

Malignant Tumor of the Sheaths and Peripheral Nerves: A Case Report

S. Naimi^{1*}, Y. Bouktib¹, A. Elhejjami¹, B. Boutakioute¹, M. Ouali Idrissi¹, N. Cherif Idrissi El Ganouni¹¹Radiology Department, Arrazi Hospital, Mohammed VI University Hospital, Marrakech, MoroccoDOI: [10.36347/sasjm.2024.v10i05.007](https://doi.org/10.36347/sasjm.2024.v10i05.007)

| Received: 01.04.2024 | Accepted: 05.05.2024 | Published: 09.05.2024

*Corresponding author: S. Naimi

Radiology Department, Arrazi Hospital, Mohammed VI University Hospital, Marrakech, Morocco

Abstract

Case Report

Malignant Peripheral Nerve Sheath Tumors (MPNST) are a rare anatomopathological subtype of soft tissue sarcoma. We report a case of MPNST in a patient without a history of neurofibromatosis. He presented with a progressively developing ulcerobourgenate lesion on the left buttock. Histopathological analysis of a biopsy of the mass confirmed MPNST. These are rare tumors that can occur in patients without any particular history and are difficult to manage at an advanced stage.

Keywords: Sarcoma; Malignant peripheral nerve sheath tumor; MRI.

Copyright © 2024 The Author(s): This is an open-access article distributed under the terms of the Creative Commons Attribution **4.0 International License (CC BY-NC 4.0)** which permits unrestricted use, distribution, and reproduction in any medium for non-commercial use provided the original author and source are credited.

INTRODUCTION

Malignant Peripheral Nerve Sheath Tumors (MPNST) arise from cells within the nerve sheath, including Schwann cells, perineural fibroblasts, or endoneural fibroblasts. They represent a rare anatomopathological subtype of soft tissue sarcoma. Typically, they occur in patients with neurofibromatosis type I or those who have undergone radiation therapy [1,2]. We report a rare case of malignant peripheral nerve sheath tumors in the left buttock of a patient with no significant medical history.

OBSERVATION

The patient, a 52-year-old resident of Laayoune, married and father of 4 children, works as a mason and is covered by the Ramed health insurance. He has no significant medical history. He presents with a nodular lesion on the left buttock that has been increasing rapidly in size over the past 5 months. On examination, the lesion appears ulcerated and protruding, measuring 9x7 cm,

with no signs of sciatica or cruralgia. Associated with this is the presence of inguinal lymphadenopathy on the same side.

A biopsy of the mass was performed, and the results of the histopathological examination confirmed a malignant tumor of the peripheral nerve sheath.

A pelvic MRI was performed to assess the local extent of the tumor, revealing a soft tissue mass located above the aponeurosis in the subcutaneous tissues of the left gluteal region. The mass had irregular contours and appeared hypointense on T1-weighted images, hyperintense on T2-weighted images, and showed diffusion restriction. After gadolinium injection, there was intense and heterogeneous enhancement of the mass. It measured 9x7x6 cm and infiltrated the gluteus maximus muscle, associated with skin loss. Additionally, left femoral adenopathies were observed, suggesting a sarcomatous origin. (Figures 1, 2).

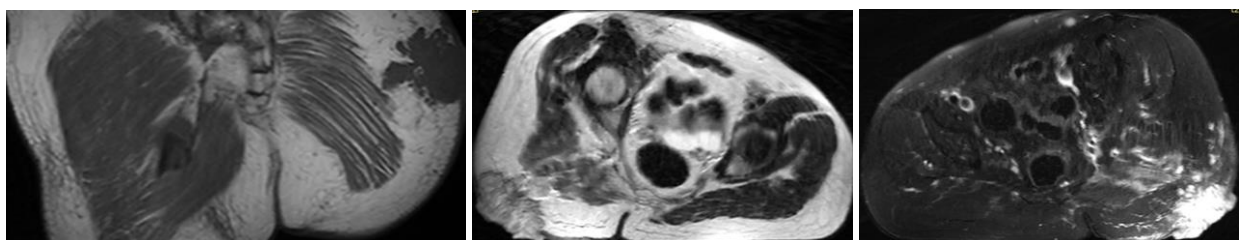


Figure 1: Coronal T1-weighted and T2-weighted sequences: soft tissue mass located above the aponeurosis in the subcutaneous tissues of the left gluteal region hypointense on T1 and hyperintense on T2

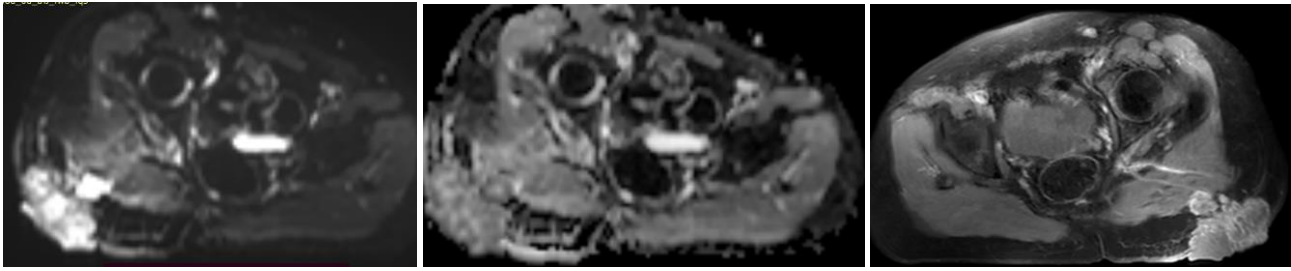


Figure 2: Diffusion restriction with intense and heterogeneous enhancement of the mass after gadolinium injection

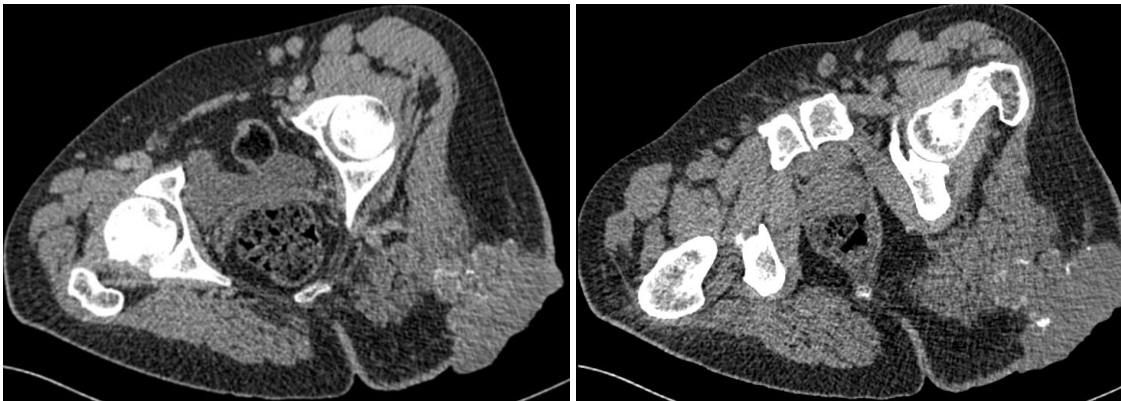

Figure 3: CT axial slices without and with contrast injection

Tissue tumor process is situated above the fascia in the subcutaneous soft tissue of the left gluteal region. It is fairly well circumscribed with irregular borders, isodense on spontaneous contrast, heterogeneous with calcifications, and contains some areas of necrosis. It is heterogeneously enhanced by the contrast medium, infiltrating posteriorly into the ipsilateral gluteus maximus muscle and the skin layer.

MRI sequences:

Axial T1-weighted, T2-weighted, and Diffusion-weighted.

Coronal T1-weighted and T2-weighted sequences.

Axial and coronal T1-weighted and T2-weighted sequences with fat saturation.

Axial and coronal T1-weighted sequences with fat saturation after gadolinium injection.

A thoraco-abdominal-pelvic CT scan was performed as part of a staging workup, which revealed no secondary lesions. Surgical excision of the tumor was performed.

DISCUSSION

Malignant tumors of peripheral nerve sheaths are a rare entity, accounting for 5 to 10% of malignant tumors of tissues. They are high-grade sarcomas [1,2]. Four main variants are recognized: the classic form predominately composed of spindle cells, the epithelioid form, the glandular form, and the form with heterologous differentiation, including the "triton" tumor [3,4]. All nerve territories can be affected: they are often described along the path of large nerve bundles, especially at the level of the sciatic nerve and cranial nerves [3].

These tumors typically affect young adults aged 20 to 50 years. In half of the cases, they occur in the context of neurofibromatosis type 1 [2]. MPNSTs develop from neurofibromas, especially plexiform neurofibromas [4].

The sex ratio is equal except in cases of neurofibromatosis type 1 (NF1), where there is a clear male predominance. Cases have been reported in children, adolescents, and the elderly, with no sex predominance [4].

Pathogenically, it is now established that the NF1 gene (located on the long arm of chromosome 17) encoding the protein "neurofibromin" is involved in the genesis of MPNSTs. The definite diagnosis is histological, with macroscopically a fusiform mass encompassing the nerve [2,4].

Clinically, pain is the most common symptom: neuralgia or undefined pain worsened by lying down, but peripheral tumors can also be asymptomatic. Spontaneous pain with sensory-motor neurological deficit should raise suspicion of malignancy. Similarly, if a known stable neurofibroma in a patient with NF1 rapidly progresses, it should prompt consideration of the diagnosis [1,3].

Palpation should be performed carefully, both at the site indicated by the patient and along the major nerve trunks. It can help identify a specific location along a nerve and search for the presence of a Tinel sign upon percussion. This sign is observed in 100% of palpable peripheral nerve tumors. A palpable mass associated

with a Tinel sign is, until proven otherwise, a peripheral nerve tumor [2,3].

Imaging is crucial for the diagnostic approach and preoperative assessment of these tumors, with two main objectives: differentiating peripheral nerve tumors from benign tumors and accurately determining their local and general extent [5].

MRI is the imaging modality of choice for characterizing these tumors, with four features that suggest a peripheral nerve tumor rather than a neurofibroma: size ≥ 5 cm, peripheral enhancement, perilesional edema, and intratumoral cystic areas (hemorrhages or necrosis). The presence of 2 to 4 of these criteria indicates a high probability of malignancy (specificity 90%, sensitivity 61%). Additionally, for patients with NF1, heterogeneous T1 signal is also suggestive of a malignant lesion. MRI is also more sensitive for determining nerve origin and guiding surgical approach [5].

The tumor appears as diffuse intermediate signal on T1-weighted sequences, with central areas showing hypointensity, and diffusely heterogeneous hypersignal on T2-weighted sequences [5].

On standard radiography, the tumor mass appears as a well-defined, dense, rounded or ovoid opacity. The outer border is smoothly contoured, resembling a compass drawing, while the inner border blends with the adjacent structures. Calcifications are rare [2,4].

Ultrasound examination is an easy, operator-dependent procedure that can provide supportive evidence of a peripheral nerve sheath tumor (PNST). Typically, these tumors appear as voluminous masses, fairly well-defined, hypoechoic, heterogeneous, and may show areas of necrosis. They can also exhibit vascularity on color Doppler imaging (unless significant necrosis is present) [3,4].

Ultrasound can reveal the intimate relationship between the tumor and the nerve trunk. However, it may be less reliable in determining their nature or distinguishing between benignity and malignancy [4].

The CT scan provides more detailed information. It helps to determine the tumor's location in proximity to a nerve trunk, ruling out other soft tissue tumors [3]. The overall appearance of the lesion on CT scan typically shows hypodensity, with peripheral and central enhancement upon contrast administration [1]. Irregular margins and infiltration of adjacent structures are often observed, favoring a diagnosis of malignant PNST. However, the presence of iodinated contrast enhancement may not always be consistent [1,4].

Metastases can occur hematogenously or follow the course of nerve sheaths. Distant metastases are commonly found in the lungs, liver, and bones. They typically develop within an average of two years, with a shorter timeframe often observed in individuals with neurofibromatosis type 1 [3,4].

The main methods of sampling to confirm the diagnosis involve fine-needle aspiration biopsy for peripheral tumors. Sometimes, diagnosis can be challenging, and the entire operative specimen may need to be removed for examination [3].

Histologically, the tumor typically presents as bundles of hyperchromatic spindle cells arranged in a fishbone pattern. High mitotic activity and geographic necrosis are often present [4].

Cytology also helps to rule out benign nerve tumors, but it is non-specific. This underscores the importance of immunocytochemistry, which shows sparse expression of S100 protein. In contrast, benign nerve tumors typically exhibit diffuse, homogeneous, and intense S100 protein expression.

The therapeutic management is not well established due to the rarity of this entity and the lack of consensus, with few series reported in the literature [2,4].

It involves both surgery and adjuvant radiotherapy, but the prognosis remains poor, with 5-year and 10-year survival rates of 34% and 23%, respectively, across all types.

Chemoradiotherapy has no impact on survival, and recurrences remain frequent [3,4].

The overall prognosis depends on the histological grade of the tumor, its size, location, association with neurofibromatosis type 1, the presence of secondary locations, and the possibility and quality of the initial surgical resection [2,3].

CONCLUSION

Malignant peripheral nerve sheath tumors (MPNSTs) are rare tumors, with diagnosis typically based on radiological findings and confirmed through histopathological and immunohistochemical analysis. MRI is the preferred imaging modality, particularly for distinguishing this entity from other differential diagnoses. Treatment primarily involves surgery, and the prognosis is generally poor [1,3,4].

REFERENCES

1. Atenguena, E., Tabola, L., Mapoko, B., Mapenya, R., Atangana, P., Sango, A., & Ndom, P. Tumeur maligne des gaines et des nerfs périphériques: à propos dun cas.

2. Soualhi, M., El Ouazani, H., Chaibainou, A., Bouchentouf, R., El Ftouh, M., Mouline, S., & Fihry, M. E. F. (2004). Tumeur maligne des gaines des nerfs périphériques type épithélioïde: A propos d'un cas. *Revue de Pneumologie Clinique*, 60(1), 50-54.
3. Mahdi, Y., Zouaidia, F., Jahid, A., Znati, K., Bernoussi, Z., Mansouri, F., & Mahassini, N. (2015). Une énorme tumeur maligne des gaines des nerfs périphériques révélant la maladie de von Recklinghausen. *Journal Africain du Cancer/African Journal of Cancer*, 2(7), 122-125.
4. Brunet, A., Hermeziu, O., Luciani, A., & Ortonne, N. (2021, June). Tumeur Triton maligne: à propos d'un cas. In *Annales de Pathologie* (Vol. 41, No. 3, pp. 317-322). Elsevier Masson.
5. Soldatos, T., Fisher, S., Karri, S., Ramzi, A., Sharma, R., & Chhabra, A. (2015, April). Advanced MR imaging of peripheral nerve sheath tumors including diffusion imaging. In *Seminars in Musculoskeletal Radiology* (Vol. 19, No. 02, pp. 179-190). Thieme Medical Publishers.