

A comparative study on fine needle aspiration with Tru-cut Biopsy in diagnosis of breast lumps

Garisa Chandra Mohana Reddy¹, Chakarala Obula Reddy^{2*}

^{1,2}Associate Professor, Department of Surgery, Fathima Institute of Medical Sciences, Kadapa, Andhra Pradesh, India

Original Research Article

*Corresponding author

Chakarala Obula Reddy

Article History

Received: 15.04.2018

Accepted: 30.04.2018

Published: 30.05.2018

DOI:

10.36347/sasjs.2018.v04i05.009



Abstract: All the breast lesions are not malignant, the diagnosis of breast lesions can be done by combination of fine needle aspiration cytology, tru-cut biopsy for better diagnostic purpose due to their accuracy. To compare fine needle aspiration cytology with Tru-cut Biopsy accuracy in breast lesions. 60 female patients (11-74 years age group) with palpable breast lump were utilized to compare the fine needle aspiration cytology with Tru-cut Biopsy to rule out clinically palpable breast lump was carried out in Fathima Institute of Medical Sciences, Kadapa, Andhra Pradesh. We have noted 22 benign lesions (36.4%) out of which fibroadenoma being the most common benign lesion and 38 malignant lesions (63.33%) of which infiltrating ductal carcinoma being the most common malignant lesion that presented for needle aspiration. The benign breast lesions on histopathological examination were fibrocystic disease-3 cases; serocystic disease-1 case; and fibro adenoma-18 cases were noted (Table-3). The morphology of malignancy breast lesions on histopathological examination were infiltrating ductal carcinoma-34 cases; Lobular carcinoma-2 cases; Non filtrating carcinoma-1case; infiltrating papillary carcinoma-1 case were noted in the present study. Fine needle aspiration cytology having more positive predictive value due to its low cost, easy to perform and having more diagnostic accuracy.

Keywords: benign, biopsy, carcinoma, infiltration, malignancy, tru-cut

INTRODUCTION

Fine needle aspiration cytology is simple, inexpensive technique and highly effective diagnostic tool in breast lump lesions become the investigation of choice for the diagnosis of the breast malignancy [1, 2]. Based on histological studies of tissue specimens related to palpable breast lesions tru-cut biopsy plays major role in providing reliable information.

Tru-cut biopsy will guide the surgeon and the oncologist for ideal modern therapeutic strategy while planning a surgery [3]. Trucut Biopsy has replaced FNAC because sample insufficiency is rare for trucut biopsy even for these lesions. Compared to open surgery, trucut biopsy is much less invasive. The volume of tissue removed, breast deformity, and the effect on mammography are much reduced [4, 5]. The current study was planned to compare fine needle aspiration cytology with Tru-cut Biopsy in diagnosis of breast lump lesions around Kadapa region of Andhra Pradesh.

MATERIALS AND METHODS

60 Female patients (17-74 years age group) with palpable breast lump were utilized in our study to compare Fine needle aspiration cytology with tru-cut biopsy in diagnosis of clinically palpable breast lumps. The present study was carried out in Fathima Institute of Medical Sciences, Kadapa, Andhra Pradesh between April 2015 to March 2016. In outpatient department a detailed history and thorough physical examination of

the patient having palpable breast lump was carried out and entered in the proforma. The patient is informed about the procedure and informed consent obtained from the patient before subjecting to fine needle aspiration cytology of the breast lump. The standard procedure was followed, making use of a 10ml syringe bearing a 22-gauge needle. The patients were informed about the cytological diagnosis. The suspicious and reported malignancies of concern patients by cytological examination underwent mastectomy or modified radical mastectomy using tru-cut biopsy method and the specimen utilized for histopathological confirmation of the diagnosis. Consent of the subject was taken as per human ethical guidelines from Fathima Institute of Medical Sciences, Kadapa, Andhra Pradesh (FIMS/KP/AP/21/12/2015).

RESULTS

The age distribution of breast lesions in our study showed 18 patients with both benign and malignant lesions between 31-40 years age group showed more significance when compared other age

groups (Table-1). We have noted 22 benign lesions (36.4%) out of which fibroadenoma (Figure 1) being the most common benign lesion that presents for needle aspiration. We have noted 38 malignant lesions (63.33%) of which infiltrating ductal carcinoma (Figure 2 & 3) being the most common malignant lesion that presented for needle aspiration (Table-2). The benign breast lesions by histopathological examination were fibrocystic disease-3 cases (Figure-4); sero-cystic disease-1 case; and fibro adenoma-18 cases (Table-3).

The morphology of malignancy breast lesions by histopathological examination were infiltrating ductal carcinoma-34 cases; Lobular carcinoma-2 cases; Non filtrating carcinoma-1case; infiltrating papillary carcinoma-1 case (Table-4). The predictive value (Positive-100%; Negative-90.47%) in the present study showed with sensitivity 93.10% and specificity of 100% with fine needle aspiration cytology in breast lump lesions.

Table-1: The age incidence of the patients with breast lesions

Age(years)	Benign	Malignant	Total
11-20 (17yrs)	6	-	6
21-30	9	-	9
31-40	7	11	18
41-50	-	9	9
51-60	-	6	6
61-70	-	9	9
>71	-	3	3
Total	22	38	60

Table-2: Diagnosis of breast lump lesions (Fine needle aspiration cytology)

Diagnosis	No. Patients with Prediction
Benign	24(False negative-2)
Suspicious	3 (Malignancy Confirmed with HP)
Malignant	33 (False Positive-0)
Total	60

Table-3: Benign breast lesions (Histopathological examination)

Morphology	Number of Cases
Fibrocystic Disease	3
Sero-cystic disease	1
Fibroadenoma	18
Total	22

Table-4: Malignant breast lesions (Histopathological Examination)

Morphology	Number of Cases
Infiltrating ductal carcinoma	34
Lobular carcinoma	2
Nonfiltrating carcinoma	1
Infiltrating papillary carcinoma	1
Total	38

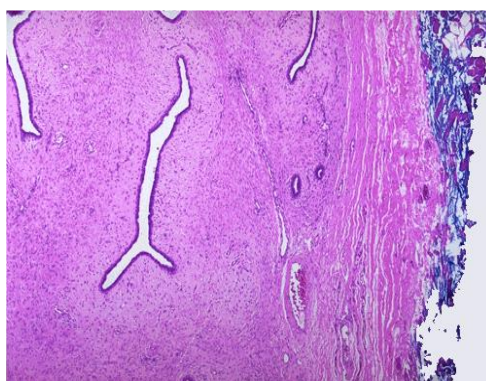


Fig-1: Fibroadenoma with compressed breast connective tissue forming a mass

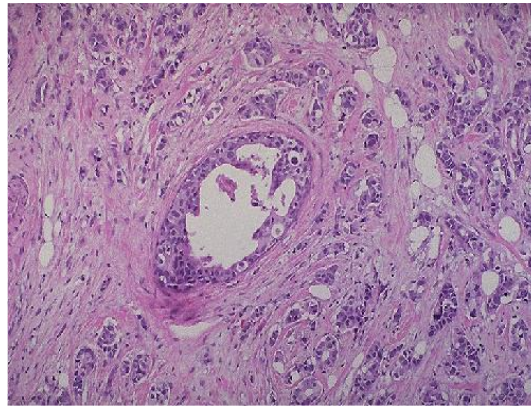


Fig-2: Duct lined by carcinoma cells- Ductal carcinoma infiltrates outward into the surrounding stroma as an infiltrating ductal carcinoma

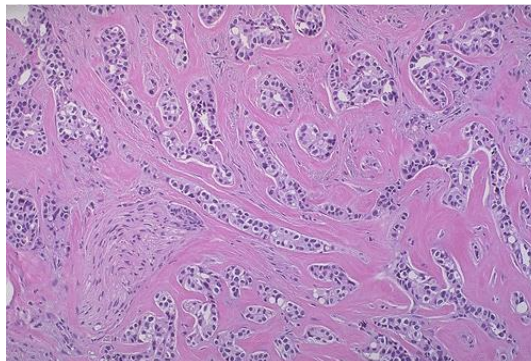


Fig-3: Typical infiltrating ductal carcinoma of the breast

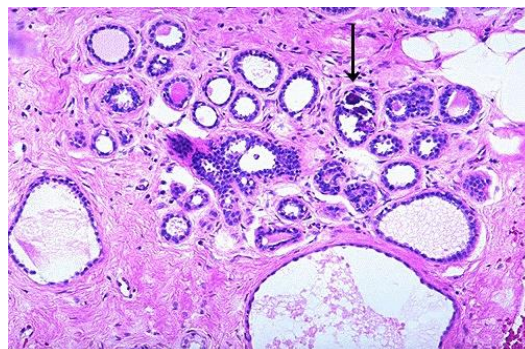


Fig-4: Histological appearance of fibrocystic changes in breast with no atypical changes

DISCUSSION

Fine needle aspiration cytology is one of the major diagnostic procedure in developing countries due to its low cost, safe, affordable with rapid results and minimal pain in malignant breast lesions [6, 7]. But in some studies core biopsy or tru- cut biopsy played a vital role when compared with fine needle aspiration cytology due to its sensitivity, core biopsy sensitivity (84.62%) is more than that of sensitivity of fine needle aspiration cytology (80.71%) in a study of 52 samplings, in which all the patients underwent fine needle aspiration cytology followed by core biopsy [8]. The diagnostic accuracy of clinical examination, xeromammography, and fine needle aspiration cytology was compared with the definitive histological finding [9]. Previous studies stated that specificity of the core needle biopsy is higher with its predictive value for

suspicious, atypical lesions and fibro epithelial lesions [4]. The incidence of fine needle aspiration cytology has increased due to its widely used screening programmes. When we consider the performance indices of core needle biopsy are higher than fine needle aspiration cytology in majority of breast lesions [10]. In diagnosing the breast tumors the accuracy of fine needle aspiration cytology increases by performing repeat aspiration in a lump for which previously been reported as inadequate sampling [11]. The sensitivity of fine needle aspiration cytology in diagnosing the palpable breast lump in our study was 93.10%, specificity was 100%, positive predictive of 100%, and negative predictive value of 90.47% confirms the accuracy and clinical utility of fine needle aspiration cytology when compared with core biopsy or tru-cut

biopsy in diagnosis and management of breast lesions is in support with the previous literatures [12].

CONCLUSION

The tru-cut biopsy and fine needle aspiration cytology together plays major role in diagnosis of breast lump lesions whereas fine needle aspiration cytology having more predictive value due to its low cost, easy to perform and having more diagnostic accuracy.

ACKNOWLEDGEMENT

Authors are thankful to the Faculty, Department of Surgery and Pathology, FIMS, Kadapa for their support during this work.

REFERENCES

1. Duguid HL, Wood RA, Irving AD, Preece PE, Cuschieri A. Needle aspiration of the breast with immediate reporting of material. *Br Med J.* 1979 Jul 21;2(6183):185-7.
2. Kline TS, Joshi LP, Neal HS. Fine-needle aspiration of the breast: Diagnoses and pitfalls. A review of 3545 cases. *Cancer.* 1979 Oct;44(4):1458-64.
3. Pinder SE, Elston CW, Ellis IO. The role of preoperative diagnosis in breast cancer. *Histopathol.* 1996;28:563-6.
4. Shashirekha CA, Singh R, Ravikiran HR, Sreeramulu PN, Prasad K. Fine needle aspiration cytology versus trucut biopsy in the diagnosis of breast cancer: a comparative study. *International Surgery Journal.* 2017 Oct 27;4(11):3718-21.
5. Joulaee A, Kalantari M, Kadivar M, Joulaee S, Bahrani N, Mangual M, Hosseini S, Etemadmoghadam G. Trucut biopsy of breast lesions: The first step toward international standards in developing countries. *European Journal of Cancer.* 2012 Mar 1;48(5):648-54.
6. Tiwari M. Role of fine needle aspiration cytology in diagnosis of breast lumps. 2007.
7. Homesh NA, Issa MA, El-Sofiani HA. The diagnostic accuracy of fine needle aspiration cytology versus core needle biopsy for palpable breast lump (s). *Saudi medical journal.* 2005 Jan;26(1):42-6.
8. Memom F, Qureshi S. Sensitivity of fine needle aspiration versus core biopsy in the diagnosis of palpable and clinically suspicious breast lesions. *Pakistan J Surg.* 2009; 25(3):214-7.
9. Thomas JM, Fitzharris BM, Redding WH, Williams JE, Trott PA, Powles TJ, Ford HT, Gazet JC. Clinical examination, xeromammography, and fine-needle aspiration cytology in diagnosis of breast tumours. *Br Med J.* 1978 Oct 21;2(6145):1139-41.
10. Willems SM, Van Deurzen CH, Van Diest PJ. Diagnosis of breast lesions: fine-needle aspiration cytology or core needle biopsy? A

review. *Journal of clinical pathology.* 2012 Apr 1;65(4):287-92.

11. Saxe A, Phillips E, Orfanou P, Husain M. Role of sample adequacy in fine needle aspiration biopsy of palpable breast lesions. *The American journal of surgery.* 2001 Oct 1;182(4):369-71.
12. Ariga R, Bloom K, Reddy VB, Kluskens L, Francescatti D, Dowlath K, Siziopikou P, Gattuso P. Fine-needle aspiration of clinically suspicious palpable breast masses with histopathologic correlation. *The American journal of surgery.* 2002 Nov 1;184(5):410-3.