

Evaluation of the Incidence of Gefitinib Induced Interstitial Lung Disease in Patients with Pulmonary Adenocarcinoma

Kailash Chandra Pandey¹, Swaroop Revannasiddaiah², Nirdosh Kumar Pant^{*3}, Lalit Mohan⁴, Madhup Rastogi⁵

¹⁻⁴Department of Radiotherapy, Swami Rama Cancer Hospital & Research Institute, Government Medical College-Haldwani, District Nainital, Uttarakhand, 263139, India

⁵Professor, Department of Radiotherapy, Ram Manohar Lohia Institute of Medical Sciences, Vibhuti Khand, Gomti Nagar, PIN 226010, Lucknow, India

Original Research Article

*Corresponding author

Nirdosh Kumar Pant

Article History

Received: 30.03.2018

Accepted: 08.04.2018

Published: 30.04.2018

DOI:

10.36347/sjams.2018.v06i04.040



Abstract: Gefitinib induced interstitial lung disease (ILD) is a potentially serious adverse effect that should be considered in patients treated with gefitinib who present with unexpected dyspnea. This single-institution retrospective study aims to determine the incidence, clinical presentation, management, and clinical outcome in patients diagnosed with gefitinib induced ILD during the time frame of January 2013-December 2016. Out of 340 patients with EGFR-mutated pulmonary adenocarcinoma who received gefitinib as targeted therapy against EGFR exon 19 or exon 21 mutations, 36 patients developed features confirmatory of ILD. The median time of presentation of ILD was after the 3rd month of gefitinib use. Eighteen patients (50%) presented with acute onset dyspnea, and dry cough and further eighteen patients (50%) presented with insidious onset of dry cough and dyspnoea. Infectious pneumonitis was not considered as interstitial lung disease. Six of these patients had severe ILD. Four of these patients responded to corticosteroid treatment and supplemental oxygen. One patient recovered after intensive care and mechanical ventilation and one patient succumbed to ILD despite mechanical ventilation. Incidence of mild and serious ILD in this Indian patient population was 8.8% & 1.8%, respectively. Thus, gefitinib induced lung disease is not uncommon and thus requires a high index of suspicion for early diagnosis and drug discontinuation.

Keywords: Gefitinib, tyrosine kinase inhibitor, interstitial lung disease, dyspnoea, adenocarcinoma.

INTRODUCTION

The discovery that EGFR (epidermal growth factor receptor) driver mutations are responsible for a large proportion of pulmonary adenocarcinomas has revolutionized the treatment of lung cancer. The advent of EGFR targeted tyrosine-kinase inhibitors such as gefitinib, erlotinib and afatinib have prolonged survival in advanced lung cancer harboring EGFR activating mutations such as exon 19 deletions and exon 21 L858R substitution mutations [1].

Gefitinib was approved by the US-FDA for first-line use in the treatment of metastatic or locally-advanced inoperable non-small cell lung cancer (NSCLC) which are harboring activating EGFR mutations [1,2]. It must also be noted that gefitinib is also approved for use after failure with prior chemotherapy [3].

In addition to lung cancer, gefitinib has also been used experimentally and off-label in various other

malignancies including head & neck squamous cell cancers, pancreatic cancers, glioblastoma and others [4].

Despite being a targeted therapeutic agent, gefitinib is not without its side effects. It shares a similar adverse effect profile with other EGFR targeting agents such as erlotinib and afatinib. The most common adverse effects are dermatitis, rash, acne and diarrhoea. However, the most serious albeit less common adverse effect would be the development of interstitial lung disease (ILD). The spectrum of respiratory symptoms of ILD includes respiratory symptoms such as dry cough, dyspnoea and respiratory distress. Western studies have indicated an incidence rate ranging from 15-40% for mild pulmonary symptoms such as cough and slight dyspnoea. Severe pneumonitis and life threatening respiratory distress have been reported in only 1% of patients [5, 6].

Gefitinib is a widely used drug in the field of oncology. However, the incidence of gefitinib-induced ILD has not been determined in Indian patients, and to our knowledge, this is the first ever study from India which attempts to assess the issue.

EXPERIMENTAL SECTION/MATERIALS AND METHODS

This retrospective study utilized hospital records of patients treated from 1 January 2013 to 31 December 2016 at the Swami Rama Cancer Hospital & Research Institute at Haldwani, District Nainital,

Uttarakhand, India. All patients included in this retrospective study had received single-agent gefitinib at a dose of 250mg once a day, orally. Only patients with confirmed exon 19 del or exon 21 L858R mutations in the EGFR gene were included. As a retrospective trial, no patient was warranted any trial specific intervention. All patients' records were handled in a manner to ensure patient anonymity and confidentiality. The inclusion and exclusion criteria for this retrospective trial are mentioned in table-1 (eligibility criteria).

Table-1: Eligibility criteria

INCLUSION CRITERIA
- Patient should have received at-least 10 days of Gefitinib. - Confirmed EGFR activating mutations. - Confirmed pulmonary adenocarcinoma.
EXCLUSION CRITERIA
- Incomplete patient records - Use of alternative EGFR targeted therapies such as erlotinib, afatinib etc. - Use of other chemotherapy or radiotherapy during the use of gefitinib. - Use of gefitinib for indications other than pulmonary adenocarcinoma. - Prior history of interstitial lung disease before the diagnosis of malignancy. - Ambiguous and mixed histologies.

Gefitinib induced ILD was suspected when patients presented with any of the following symptoms such as- dyspnea (acute or insidious onset), dry cough, and/or fever. If the patient record was suspicious of an infectious cause, the case was not counted as 'gefitinib induced ILD' unless if infectious cause was ruled out by extensive investigations (complete blood counts, blood and urine cultures, sputum and/or Broncho alveolar lavage (BAL) fluid for Gram stain and culture, Zeihl Nielsen stain for acid fast bacilli, fungal elements, fungal hyphae and pneumocystitis jiroveci).

As per records, all patients suspected with gefitinib induced ILD had underwent an arterial blood gas analysis and chest radiograph, and echocardiogram. The diagnosis of ILD was radiologically confirmed only after imaging with high resolution computed tomography (HRCT) of the lungs.

A patient was counted as severe ILD only if the clinical record described the clinical presentation as being acute, rapidly progressing respiratory failure requiring supplemental oxygen, corticosteroids and mechanical ventilation.

All patients in whom gefitinib induced ILD was either suspected or diagnosed were started on oral or intravenous corticosteroids, which could be continued for a duration of six to eight weeks depending on clinical situation. In patients who were hypoxemic at rest or had features of life-threatening frank respiratory failure, methylprednisolone was given at a dose of 125 mg every four to six hours. Oral

corticosteroids would only be used after clinical improvement. Oxygen inhalation and mechanical ventilation was initiated in patients having progressive respiratory failure despite high dose parenteral corticosteroids. The dose of oral prednisolone given in non-hypoxemic patients was 0.75–1 mg/kg body weight for the first two weeks and tapered by 0.25 mg/kg every two weeks provided that there was clinical and radiological improvement.

All patients were followed up on a weekly basis after discharge from hospital after stabilization and fortnightly follow-up was done until complete radiological resolution and normalization of oxygen saturation. At every follow-up visit, thorough clinical examination was done. Chest radiograms were performed after two weeks and CT scans were ordered in case of suspicions on chest radiographs.

For statistical analysis, data from hospital records were manually entered into spreadsheet format and descriptive analyses were inferred using *Gnumeric version 1.12.28* for Linux Platform.

RESULTS AND DISCUSSION

Of the 340 EGFR mutated pulmonary adenocarcinoma patients during the time frame of January 2013- December 2016, 36 patients were found to be diagnosed with interstitial lung disease. The age of patients ranged from 18-79 years, with a median age of 56 years. The male: female ratio of patients with gefitinib induced ILD was almost identical at 19:17 (male: female). Of the 340 patients, 210 were smokers

and 130 were non-smokers. However the ratio of smokers developing ILD was much higher than the ratio of non-smokers developing ILD after the initiation of gefitinib (13.8% vs. 5.7%, $p=0.0174$).

The median time of manifestation of ILD after the initiation of gefitinib was at 12 weeks, with the range being from 2 weeks to 34 weeks (Figure-1). There was no case of interstitial lung disease which developed beyond 34 weeks after initiation of gefitinib.

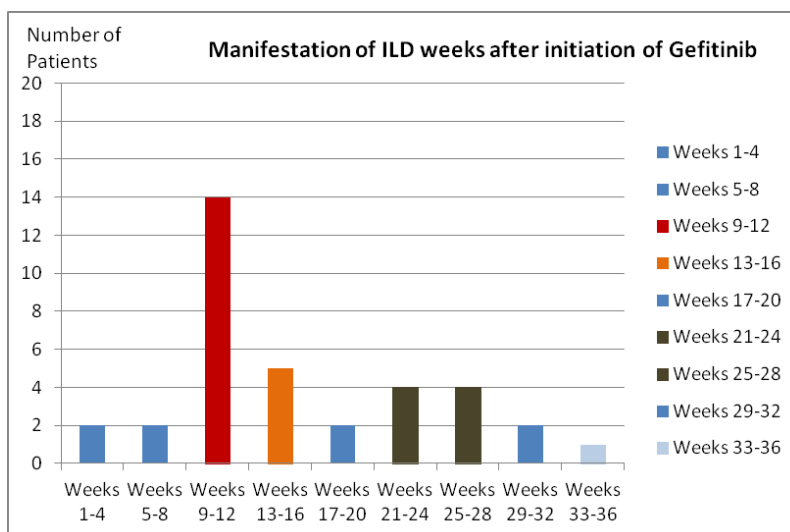


Fig-1: Week-wise onset of gefitinib induced interstitial lung disease

Half of the patients (50%, $n=18$) who developed ILD presented with acute onset of symptoms which included isolated high grade fever, high grade fever with dyspnea, and high grade fever with dry cough. The remaining 50% of patients who developed ILD had an insidious onset of symptoms and presented with dyspnea, dry cough, fever, and fatigue.

All patients with ILD had prompt discontinuation of gefitinib at the earliest. Of the 36 patients who developed ILD, six patients had developed severe ILD. Four of these patients with

severe ILD responded to corticosteroid treatment and supplemental oxygen. One patient recovered after intensive care and mechanical ventilation and one patient succumbed to ILD despite mechanical ventilation.

No patients diagnosed with gefitinib induced ILD were re-challenged with the drug. Neither was other tyrosine kinase inhibitors used as alternate treatment. Subsequent anti-cancer treatment was with radiotherapy, intravenous chemotherapy, oral metronomic cyclophosphamide, oral metronomic etoposide or supportive care alone (table 2).

Table-2: Subsequent therapy after recovery from gefitinib induced interstitial lung disease

Modality	Number
Best supportive care	14
Palliative radiotherapy	8
Intravenous chemotherapy	3
Metronomic cyclophosphamide	9
Metronomic etoposide	2
TOTAL	36

DISCUSSION

Despite the fact that many EGFR and ALK targeted therapies have been approved for the treatment of pulmonary adenocarcinoma, most of them are associated with risk of drug induced interstitial lung disease, which warrants immediate cessation of the targeted therapy. While agents like gefitinib, erlotinib, afatinib, osimertinib, crizotinib and alectinib have all been associated with risk of interstitial lung disease, most studies describe an incidence rate of about 1-5%

[7-12]. However no study currently describes the risk of interstitial lung disease among Indian patients treated with EGFR targeted therapies. This in our knowledge is the first ever study which describes the risk of interstitial lung disease induced by gefitinib in the specific population of Indian patients with pulmonary adenocarcinoma.

As per our retrospective study, the incidence of gefitinib induced ILD was 10.6%, with 36 patients

out of 340 gefitinib treated patients developing any degree of ILD. While the incidence of mild ILD was 8.8%, the incidence of severe ILD was 1.8%.

Most earlier studies describe the time of onset of ILD has ranged from 1 day to several weeks after the initiation of gefitinib, with most studies describing the mean duration as being 12 weeks from the first dose. Our study too had a peak incidence at the 12th week. It was notable that no patient developed ILD later than 34 weeks after initiation of gefitinib. No patient had an immediate onset during the first week of treatment.

The most frequent symptoms of gefitinib induced ILD currently reported in the published literature include fever, hypoxemia and dyspnea. In our retrospective study, half of the patients presented with acute onset while the remaining half presented with insidious onset of symptoms. Six (16.7%) patients had significant hypoxemia at presentation, and most responded well to oxygen supplementation and corticosteroids.

As per published literature, the various radiological patterns reported on HRCT include focal alveolar densities (54%), ground glass opacities (34%), and alveolar opacification (8.5%) [13]. Since ours has been a retrospective study, characterization of radiological findings has not been possible. Bronchoscopy findings reported in various previously published articles include lymphocytosis in the Broncho alveolar lavage fluid and the predominant histological pattern was organizing pneumonia [14]. In addition to the mentioned patterns, other reported patterns include nonspecific interstitial pneumonitis, diffuse alveolar damage and/or intra-alveolar hemorrhage [15]. Since ours is a retrospective study, it was not feasible to obtain bronchoscopy and histological findings.

Though literature specific to gefitinib is rather scarce, interstitial lung disease induced by other targeted therapies such as rituximab, cetuximab, erlotinib and others can be interpolated since the underlying pathophysiology is assumed to be the same. The treatment options mentioned in the reviewed literature include use of corticosteroids, oxygen supplementation, and mechanical ventilation. In a systematic review, 27% of patients required mechanical ventilation and the mortality was 16% [15, 16].

While after an established diagnosis of ILD, re-challenge with the drug is generally avoided in favour of alternate therapies such as chemotherapy or radiotherapy, as permitted by the patient's general condition. In our retrospective study, 38.9% of the patients could not be treated with further modalities had were hence assigned for best supportive care. The

remaining patients were treated with palliative radiotherapy (22.2%), intravenous chemotherapy (8.3%), metronomic oral cyclophosphamide (25%) or metronomic oral etoposide (5.6%).

CONCLUSION

Interstitial lung disease is a serious and potentially lethal pulmonary toxicity of gefitinib and similar EGFR targeted small molecule tyrosine kinase inhibitors. Since the symptoms at presentation may be nonspecific, the treating clinicians must maintain a high suspicion and vigilance to recognize this complication early. Early recognition, gefitinib discontinuation and appropriate supportive care can reduce the risk of mortality. In general, re-challenge with gefitinib or alternate EGFR tyrosine kinase inhibitors should be avoided. Incidence of mild and serious ILD in this Indian patient population was 8.8% & 1.8%, respectively. Thus, gefitinib induced lung disease is not uncommon and thus requires a high index of suspicion for early diagnosis and drug discontinuation.

REFERENCES

1. Revannasiddaiah S, Thakur P, Bhardwaj B, Susheela SP, Madabhavi I. Pulmonary adenocarcinoma: implications of the recent advances in molecular biology, treatment and the IASLC/ATS/ERS classification. *J Thorac Dis.* 2014 Oct;6(Suppl 5):S502-25.
2. Greenhalgh J, Dwan K, Boland A, Bates V, Vecchio F, Dundar Y, Jain P, Green JA. First-line treatment of advanced epidermal growth factor receptor (EGFR) mutation positive non-squamous non-small cell lung cancer. *The Cochrane Library.* 2016 Jan 1.
3. Wu YL, Saijo N, Thongprasert S, Yang JH, Han B, Margono B, Chewaskulyong B, Sunpaweravong P, Ohe Y, Ichinose Y, Yang JJ. Efficacy according to blind independent central review: Post-hoc analyses from the phase III, randomized, multicenter, IPASS study of first-line gefitinib versus carboplatin/paclitaxel in Asian patients with EGFR mutation-positive advanced NSCLC. *Lung Cancer.* 2017 Feb 1;104:119-25.
4. Olsen CC, Schefter TE, Chen H, Kane M, Leong S, McCarter MD, Chen Y, Mack P, Eckhardt SG, Stieglmann G, Raben D. Results of a phase I trial of 12 patients with locally advanced pancreatic carcinoma combining gefitinib, paclitaxel, and 3-dimensional conformal radiation: report of toxicity and evaluation of circulating K-ras as a potential biomarker of response to therapy. *American journal of clinical oncology.* 2009 Apr 1;32(2):115-21.
5. Takeda M, Nakagawa K. Toxicity profile of epidermal growth factor receptor tyrosine kinase inhibitors in patients with epidermal growth factor receptor gene mutation-positive lung cancer. *Mol Clin Oncol.* 2017 Jan;6(1):3-6.

6. Shah RR. Tyrosine Kinase Inhibitor-Induced Interstitial Lung Disease: Clinical Features, Diagnostic Challenges, and Therapeutic Dilemmas. *Drug Saf.* 2016 Nov;39(11):1073-1091.
7. Hsiue EH, Lee JH, Lin CC, Yang JC. Safety of gefitinib in non-small cell lung cancer treatment. *Expert Opin Drug Saf.* 2016 Jul;15(7):993-1000.
8. Losanno T, Gridelli C. Safety profiles of first-line therapies for metastatic non-squamous non-small-cell lung cancer. *Expert Opin Drug Saf.* 2016 Jun;15(6):837-51.
9. Hong D, Zhang G, Zhang X, Lian X. Pulmonary Toxicities of Gefitinib in Patients With Advanced Non-Small-Cell Lung Cancer: A Meta-Analysis of Randomized Controlled Trials. *Medicine (Baltimore).* 2016 Mar;95(9):e3008.
10. Matsumoto Y, Kawaguchi T, Yamamoto N, Sawa K, Yoshimoto N, Suzumura T, et al. Interstitial Lung Disease Induced by Osimertinib for Epidermal Growth Factor Receptor (EGFR) T790M-positive Non-small Cell Lung Cancer. *Intern Med.* 2017 Sep 1;56(17):2325-2328.
11. Macerelli M, Mazzer M, Foltran L, Cardellino GG, Aprile G. Erlotinib-associated interstitial lung disease in advanced pancreatic carcinoma: a case report and literature review. *Tumori.* 2015 Jul 24;101(4):e122-7.
12. Peerzada MM, Spiro TP, Daw HA. Pulmonary toxicities of tyrosine kinase inhibitors. *Clin Adv Hematol Oncol.* 2011 Nov;9(11):824-36.
13. Soubrier M, Jeannin G, Kemeny JL, Tournadre A, Caillot N, Caillaud D, Dubost JJ. Organizing pneumonia after rituximab therapy: Two cases. *Joint Bone Spine.* 2008;75:362-5.
14. Mian M, Rass C, Hutarew G, Kofler B, Fiegl M, Greil R. Extensive organizing pneumonia during chemo-immunotherapy containing rituximab and G-CSF in a patient with diffuse large B-cell lymphoma: case report and review of the literature. *Leuk Lymphoma.* 2006;47:1683-5.
15. Lioté H, Lioté F, Séroussi B, Mayaud C, Cadranet J. Rituximab-induced lung disease: A systematic literature review. *Eur Respir J.* 2010; 35:681-7.
16. Vahid B, Marik PE. Infiltrative lung diseases: complications of novel antineoplastic agents in patients with hematological malignancies. *Can Respir J.* 2008;15:211-6.