

Extracorporeal Fixation of Mandibular Condyle Fracture: A Case Report

Ramani Pamanji^{1*}, Rajashekar Gali², Ramesh Babu Vaka³

¹Post Graduate Student Department of Oral and Maxillofacial Surgery Narayana Dental College and Hospital Nellore, Andhra Pradesh, India

^{2,3}Professor Department of Oral and Maxillofacial Surgery Narayana Dental College and Hospital Nellore Andhra Pradesh, India

*Corresponding author: Ramani Pamanji

| Received: 12.02.2019 | Accepted: 22.02.2019 | Published: 28.02.2019

DOI: [10.36347/sjds.2019.v06i02.006](https://doi.org/10.36347/sjds.2019.v06i02.006)

Abstract

Case Report

Condylar fracture is the most common fracture in mandible which accounts for 25-30%. The major causes of such fractures are RTA and assault. Due to its anatomical weakness and the shape of the condylar head and attachment of muscle, the antero-medial dislocation is quite common. Surgical management of condylar fractures is widely debated. Medially dislocated sub condylar fracture fragments are routinely managed with open method. The precise anatomical reduction with conventional open reduction can be difficult due to the narrow surgical and visual fields in case of highly dislocated condyle fractures. In such cases extracorporeal fixation of condyle may be better choice to achieve ideal alignment and simple maintenance of vertical height of the ramus and facial symmetry. We here present a case of extracorporeal fixation of unilateral left high condylar fracture.

Keywords: Extracorporeal fixation, condyle fracture, opens reduction.

Copyright © 2019: This is an open-access article distributed under the terms of the Creative Commons Attribution license which permits unrestricted use, distribution, and reproduction in any medium for non-commercial use (NonCommercial, or CC-BY-NC) provided the original author and source are credited.

INTRODUCTION

Though the condylar fracture accounts for 25-30% of all mandibular fracture, the management is always arguable. The surgical methods include open reduction and osteosynthesis with miniplates, wires or lag screws. Because of the displacement of condylar fragment, the ramus of mandible is telescoped into the glenoid fossa. Hence even in case of open reduction, it is difficult to locate and manipulate the displaced fragment in most cases. Another drawback is to hold it in reduced position and fixation due to its proximity to important anatomical structures. The extracorporeal

fixation could be a viable option for such high condylar fractures.

CASE REPORT

A 13-year-old female patient reported to our department with a chief complaint of pain in the left side of jaw. Intra-orally all teeth were present and the occlusion was deranged with posterior open bite on right side and no midline deviation was noticed. Mild restriction of mouth opening was noticed. On palpation Temporomandibular joint (TMJ) area was severely painful on the left side. OPG shows left condylar neck fracture [Fig-1]. CT showed anteromedial dislocation of the fractured neck of the left condyle [Fig-2].

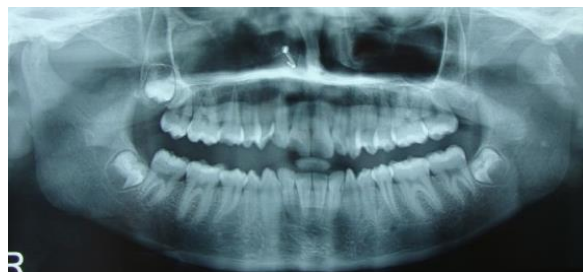

Fig-1: Pre-operative OPG showing left high condylar fracture

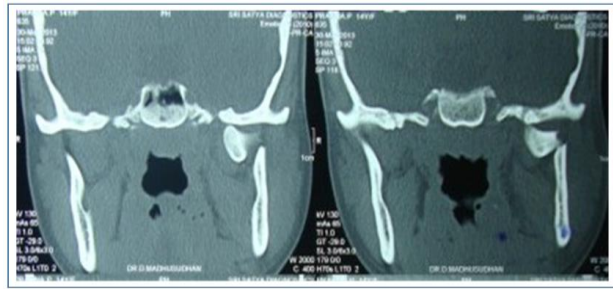


Fig-2: Coronal section of CT showing anterior- medially dislocated condylar neck fracture on the left side

Based on the clinical and radiological examination this was classified as medially dislocated condyle neck fracture according to Lindahl's comprehensive classification. A preauricular incision was given [Fig 3]. Dissection was done in the subdermal fat plane just above the superficial musculo-aponeurotic (SMAS) layer till the anterior margin of the parotid gland. The gland is gently retracted posteriorly to expose the masseter muscle fibres, and the course of facial nerve branches are divided to expose the periosteum overlying the ramus and condyle. Subperiosteally dissection over lateral aspect of ramus was done to expose the fracture. After exposure of the fracture; attempts were made to reduce the anteromedial dislocated condylar neck. The condyle was stripped free of its attachments from the lateral pterygoid muscle and capsular attachments, and it was retrieved from the body and out of glenoid fossa. It was fixed extra

corporeally by adapting a four-hole miniplate and attached to its posterior border [Fig 4]. The condylar segment was repositioned back into the glenoid fossa, and in its continuity with the distal part, IMF placed and was fixed to the ramus. IMF was released; mobility of the fracture segment and occlusion checked, small portion of temporal fascia is placed in between glenoid fossa and condyle. Wound closed in layers after water tight closure of parotid fascia to prevent fistula formation with 3-0 vicryl and skin closure done with 3-0 ethilon. Patient's post-operative recovery was uneventful. Postoperative OPG [Fig-5]

Shows fixation of fractured fragments. The mouth opening improved and case was followed up for four months for any changes in mouth opening, mandibular movements and occlusion.

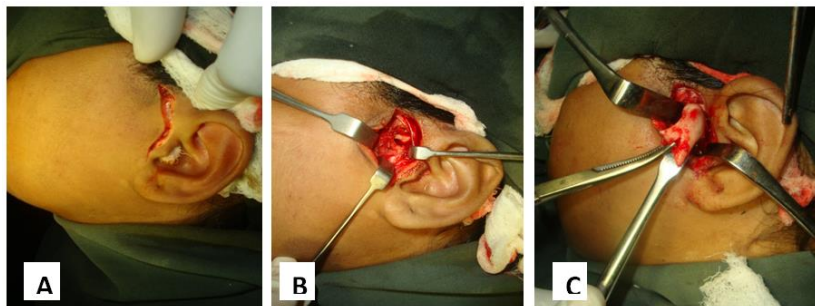


Fig-3[a]: preauricular incision [b]: sub periosteal dissection exposing the ramus and fracture condyle of mandible [c]: fractured segment retrieved out of glenoid fossa

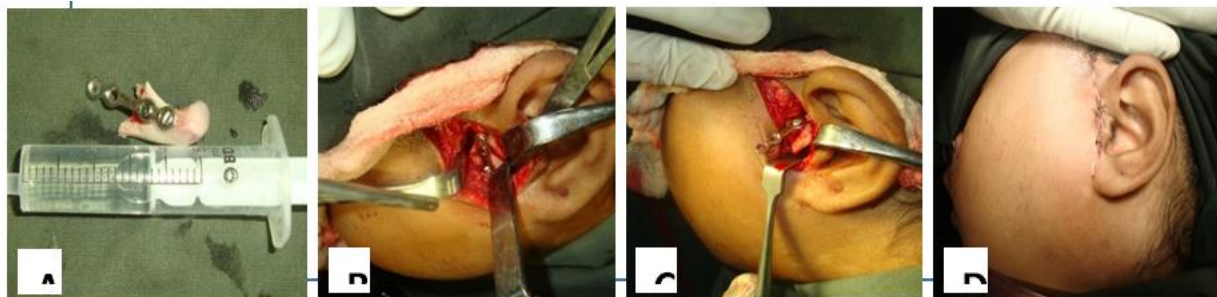

Fig-4: [a]: extracorporeal fixation of proximal segment with 4 holed miniplate [b]: repositioning the Proximal stump into the glenoid fossa [c]: fixation of proximal segment to the ramus [d]: wound closure

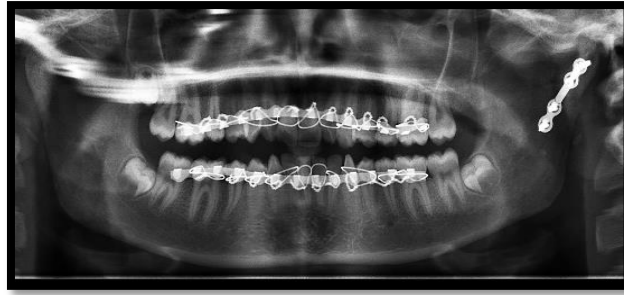

Fig-5: Immediate post op OPG showing fixation of fractured segment

DISCUSSION

The extensiveness of a mandibular condyle fracture is proportionately high when compared with another type of mandibular fracture. The mandibular condylar fractures are broadly classified as intracapsular and extra capsular and treatment options are either by open or closed method [2]. Zide and Kent illustrated absolute and relative indications for open reduction of condylar fractures. Open reduction by standard surgical approaches like Risdon's submandibular; retromandibular is difficult due to its anatomical position and proximity of the facial nerve [4]. Localization of the displaced or dislocated fractured bony fragment as well makes the procedures more difficult by these approaches.

Many surgeons had chosen closed method and treatment had shown favourable results. But a few conservative treatments had issues such as malocclusion, facial asymmetry, TMJ pain, loss of vertical height of ramus. In case of severely displaced condylar fractures open reduction may give satisfactory results. In case of high or superiorly positioned fractures standard approaches can be difficult in term of access, visualization, fixation and causing damages to adjacent structures such as parotid gland and facial nerve [4]. Extra corporeal fixation is a method to resolve above problems [7]. In the present case, attaining ideal occlusion was difficult due to shortening of the ramus and pull of the mandible to the left side. The extracorporeal reduction and fixation are planned due to severe antero-medial displacement of the condylar ne fracture.

For superiorly located condylar fractures with medially displaced fragments, Nam [8] introduced 'Nam's method', which incorporates vertical ramus osteotomy, extra oral reduction and fixation of the fractured condyle to the osteotomy fragment, and re-fixation of the ramus. This technique allows for anatomically accurate reduction of fragments [8].

Approaches to the fractured condylar neck is usually by pre-auricular or Endaural[5]. The dissection we followed in this case was the Trans masseteric antero parotid (TMAP) technique advocated by Wilson *et al.* which offers immediate access to the condylar

neck while substantially reduces the risk of injuring the facial nerve and reduce the postoperative complication. Since it is a quick, leaves a small less conspicuous scar, fractured fragments can be perfectly aligned with minimal risk to the facial nerve injury.

Extracorporeal fixation even though it is unique, compromising the vascularity [6] of the osteotomised segment is still possible. Fixing the fractured condyle to the free ramal graft without detaching the lateral pterygoid [7] will be challenging due to intervening soft tissues. Explanted fractured segment act as free graft [3,6] and shows condylar resorption[6,7].

Boyne [1] reported significant condylar resorption in patients treated with extracorporeal fixation. In their study, condylar resorption occurred within the first two years of surgery and then remained stable for up to 15 years. Changes in occlusion were not observed

CONCLUSION

For condylar fracture, the decision for open reduction or closed reduction is based on amount of displacement or dislocation, functional and aesthetic concern. Severely displaced condyle fracture invariably warrants an open reduction. For proper anatomical reduction of medially dislocated condyle, direct visualization, retrieval of medially dislocated fractured segment, fixation by extracorporeal method is valuable. But the disadvantage with this technique is broad exposure, damage to facial nerve and parotid gland and avascular necrosis of free ramal graft segment.

REFERENCES

1. Boyne PJ. Free grafting of traumatically displaced or resected mandibular condyles. *Journal of Oral and Maxillofacial Surgery*. 1989;47(3):228-32.
2. Haug RH, Brandt MT. Traditional versus endoscope-assisted open reduction with rigid internal fixation (ORIF) of adult mandibular condyle fractures: a review of the literature regarding current thoughts on management. *Journal of oral and maxillofacial surgery*. 2004; 62(10): 1272-9.

3. Davis BR, Powell JE, Morrison AD. Free-grafting of mandibular condyle fractures: clinical outcomes in 10 consecutive patients. *International journal of oral and maxillofacial surgery*. 2005;34(8):871-6.
4. Ellis III E, McFadden D, Simon P, Throckmorton G. Surgical complications with open treatment of mandibular condylar process fractures. *Journal of oral and maxillofacial surgery*. 2000;58(9):950-8.
5. Gupta MV, Col NS. Extracorporeal fixation of displaced mandibular condylar fracture: viable option. *Medical Journal Armed Forces India*. 2009;65(3):229-31.
6. Narayanan V, Kannan R, Sreekumar K. Retromandibular approach for reduction and fixation of mandibular condylar fractures: a clinical experience. *International journal of oral and maxillofacial surgery*. 2009;38(8):835-9.
7. Park JM, Jang YW, Kim SG, Park YW, Rotaru H, Baciut G, Hurubeanu L. Comparative study of the prognosis of an extracorporeal reduction and a closed treatment in mandibular condyle head and/or neck fractures. *Journal of Oral and Maxillofacial Surgery*. 2010;68(12):2986-93.
8. Nam IW. The condylar head and upper condylar neck fractures treated by Dr Nam's method. *J Korean Acad Oral Maxillofac Surg*. 6:25, 1980.