

Single Visit Internal Perforation Repair Using a Novel HCSC and an Internal Isolation Technique: A Case Series

Roberto Careddu, DDS, PhD¹, Ahmed Khaled, BDS², Hal Duncan, DDS, PhD³

¹Division of Restorative Dentistry and Periodontology, Dublin Dental University Hospital, Lincoln Place, Dublin 2, Ireland

²Private Practice, Dublin, Ireland

³Division of Restorative Dentistry and Periodontology, Dublin Dental University Hospital, Lincoln Place, Dublin 2, Ireland

DOI: [10.36347/sjds.2024.v1i102.001](https://doi.org/10.36347/sjds.2024.v1i102.001)

| Received: 16.03.2024 | Accepted: 24.04.2024 | Published: 29.04.2024

*Corresponding author: Roberto Careddu

Division of Restorative Dentistry and Periodontology, Dublin Dental University Hospital, Lincoln Place, Dublin 2, Ireland

Abstract

Case Series

Introduction: Communications between the root canal system and the external tooth surface are referred as perforations and are a common complication in the endodontic routine. Mineral Trioxide Aggregate is the gold standard material for perforation repair due to its characteristics such as biocompatibility and sealing ability. In recent years a lot of MTA-like products, commonly referred to as hydraulic cements or bioceramics, gained popularity as they set faster and are easier to handle compared to the classic MTA formulation. The standard perforation repair involves sealing the perforation first and then checking the setting of the material and completing the root canal treatment in a second visit. The internal isolation technique proposed in this case series is a novel, alternative method addressing the root canal treatment of a perforated tooth. **Materials and Methods:** Four cases are presented, each with a varying degree of perforation of the pulpal floor, all of them managed in single session treatments using the internal isolation technique. This technique involves the application of a fast setting hydraulic cement and its isolation from excessive water while completing the root canal treatment. The material thus can be allowed to sufficiently set before the end of the session, therefore allowing the finalisation of the complete therapy. **Results:** All the presented cases showed a positive outcome of the therapy. **Discussion:** The internal isolation technique appears to be a viable way to manage perforations while reducing the number of sessions required.

Keyword: Endodontic routine, bioceramics, pulpal floor, tooth surface, stripping[?].

Copyright © 2024 The Author(s): This is an open-access article distributed under the terms of the Creative Commons Attribution 4.0 International License (CC BY-NC 4.0) which permits unrestricted use, distribution, and reproduction in any medium for non-commercial use provided the original author and source are credited.

INTRODUCTION

Perforations are defined as communications between the root canal space and the external tooth surface and can be divided into apical, furcation or 'stripping' perforation according to the location and nature of the communication [1]. Iatrogenic perforations are an unfortunate event that can not only occur during root canal treatment phases such as access cavity and canal shaping, but also during prosthodontic procedures like post space preparation [2]. The most pertinent factors associated with an increased likelihood of perforation are the experience of the operator and type and morphology of the tooth [3].

Several materials have been used for non-surgical repair of perforations including amalgam, glass ionomer cement, Zinc Oxide Eugenol and gutta-percha with varying degrees of success [4, 5]. In most recent years, hydraulic calcium silicate cements (HCSCs) such as Mineral Trioxide Aggregate (MTA) and Biodentine

(Septodont, Saint Maur Des Fosses, France) have been marketed for perforation repair due to their bioactive properties and ability to promote tissue regeneration. Studies investigating the use of HCSCs for this purpose are promising with the induction of mineralised tissue formation and no or very little inflammatory response [4, 6-8].

Despite being the most appropriate perforation repair material, MTA still possesses some drawbacks like discolouration, poor handling properties and a long setting time [8-10]. Although Biodentine is easier to handle, sets faster and does not show discoloration issues, it has low radiopacity, a lower wash out resistance and a higher setting time compared with the 12 minutes stated by the manufacturer [11-13].

The currently recommended method for internal furcation repair initially requires the canals to be protected, prior to cleaning the defect, placing the HCSC

and coronally restoring with a temporary filling material. Re-entry is therefore necessary to assess the setting of the HCSC and complete the root canal treatment [14]. This method is not only time consuming, but also risks further damage by mechanical of microbial means to the perforation site.

The aim of this work was therefore to propose a single visit perforation repair and root canal treatment using a bespoke 'internal isolation technique' in order to allow the HCSC to set, protecting it from wash out while completing the root canal treatment.

Case Series

The three cases involved furcal perforation repair and sealing with Well-Root PT (Vericom, Chuncheon, Korea), a new HCSC based on calcium aluminosilicate in a putty formulation. It has a reported initial setting time of 5 ± 2 min and final setting of 45 ± 5 and exhibits high resistance to push out strength. The proposed technique involves the initial shaping of the root canals and their 'protection' from blockage with gutta-percha points or PFTE. The perforation site is thereafter cleaned and rinsed with a 2.5% NaOCl solution Well-Root PT is applied in at least 2mm thickness and covered completely with liquid dam (Dabliu Dam, Dental-world, Molfetta, Italy) after a period of 5 minutes. Next, all the phases of the root canal treatment are completed and after root canal obturation the liquid dam is removed and the hardness of the HCSC material is verified with a spoon excavator.

Case 1

A 28 year-old female patient was referred to another surgery due to the presence of copious bleeding in the mesio-buccal canal area of a lower right second

molar following an attempt to locate the mesio-buccal canal. She was asymptomatic. The preoperative periapical x-ray (Figure 1A) suggested the presence of a perforation and a small FOV 5x5 CBCT scan was taken to assess the damage. The CBCT scan confirmed the location of the mesio-buccal canal as well as the presence of a perforation involving the pulp chamber floor and part of the canal (Figures 1B and 1C).

After locating the root canal orifice (Figure 2A) and partially instrumenting the canal, a gutta-percha cone was placed in order to prevent the material blocking the lumen of the root canal (Figure 2B). Afterwards, the perforation was cleaned and carefully rinsed with 2.5% NaOCl and dried with sterile cotton wool pellets. Well-Root Pt was applied using a small amalgam plugger, before compaction and smoothing with a microbrush. The perforation site was then completely covered with liquid dam (Figure 2B).

The distal and mesio-lingual canals were next scouted, shaped, irrigated with 2.5% NaOCl and EDTA prior to sonic activation and sealing with single cone and a HCSC sealer (Fill-root ST, Dental-world, Molfetta, Italy). The gutta-percha that remained in the mesio-buccal canal was removed, the set of Well-Root assessed by scratching the material with an excavator and shaping, irrigation and filling was completed with the same protocol (Figures 2C and 3A). Due to patient fatigue, the tooth was restored at a second appointment using a fibre reinforced resin-based composite (Ever X Flow, GC, Tokyo, Japan) and a conventional resin-based composite (G-Aenial, GC, Tokyo, Japan). At two years follow up there is no evidence of pathology and the tooth remains asymptomatic (Figure 3B).

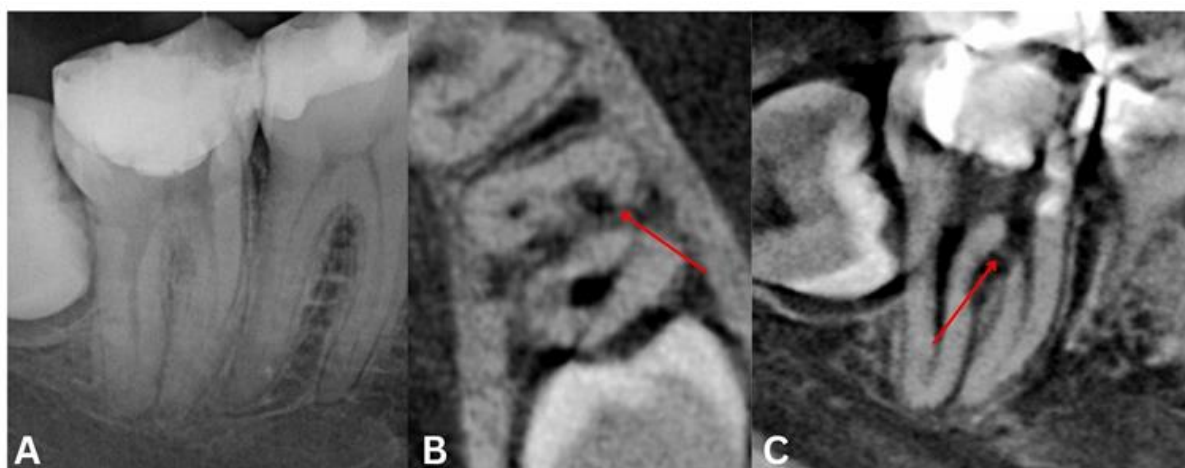

Figure 1: Case 1. Pre operative assessment of tooth 47. (A) The periapical x-ray showed an internal radiolucency in the mesial furcation area and a ledge on the distal canal. (B & C) The 3D imaging confirmed the presence of a perforation (red arrow) in the mesio-buccal furcation area

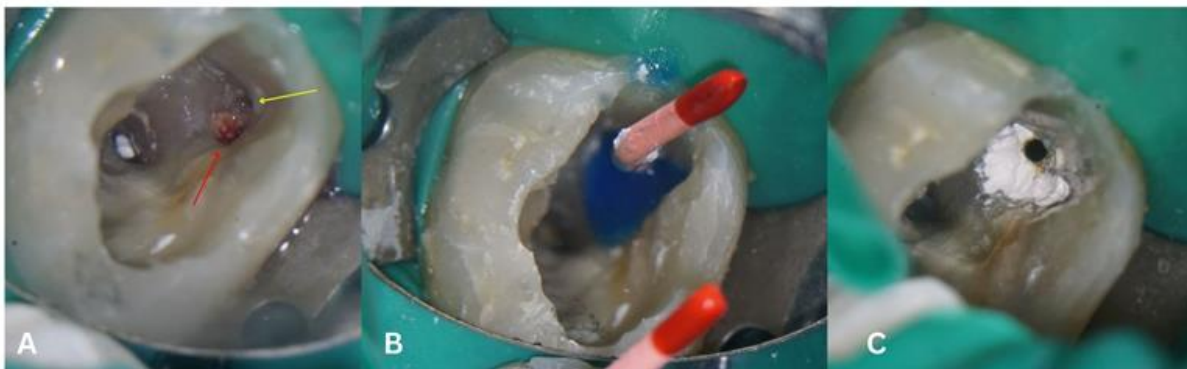

Figure 2: Case 1. Intra operative photos. (A) Detail of the perforation (red arrow) and position of the mesio buccal canal orifice (yellow arrow) in the mesio-buccal furcation area. (B) the canal was partially shaped and a gutta-percha point was placed in order to avoid material to penetrate the canal. The perforation was then closed with HCSC and the material was then isolated with liquid dam. (C) After completing the shaping and filling of the other canals, the gutta-percha and liquid dam present in the mesio-buccal canal was removed to allow assessing the setting of the material and completing the root canal treatment

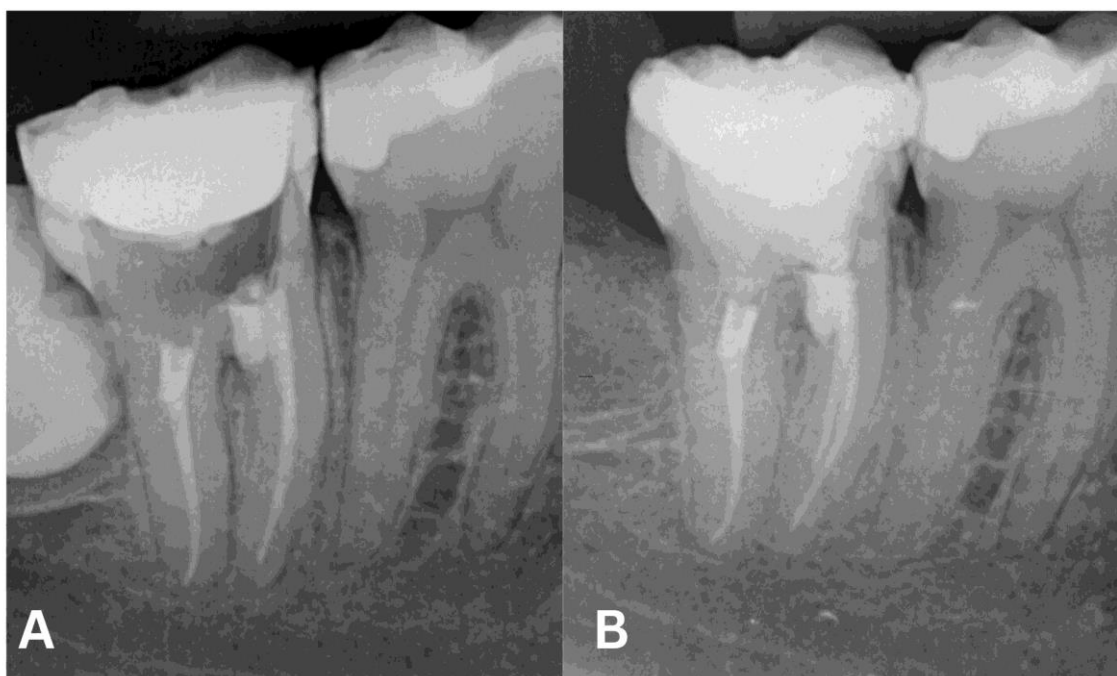


Figure 3: Case 1. Post operative periapical x-rays. (A) completed root canal treatment and temporary filling. (B) Follow up at two years showing no signs of apical pathosis or furcal radiolucency

Case 2

A 51 year-old female patient was referred by her dentist to a referral practice, with a report of a recent perforation that occurred while opening the pulp chamber during an emergency first stage root canal treatment on tooth 36 (Figure 4A). The patient attended the practice with a temporary filling of intermediate restorative material (IRM, Dentsply Sirona, Charlotte, North Carolina, USA) and a cotton wool pellet covering the canals (Figure 4B). The patient reported throbbing pain, that was not managed with analgesics and was disturbing sleep.

After initial instrumentation and protecting the canal orifices with gutta percha, the lesion was cleaned

with 2.5% NaOCl and sealed with Well-root PT and covered with liquid dam according to the proposed protocol (Figure 5A). Chemo-mechanical debridement with NaOCl/ EDTA was carried out prior to sonic activation and obturation with a warm vertical compaction technique. Thereafter the liquid dam was removed and the set of the HCSC assessed (Figure 5B). The tooth was restored in the same appointment using a fibre reinforced resin-based composite (Ever X Flow, GC, Tokyo, Japan) and a conventional resin-based composite restoration (G-Aenial, GC, Tokyo, Japan) (Figure 6A). The patient for financial reasons declined to have a cuspal coverage placed; however, at two and three year follow up the outcome of the treatment was successful (Figures 6B and 6C).

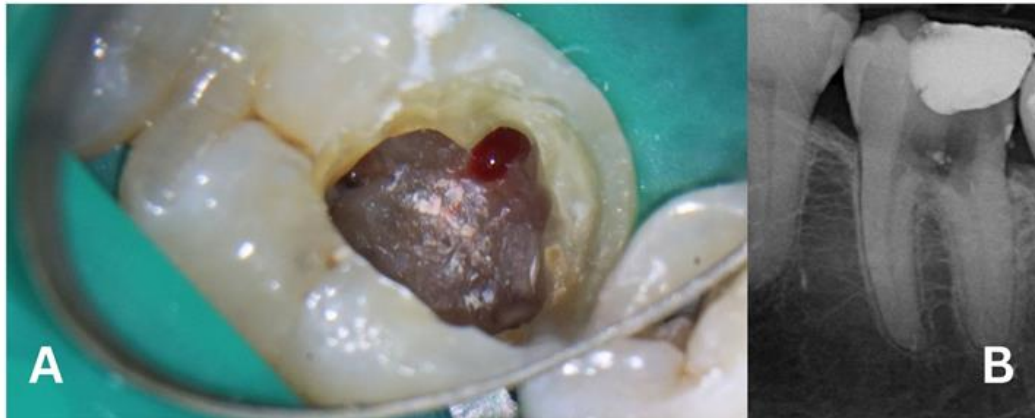


Figure 4: Case 2. Details of the perforation. (A) Intraoperative x-ray showing the perforation of the pulp chamber. (B) Pre operative x-ray where it is noticeable the position of the perforation

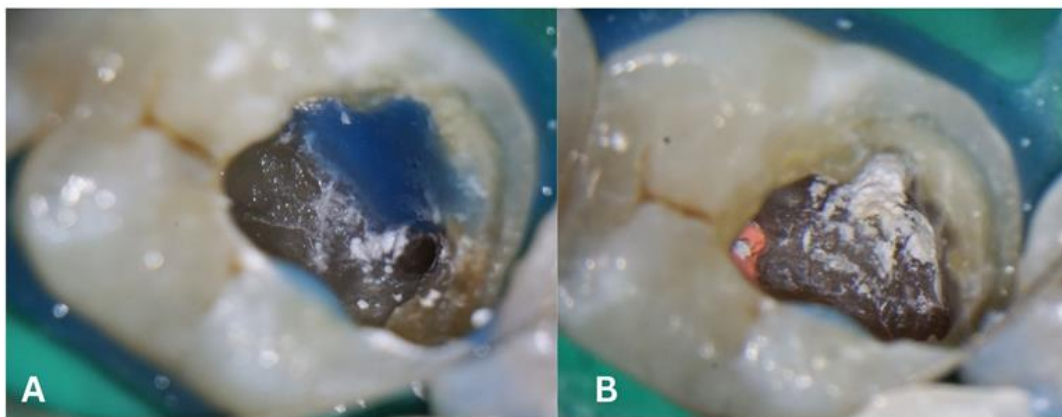


Figure 5: Case 2. Internal isolation. (A) The perforation was sealed with HCSC and covered with liquid dam while the root canal treatment was performed. (B) After completing the filling of the root canal system, the liquid dam was removed and the setting of the HCSC assessed

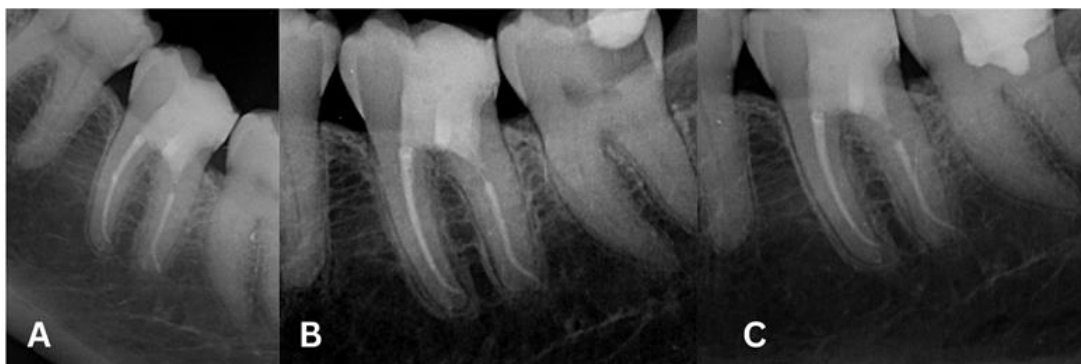

Figure 6: Case 2. (A) Post operative x-ray after restoring the tooth with fiber-reinforced resin. (B) Two years follow up. (C) Three years follow up

Case 3

A 48 year-old male patient presented to his dentist with a broken down 47, a history of several failed adhesive restoration and evidence of pulp necrosis. During the access opening a perforation was created and his dentist subsequently referred the case for perforation management, root canal treatment and post and core placement. The referring dentist provided a pre-operative PA (Figure 7A). During the appointment a C-shape canal was suspected, therefore a FOV CBCT 5x5 was taken to

better assess the case and avoid the potential of missed anatomy (Figure 7B). The CBCT scan confirmed the presence of two canals confluent in the mesial root and a single canal in the distal root.

The perforation was treated according to the protocol previously described and the root canal treatment was performed, while the HCSC was setting with liquid dam protection (Figure 8A). The final restoration was completed with a post and core as

requested by the referring dentist at the same appointment. After cementing the post, the tooth was filled with fibre reinforced resin-based composite (Ever X Flow, GC, Tokio, Japan) and a conventional resin-

based composite (G-Aenial, GC, Tokio, Japan) (Figure 8B). The tooth will be restored with crown by his dentist in the future.

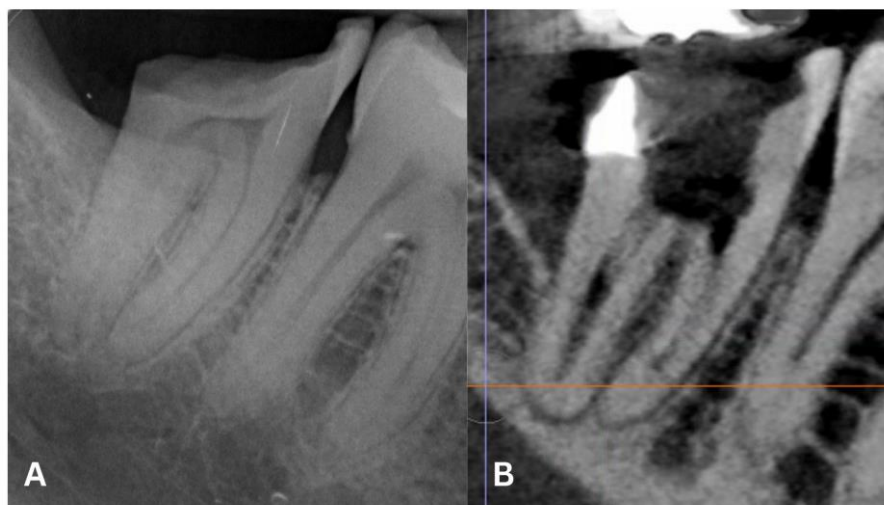

Figure 7: Case 3. Pre-operative radiographs. (A) X-ray taken by the referring dentist and sent with the referral and occurred prior to the perforation. (B) Pre-operative CBCT showing a perforation of the floor of the pulp chamber

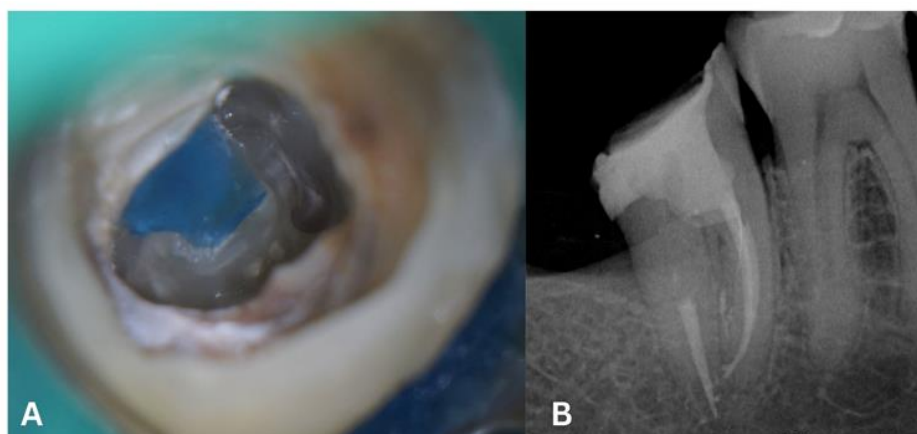


Figure 8: Case 3. (A) Internal isolation of the HCSC using liquid dam. (B) Post op x-ray. Perforation repair, root canal treatment and post and core placement were completed in a single session

Case 4

A 55 female patient was referred for a root canal treatment of a symptomatic 16 where was previously placed a dentatus post without carrying out an endodontic treatment but just a pulpectomy (Figure 9). The post was actually placed buccally in respect to the position of the palatal canal, causing a perforation. After the removal of the post, the palatal canal was scouted and grossly shaped before protecting it with a gutta-percha cone. Well- root and liquid dam were applied on the

perforation (Figure 10 A). The distal and mesiobuccal 1 and 2 canals were next scouted, shaped, irrigated with 2.5% NaOCl and EDTA prior to sonic activation and sealing with single cone and a HCSC sealer. The liquid dam and gutta-percha point were then removed from the palatal canal: the perforation appeared sealed with a fully set material and the canal maintained full patency (Figure 10B). After cleaning and obturating the palatal canal with single cone and HCSC sealer, the tooth was restored with fiber-reinforced resin (Figure 10C and 11).

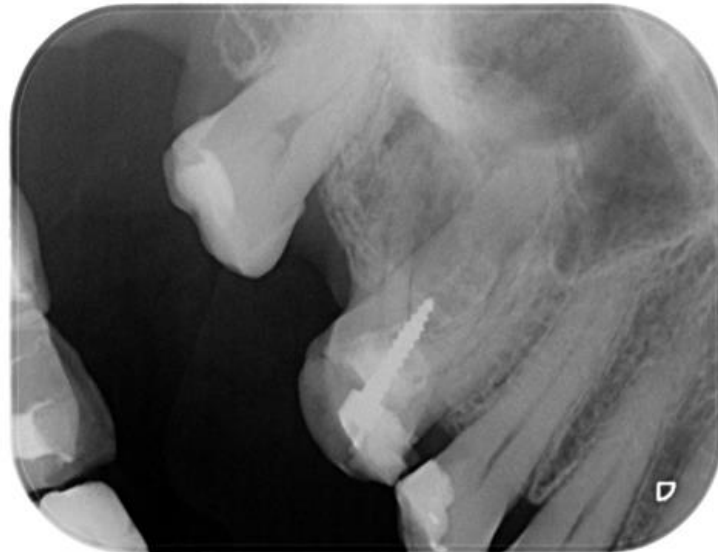


Figure 9: Case 4. Pre operative x-ray showing a not ideal root canal treatment and a restoration with a “dentatus” post on the palatal canal. The post was placed too buccally, perforating the root

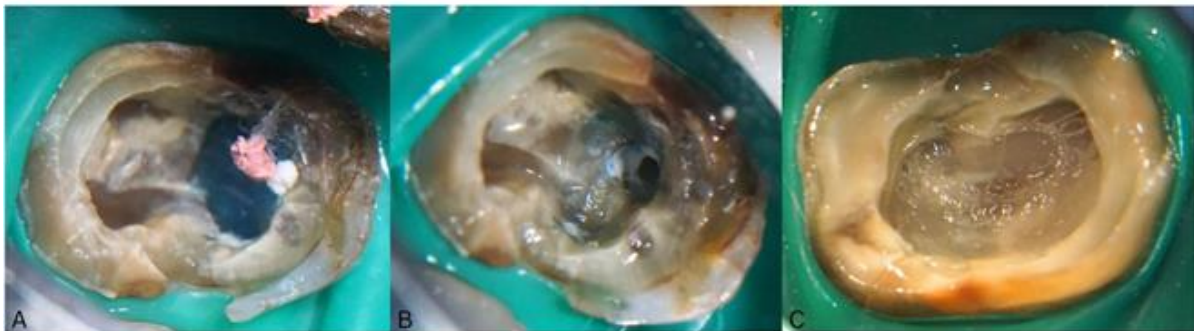


Figure 10: Case 4. Intra operative pictures. (A) The canal was protected with a guttapercha point and Well-Root PT was applied and covered with liquid dam. (B) Once removed the protecting gutta-percha point and liquid dam, a fully set material was found while the lumen of the canal was easy to access. (C) The tooth was then restored with fiber-reinforced resin

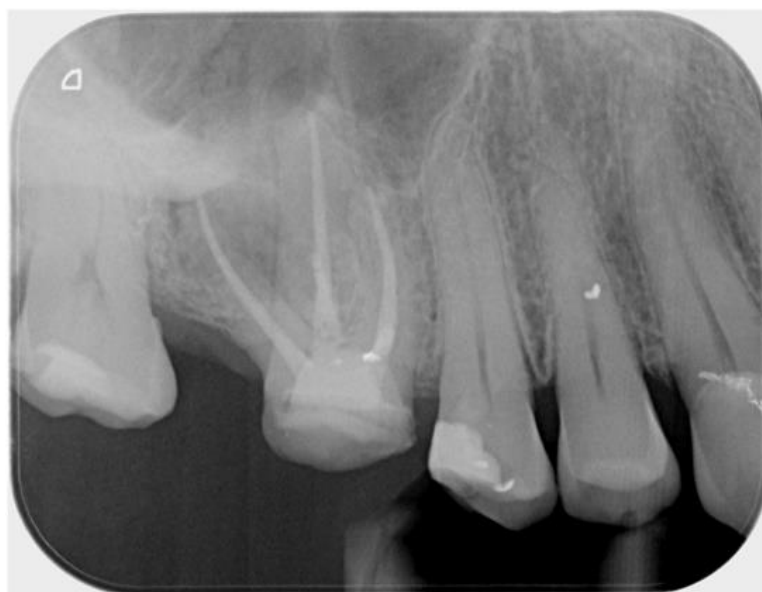

Figure 11: Case 4. Post Operative x-ray showing a completed root canal treatment and a direct restoration

DISCUSSION

Furcation and root canal perforation are common complications in endodontics and can be the result of deep penetrating caries, internal/external resorption or errors during several phases of the root canal treatment or post placement [8].

Historically, perforation repairs were approached surgically, however non-surgical perforation repair has demonstrated a high 72.5% overall success. This success rate was increased to 80.9% when the HCSC, MTA, was used.^{4,9} However, the material is not the only important factor for the outcome, as other factors, including the presence of a preoperative lesion and the contact between perforation and oral fluids have been shown to be important to success of the procedure [15].

Despite being considered the material of choice for perforation repair, MTA has drawbacks including discolouration, a long-setting time and can be technically difficult to handle [16]. In order to avoid these issues, other HCSCs have been proposed as alternatives to the classic MTA formulation, with recent evidence suggesting that they perform equally well and have practical advantages in various applications including perforation repair [11, 17].

The practicalities of single and multiple visit root canal treatment has been investigated with clear benefit with single visit endodontics with regards to timing and costs both for the patient and the dentist [18, 19]. The recommended protocol for root perforation repair traditionally included a second re-entry appointment to evaluate the hardness of the material and this was related of the long setting time of the original MTA formulations [14, 20].

In the current study Well-root PT was used, a new HCSC that presents an advertised initial setting time of 5 ± 2 min and final setting of 45 ± 5 . This allows the material to set in a time compatible with the completion of the root canal treatment. In order to not interfere with the setting process and prevent wash out, it is important to avoid the contacts between the material and endodontic irrigants such as NaOCl or EDTA. The placement of liquid dam after the initial setting of the material aimed to internally isolate the area of perforation, which allowed not only profuse use NaOCl and EDTA, but also activation of the irrigants without jeopardising or inhibiting the HCSC setting process. Only after the obturation of the root canal system was the liquid dam removed, allowing the operator to test the setting of Well-Root PT. In all four cases reported the material was set and allowed permanent restoration.

When considering the outcome of these cases it is important to note that in all four there was no contact between the perforation and oral fluids as well as the absence of a lesion at the time of repair, and were

performed by one experienced referral operator using the dental operating microscope [15, 21].

CONCLUSIONS

With the limitations of this study, the internal isolation technique with liquid dam, is a suitable and advantageous way to perform a single visit perforation repair and root canal treatment. Well-Root Pt is an easy to use and successful material to be used for perforation repair and, due to its short time setting, can be combined successfully with the proposed technique. However, further investigations are needed on a larger number of patients and multiple operators.

All the Authors declare no conflict of interest.

Author contribution:

Roberto Careddu: Conceptualization, Writing- original draft, Investigation

Ahmed Khaled: Conceptualization, Writing- Editing and reviewing,

Hal Duncan: Conceptualization, Writing- Editing and reviewing, Supervision

REFERENCES

1. American Association of Endodontists. *Glossary of Endodontic Terms*. 10th ed.; 2020.
2. Kvinnsland, I., Oswald, R. J., Halse, A., & Grønningsaeter, A. G. (1989). A clinical and roentgenological study of 55 cases of root perforation. *International endodontic journal*, 22(2), 75-84.
3. Sarao, S. K., Berlin-Broner, Y., & Levin, L. (2021). Occurrence and risk factors of dental root perforations: a systematic review. *international dental journal*, 71(2), 96-105. doi:10.1111/idj.12602
4. Siew, K., Lee, A. H., & Cheung, G. S. (2015). Treatment outcome of repaired root perforation: a systematic review and meta-analysis. *Journal of endodontics*, 41(11), 1795-1804. doi: 10.1016/j.joen.2015.07.007
5. Lodiene, G., Kleivmyr, M., Bruzell, E., & Ørstavik, D. (2011). Sealing ability of mineral trioxide aggregate, glass ionomer cement and composite resin when repairing large furcal perforations. *British dental journal*, 210(5), E7-E7. doi: 10.1038/sj.bdj.2011.198
6. Parirokh, M., & Torabinejad, M. (2010). Mineral trioxide aggregate: a comprehensive literature review—part III: clinical applications, drawbacks, and mechanism of action. *Journal of endodontics*, 36(3), 400-413. doi: 10.1016/j.joen.2009.09.009
7. Torabinejad, M., Parirokh, M., & Dummer, P. M. H. (2018). Mineral trioxide aggregate and other bioactive endodontic cements: an updated overview

- part II: other clinical applications and complications. *Int Endod J*, 51(3), 284-317. doi:10.1111/iej.12843
8. Aslan, T., Esim, E., Üstün, Y., & Özkan, H. D. (2021). Evaluation of stress distributions in mandibular molar teeth with different iatrogenic root perforations repaired with biodentine or mineral trioxide aggregate: a finite element analysis study. *Journal of endodontics*, 47(4), 631-640. doi: 10.1016/j.joen.2020.11.018
 9. Pinheiro, L. S., Kopper, P. M. P., Quintana, R. M., Scarparo, R. K., & Grecca, F. S. (2021). Does MTA provide a more favourable histological response than other materials in the repair of furcal perforations? A systematic review. *International endodontic journal*, 54(12), 2195-2218. doi:10.1111/iej.13617
 10. Careddu, R., & Duncan, H. F. (2018). How does the pulpal response to Biodentine and ProRoot mineral trioxide aggregate compare in the laboratory and clinic?. *British dental journal*, 225(8), 743-749. doi: 10.1038/sj.bdj.2018.864
 11. Kaur, M., Singh, H., Dhillon, J. S., Batra, M., & Saini, M. (2017). MTA versus Biodentine: review of literature with a comparative analysis. *Journal of clinical and diagnostic research: JCDR*, 11(8), ZG01-ZG05. doi:10.7860/JCDR/2017/25840.10374
 12. Grech, L., Mallia, B., & Camilleri, J. (2013). Investigation of the physical properties of tricalcium silicate cement-based root-end filling materials. *Dental Materials*, 29(2), e20-e28. doi: 10.1016/j.dental.2012.11.007
 13. Careddu, R., & Duncan, H. F. (2021). A prospective clinical study investigating the effectiveness of partial pulpotomy after relating preoperative symptoms to a new and established classification of pulpitis. *Int Endod J*, 54(12), 2156-2172. doi:10.1111/iej.13629
 14. Berman, L. H., & Hargreaves, K. M. (2020). *Cohen's Pathways of the Pulp - Louis H. Berman, Kenneth M. Hargreaves - 12th Edition (2020) 992 Pp., ISBN: 9780323673044.* <http://ebooks.elsevier.com>
 15. Krupp, C., Bargholz, C., Brüsehaber, M., & Hülsmann, M. (2013). Treatment outcome after repair of root perforations with mineral trioxide aggregate: A retrospective evaluation of 90 teeth. *J Endod*, 39(11), 1364-1368. doi: 10.1016/j.joen.2013.06.030
 16. Darvell, B. W., & Wu, R. C. T. (2011). MTA - An Hydraulic Silicate Cement: Review update and setting reaction. *Dental Materials*, 27(5), 407-422. doi: 10.1016/j.dental.2011.02.001
 17. Abdelmotelb, M. A., Gomaa, Y. F., Khattab, N. M. A., & Elheeny, A. A. H. (2021). Premixed bioceramics versus mineral trioxide aggregate in furcal perforation repair of primary molars: in vitro and in vivo study. *Clin Oral Investig*, 25(8), 4915-4925. doi:10.1007/s00784-021-03800-3
 18. Moreira, M. S., Anuar, A. S. N. S., Tedesco, T. K., dos Santos, M., & Morimoto, S. (2017). Endodontic Treatment in Single and Multiple Visits: An Overview of Systematic Reviews. *J Endod*, 43(6), 864-870. doi: 10.1016/j.joen.2017.01.021
 19. Manfredi, M., Figini, L., Gagliani, M., & Lodi, G. (2016). Single versus multiple visits for endodontic treatment of permanent teeth. *Cochrane Database of Systematic Reviews*, 2016(12). doi: 10.1002/14651858.CD005296.pub3
 20. Pace, R., Giuliani, V., & Pagavino, G. (2008). Mineral Trioxide Aggregate as Repair Material for Furcal Perforation: Case Series. *J Endod*, 34(9), 1130-1133. doi: 10.1016/j.joen.2008.05.019
 21. Estrela, C., Decurcio, D. de, A., Rossi-Fedele, G., Silva, J. A., Guedes, O. A., & Borges, Á. H. (2018). Root perforations: A review of diagnosis, prognosis and materials. *Braz Oral Res*, 32, 133-146. doi:10.1590/1807-3107bor-2018.vol32.0073