

Endocrown: An Alternative Approach for Restoring Endodontically Treated Molars

Cyrine Jebali¹, Zeineb Riahi^{1*}, Linda Ayadi¹, Dalenda Hadyaoui¹, Belhassen Harzallah¹, Mounir Cherif¹

¹Faculty of Dental Medicine of Monastir, University of Monastir

DOI: <https://doi.org/10.36347/sjds.2025.v12i03.001>

| Received: 14.03.2025 | Accepted: 19.04.2025 | Published: 24.04.2025

*Corresponding author: Zeineb Riahi

Faculty of Dental Medicine of Monastir, University of Monastir

Abstract

Case Report

Rehabilitating endodontically treated molars continues to be significantly challenging to dental practitioners. Following endodontic treatment, these molars often lose their mechanical integrity, necessitating innovative solutions for effective restorations. Endocrowns are considered nowadays as a promising option, consisting of single-unit prostheses performed with acid-etchable reinforced ceramics. They are specifically designed for molars that have experienced considerable loss of coronal structure. The aim of this report is to evaluate the indications and practical applications of endocrowns as an alternative to traditional single crowns. It includes a clinical case report detailing the fabrication of an endocrown restoration using lithium disilicate ceramic (IPS e.Max CAD) for a mandibular first molar with extensive coronal damage.

Keywords: Endocrown, endodontically treated tooth, minimally invasive dentistry, Bonding, tooth damage, restorative dentistry.

Copyright © 2025 The Author(s): This is an open-access article distributed under the terms of the Creative Commons Attribution **4.0 International License (CC BY-NC 4.0)** which permits unrestricted use, distribution, and reproduction in any medium for non-commercial use provided the original author and source are credited.

INTRODUCTION

Traditionally, the standard approach for restoring teeth with substantial structural loss involved the use of full-coverage crowns, often requiring extensive tooth preparation and the placement of radicular posts.

With the introduction of endocrowns, a more conservative and effective alternative has emerged. However, the success and durability of endocrowns depend on proper tooth preparation, selecting the most appropriate ceramic material, and ensuring optimal bonding. Adequate adhesive cementation is crucial for achieving a successful and long-lasting restoration. [1,2]

Reinforced, acid-etchable dental ceramics are the preferred materials for fabricating endocrowns due to their ability to provide the mechanical strength required to endure occlusal forces and ensure strong adhesion to the cavity walls [3,4].

The aim of this report is to present a clinical case featuring the restoration of a mandibular molar with extensive coronal destruction and prior endodontic

treatment using an aesthetic and conservative posterior endocrown. This work will also explore the indications, guidelines and applications of endocrowns.

CLINICAL CASE

A 25-year-old patient was referred to the fixed prosthodontics department at the dental clinic of Monastir for the restoration of her mandibular left first molar (tooth 46). Upon examination, the medical and family history revealed no significant details.

Radiographic and clinical examinations were conducted, with the periapical radiographic evaluation indicating satisfactory results for the endodontically treated root canals.

The patient had an acceptable oral hygiene and a favorable occlusion. Considering the amount of remaining tooth structure, the depth of the pulp chamber, and the thickness of the walls, a post-endodontic endocrown using a lithium disilicate ceramic endocrown fabricated from lithium disilicate ceramic (IPS e.Max CAD) was deemed appropriate.

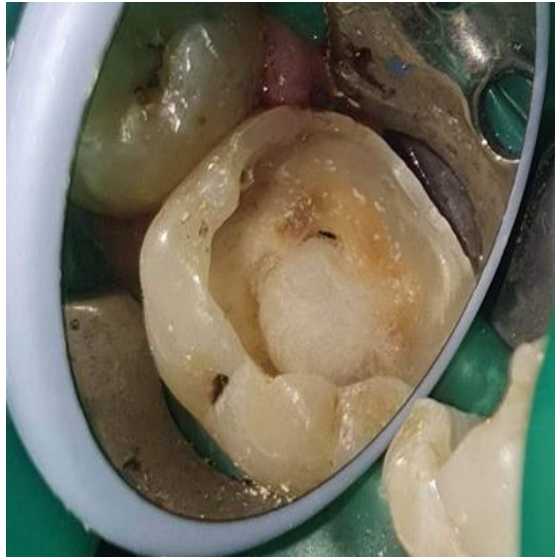

Figure 1: Pre-operative view of the endodontically treated molar

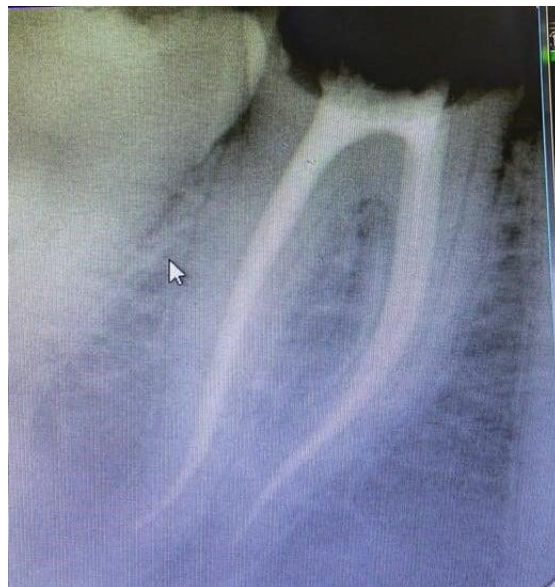

Figure 2: Preoperative intraoral periapical radiography

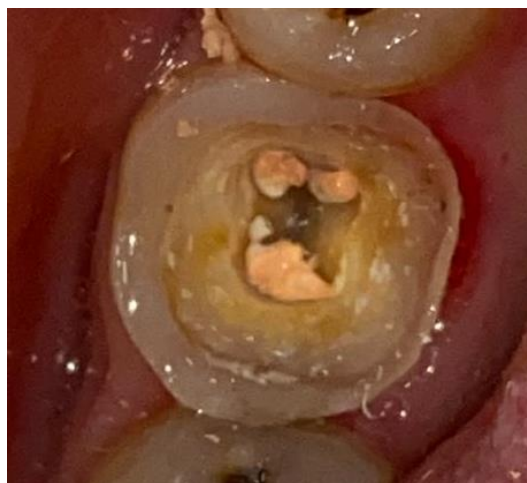

Figure 3: tooth preparation

The preparation for an endocrown differs from the conventional complete crown. In this case, the butt margin preparation type was selected due to the condition of the residual walls. The cervical margin was maintained supragingival, and any enamel walls measuring less than 2 mm width, were removed. Additionally, the buccal and lingual walls were

appropriately reduced to achieve an interocclusal clearance of 2 mm.

An impression was performed using polyvinyl siloxane with the putty-wash technique and sent to the laboratory for prosthesis fabrication. In the meantime, a provisional restoration was created from acrylic resin and luted with temporary cement.

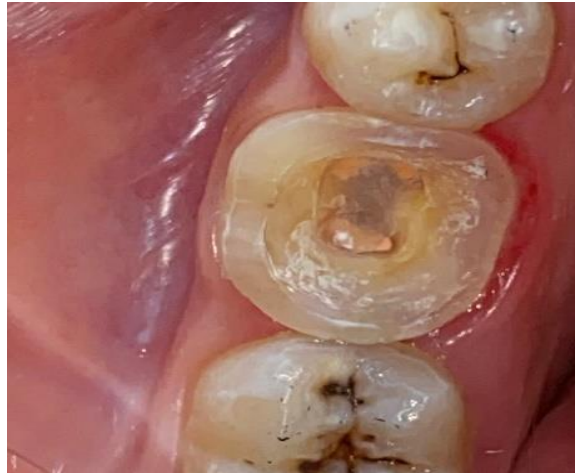

Figure 4: final preparation

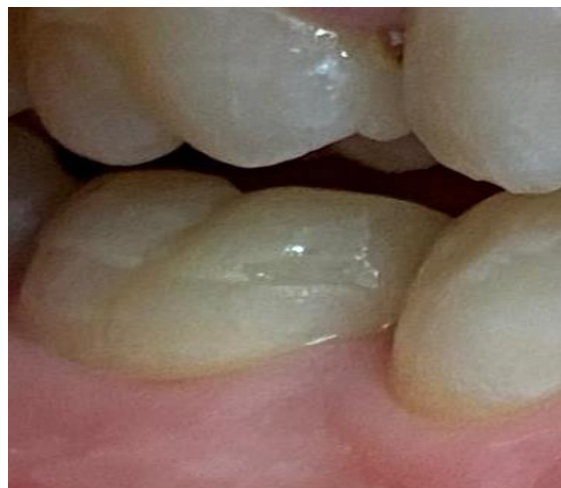

Figure 5: Temporary restoration



Figure 6: Impression made with polyvinyl siloxane material.

The impression was sent to the prosthetic laboratory, where the technician cast and scanned the models. The working model, antagonist model, and opposing models were scanned to accurately record the patient's occlusion.

The Endocrown restoration was fabricated using CAD/CAM milling technology (Computer-aided Design/Computer-aided Manufacture).

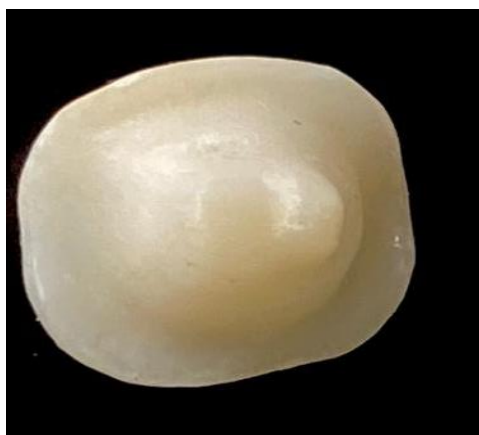

Figure7: Endocrown

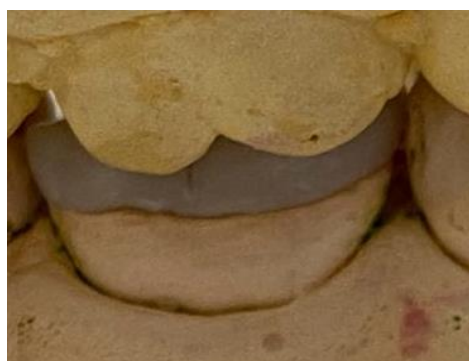

Figure 8: Fabricated endocrown on cast

Then, the endocrown try-in was conducted to assess occlusion and make any necessary internal and proximal adjustments.

Following this, we proceeded to the endocrown bonding. The first step of cementing the ceramic restoration involves properly preparing its inner surface by applying 5 to 10% hydrofluoric acid for twenty seconds, we then, rinsed the surface with water, and dried

it. This process dissolves the glass matrix, exposing the crystalline structure and creating surface microrugosities.

After that a coupling agent, a silane, was applied for 1 minute and dried, to create a chemical bond between the composite resin and the inorganic glass matrices.

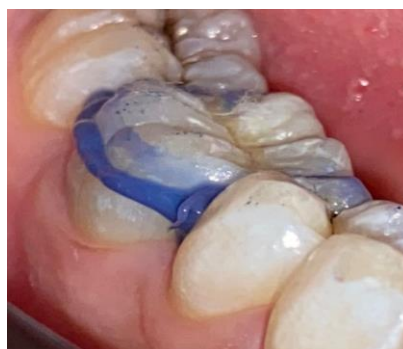

Figure 9: Try-in of the adaptation

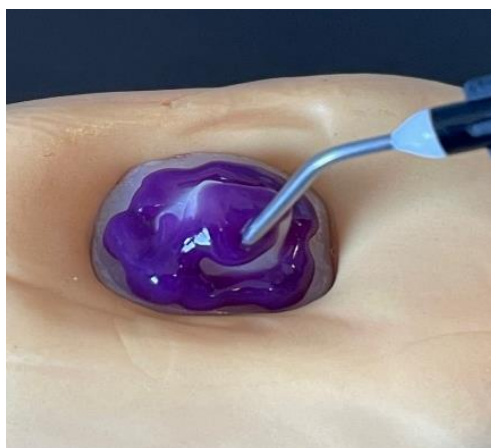

Figure 10: Etching the endocrown with hydrofluoric acid

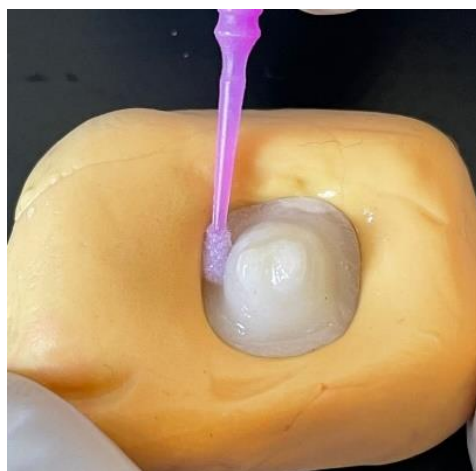

Figure 11: Application of silane coupling agent

Rubber dam isolation was performed on the prepared tooth surface, which was then etched with 37% phosphoric acid and applied for 15 seconds on the dentin and 30 seconds on the enamel. After thorough rinsing and drying, an adhesive was applied and polymerized with light curing for 20 seconds.

Finally, a dual-cure resin luting cement was applied to the intaglio surface of the endocrown and adhesively bonded to the prepared tooth surface. Light curing was performed for 5 seconds to facilitate the removal of any excess cement, followed by a 60-second curing on all surfaces.

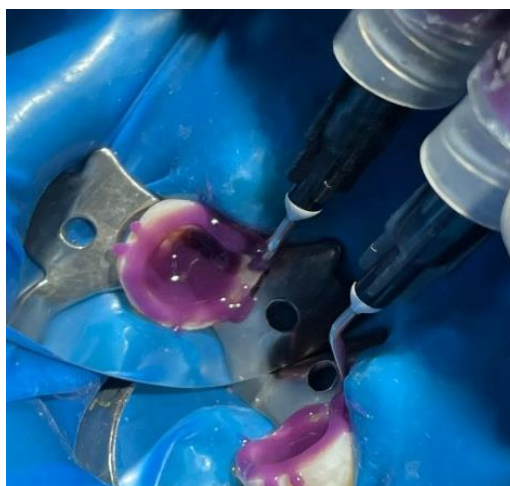

Figure 12: Acid-etching the tooth

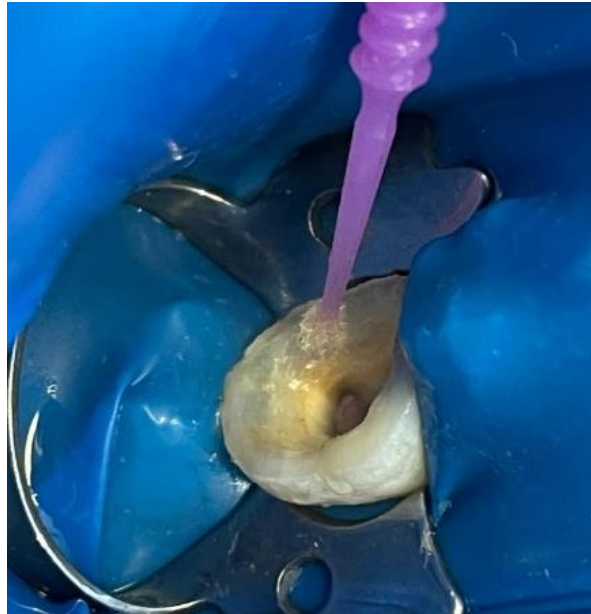

Figure 13: Application of the bonding agent



Figure 14: Light-curing the bonding agent

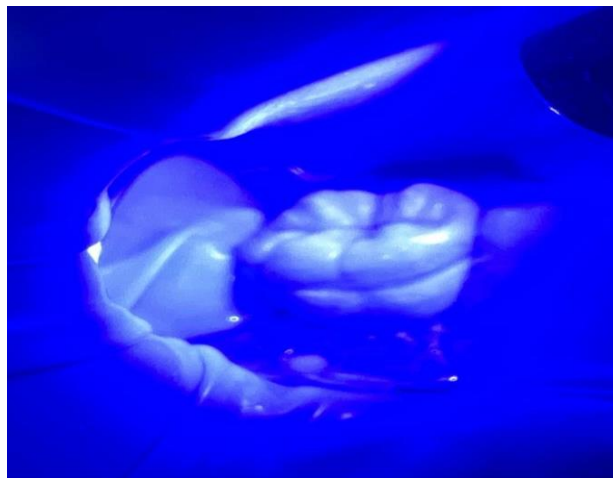


Figure 15: Application of the bonding resin and light-curing

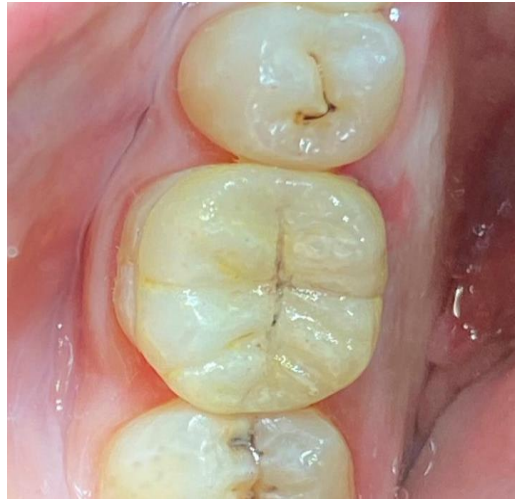

Figure 16: Final cementation

DISCUSSION

The restoration of endodontically treated teeth is a critical aspect of dental practice, aimed at reestablishing the anatomical, functional, and aesthetic integrity of teeth after root canal therapy [4,5]. Preserving the remaining healthy dental tissue is mandatory for long-term success; Therefore, endocrowns are valuable treatment options for cases involving significant loss of coronal tooth structure, as they require minimal preparation and optimize the tooth structure preservation. This approach doesn't only help maintain the integrity of the remaining tooth but also enhances the overall prognosis of the restoration by minimizing further damage to the tooth. Studies indicate that endocrowns exhibit superior fracture strength and lower failure rates in molars, making them a preferred choice in cases where traditional methods may compromise tooth integrity or require extensive preparation [6,7].

Sedrez-Porto *et al.*, conducted a systematic review to evaluate the clinical survival and the fracture strength of endocrown restorations compared to conventional treatments, such as iradicular posts, direct composite resins, and inlay/onlay restorations. Their findings suggest that endocrowns perform either as well as or better than these retorations [8].

Due to their minimally invasive preparation, endocrowns present a more advantageous treatment option compared to conventional crowns and post-and-core retained restorations. Several factors contribute to this positive outcome, including the preparation technique, occlusal thickness, and elastic moduli [9,10].

Endocrowns preserve more of the healthy tooth structure during preparation, which enhances the longevity of the restoration and reduces the risk of complications associated with more invasive procedures. Additionally, they are less time-consuming and cost-

effective, making them a preferred choice in many clinical situations [11].

The preparation principles for endocrowns emphasize minimal invasiveness and conservation of tooth structure, in this context, the butt margin design promotes effective retention and bonding, while also ensuring adequate occlusal thickness and proper surface treatment to enhance the restoration's durability and functionality [12,13].

When selecting materials for endocrown fabrication, it is ideal to use a material with a low modulus of elasticity similar to that of tooth structure, high mechanical strength, and sufficient bond strength to the underlying tooth [14].

A modulus of elasticity comparable to dentin helps distribute occlusal forces along the bonded surface and enhances fracture resistance. High mechanical strength is crucial for withstanding occlusal loads and preventing material fracture. Common materials for endocrowns include lithium disilicate glass-ceramic, which is favored for its excellent bonding strength and aesthetic qualities [15].

In this case report, the endocrown was fabricated from a lithium disilicate ceramic-based material, which offers several advantages over other materials, including superior aesthetics, adhesive properties, and mechanical interlocking with resin cement.

Research by Altier *et al.*, compared the fracture resistance of three types of endocrowns lithium disilicate ceramic and indirect resin composite and concluded that lithium disilicate ceramic endocrowns demonstrate greater fracture strength than indirect composites [5]. However, a more recent study by Tribst *et al.*, indicated that leucite-based materials provide better stress distribution and can be a reliable alternative to lithium disilicate for the fabrication of endocrowns [16].

The advancements in adhesive techniques allow a more effective bonding between the endocrown and the underlying tooth structure, which is crucial for the long-term success of the restoration [17,18].

With improved bonding ability, endocrowns can better withstand occlusal forces and reduce the risk of debonding, making them a reliable option for restoring extensively damaged teeth following endodontic treatment [19].

CONCLUSION

The indication of endocrowns offers a viable alternative to conventional post and core approaches, particularly for rehabilitating endodontically treated teeth with significant loss of coronal tissue. This restorative technique is primarily applicable to posterior teeth, demonstrating notably enhanced efficacy in molars compared to premolars [20]. However further clinical studies are required to demonstrate the longevity of this ceramic restoration.

REFERENCES

1. Dabbagh, R. A. (2021). Survival and success of endocrowns: A systematic review and meta-analysis. *The Journal of prosthetic dentistry*, 125(3), 415-e1.
2. Ciobanu, P., Manziuc, M. M., Buduru, S. D., & Dudea, D. (2023). Endocrowns – A literature review. *Medicine and Pharmacy Reports*, 96(3), 358–367.
3. Biacchi, G. R., Mello, B., & Basting, R. T. (n.d.). The endocrown: An alternative approach for restoring extensively damaged molars.
4. Dartora, N. R., Moris, I. C. M., Poole, S. F., Bacchi, A., Sousa-Neto, M. D., Silva-Sousa, Y. T., & Gomes, E. A. (2021). Mechanical behavior of endocrowns fabricated with different CAD-CAM ceramic systems. *The Journal of Prosthetic Dentistry*, 125(1), 117-125.
5. Altier, M., Erol, F., Yildirim, G., & Dalkilic, E. E. (2018). Fracture resistance and failure modes of lithium disilicate or composite endocrowns. *Nigerian journal of clinical practice*, 21(7), 821-826.
6. Kalghoum, I., Riahi, Z., Mejri, O., *et al.*, (2022). A new concept of posterior mini-invasive restorations: Clinical procedures and requirements—Case report. *CODS Journal of Dentistry*, 14(2), 61–66.
7. Zheng, Z., Wang, H., Mo, J., Ling, Z., Zeng, Y., Zhang, Y., ... & Yan, W. (2022). Effect of virtual cement space and restorative materials on the adaptation of CAD-CAM endocrowns. *BMC Oral Health*, 22(1), 580.
8. Sedrez-Porto, J. A., da Rosa, W. L. D. O., Da Silva, A. F., Münchow, E. A., & Pereira-Cenci, T. (2016). Endocrown restorations: A systematic review and meta-analysis. *Journal of dentistry*, 52, 8-14.
9. Fages, M., & Bennasar, B. (2013). The endocrown: A different type of all-ceramic reconstruction for molars. *Journal of the Canadian Dental Association*, 79, d140.
10. Menezes-Silva, R., Espinoza, C. A. V., Atta, M. T., Navarro, M. F. L., Ishikiriama, S. K., & Mondelli, R. F. L. (n.d.). Endocrown: A conservative approach. *Endocrown: uma abordagem conservadora*.
11. Heydecke, G., & Peters, M. C. (2002). The restoration of endodontically treated, single-rooted teeth with cast or direct posts and cores: A systematic review. *Journal of Prosthetic Dentistry*, 87(4), 380–386.
12. Riahi, Z., Kalghoum, I., Boudabous, E., Nouira, Z., Harzallah, B., Cherif, M., & Hadyaoui, D. (n.d.). Deep margin elevation: A modern practice to succeed posterior adhesive restorations
13. Akbar, I. (n.d.). Knowledge, attitudes and practice of restoring endodontically treated teeth by dentists in North of Saudi Arabia. Department of Conservative Dentistry, College of Dentistry, Aljouf University, Sakaka, Saudi Arabia.
14. Nayak, M., & Jose, A. (2020). Endocrown: An option for rehabilitation of badly mutilated tooth – A case report. *International Journal of Applied Dental Sciences*, 6(1), 30–33.
15. Rocca, G. T., & Krejci, I. (2013). Crown and post-free adhesive restorations for endodontically treated posterior teeth: from direct composite to endocrowns. *Eur J Esthet Dent*, 8(2), 156-79.
16. Tribst, J. P. M., Dal Piva, A. M. D. O., Madruga, C. F. L., Valera, M. C., Borges, A. L. S., Bresciani, E., & de Melo, R. M. (2018). Endocrown restorations: Influence of dental remnant and restorative material on stress distribution. *Dental Materials*, 34(10), 1466-1473.
17. Lander, E., & Dietschi, D. (2008). Endocrowns: a clinical report. *Quintessence international*, 39(2).
18. Carlos, R. B., Thomas Nainan, M., Pradhan, S., Sharma, R., Benjamin, S., & Rose, R. (2013). Restoration of endodontically treated molars using all ceramic endocrowns. *Case reports in dentistry*, 2013(1), 210763.
19. Sevimli, G., Cengiz, S., & Oruç, S. (2015). Endocrowns. *Journal of istanbul university faculty of dentistry*, 49(2), 57-63.
20. Wazurkar, S., Patel, A., Mahapatra, J., Nadgouda, M., & Pawar, L. (n.d.). Endocrown: A conservative approach in the management of endodontically treated teeth. Sharad Pawar Dental College and Hospital, Datta Meghe Institute of Higher Education and Research, Wardha, India.