

Use of the LI-RADS Classification to Characterize Liver Tumor: Experience of the Radiology Department at the Avicenne Military Hospital in Marrakech (HMA)

Z. Maflah^{1*}, Pr B. Slioui¹, Pr S. Bellasri¹, Pr N. Hammoune¹, Pr M. Atmane¹, Pr A. Mouhsine¹

¹Department of Radiology, Avicenne Military Hospital, Marrakech, Morocco

DOI: <https://doi.org/10.36347/sjmcr.2025.v13i05.096>

| Received: 06.04.2025 | Accepted: 11.05.2025 | Published: 24.05.2025

*Corresponding author: Z. Maflah

Department of Radiology, Avicenne Military Hospital, Marrakech, Morocco

Abstract

Case Report

The Liver Imaging Reporting and Data System (LI-RADS) classification is a standardized tool for characterizing liver lesions in groups at risk of hepatocellular carcinoma (HCC). This article presents an assessment of its clinical usefulness through a retrospective study carried out at the Avicenne Military Hospital in Marrakech.

Keywords: LI-RADS System - Hepatocellular Carcinoma - Liver Tumor – Imaging.

Copyright © 2025 The Author(s): This is an open-access article distributed under the terms of the Creative Commons Attribution **4.0 International License (CC BY-NC 4.0)** which permits unrestricted use, distribution, and reproduction in any medium for non-commercial use provided the original author and source are credited.

INTRODUCTION

The Liver Imaging Reporting and Data System (LI-RADS) classification is a standardized tool for characterizing liver lesions in groups at risk of hepatocellular carcinoma (HCC). This article presents an assessment of its clinical usefulness through a retrospective study carried out at the Avicenne Military Hospital in Marrakech.

Objectives

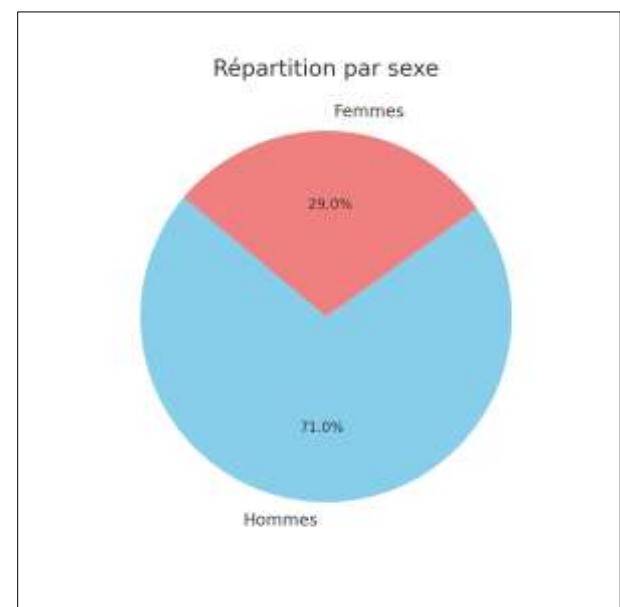
- Assess the value of the LI-RADS system for characterizing liver tumors.
- Identify the advantages of LI-RADS in clinical communication.
- Study the system's diagnostic performance.

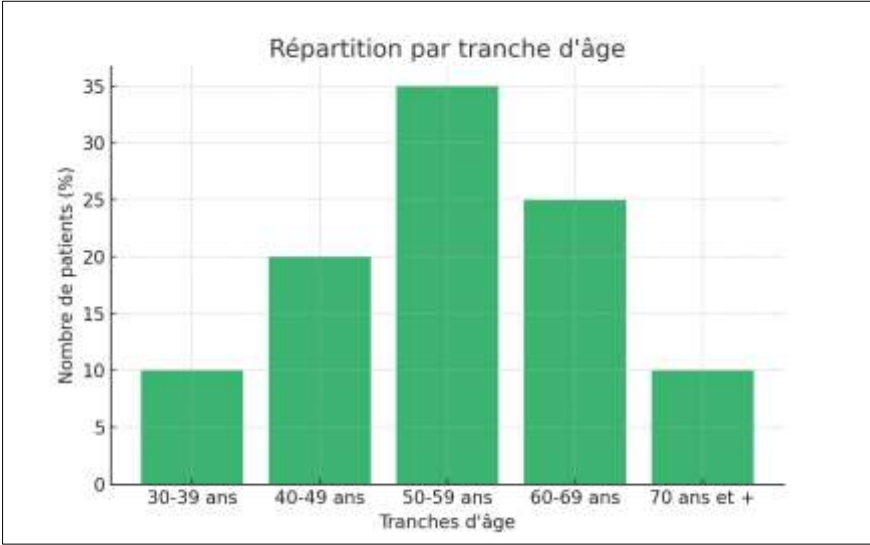
MATERIALS AND METHODS

Retrospective descriptive study conducted at the Avicenne Military Hospital in Marrakech between January 2020 and December 2022. 100 patients were included according to precise inclusion criteria. MRI and CT were used with systematic application of LI-RADS v2018.

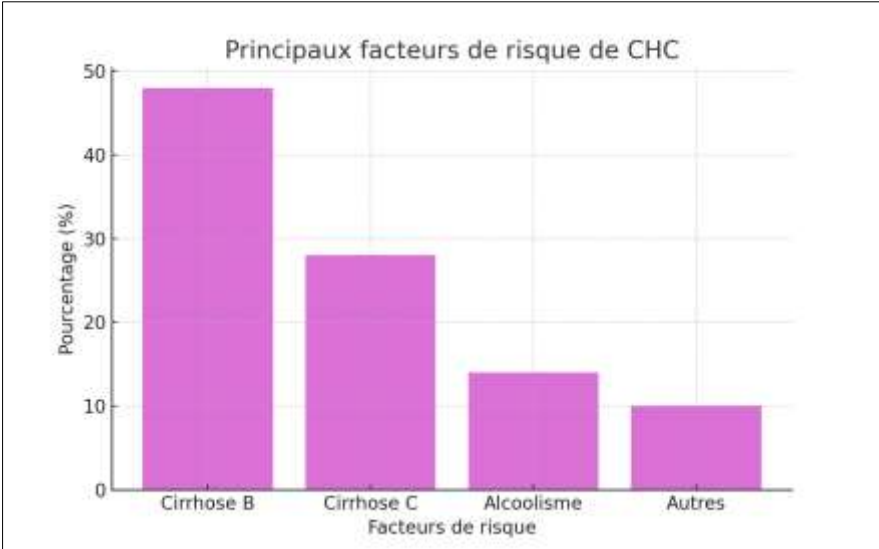
RESULTS

1. Epidemiological Characteristics

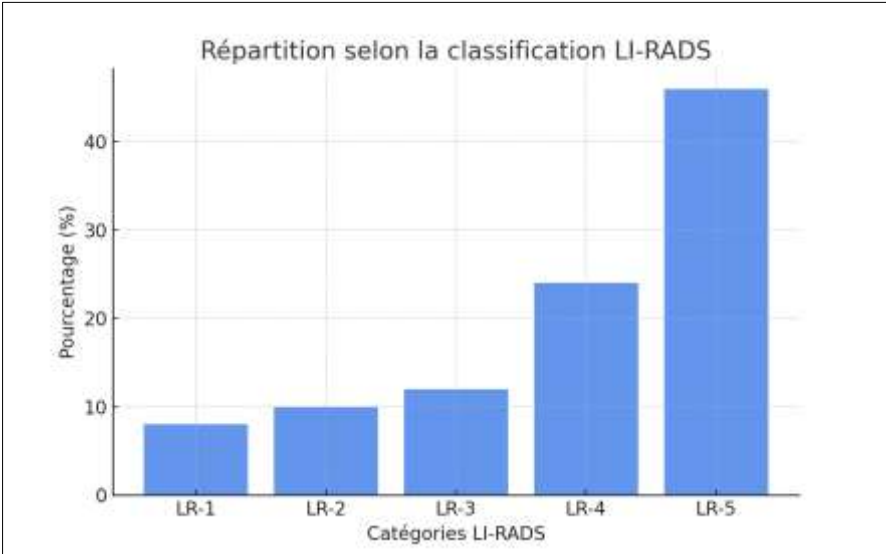




2. Risk Factors



3. Distribution by LI-RADS



The majority of patients (46%) were classified as LR-5, corresponding to a virtually certain diagnosis of HCC. Histological correlation confirmed this diagnosis in 94% of cases.

DISCUSSION

The LI-RADS (Liver Imaging Reporting and Data System) classification was born out of the need to standardize the communication, diagnosis and management of liver lesions in high-risk hepatocellular carcinoma (HCC) settings. It has become a reference tool for liver imaging, comparable to the BI-RADS for breast cancer.

Importance and Main Contributions

In our series of 15 patients followed between 2020 and 2023:

- The application of LI-RADS enabled a close correlation between the categories assigned on imaging and histological diagnoses.
- The LR-1 and LR-2 lesions were all benign (hemangioma, biliary cyst).
- 100% of LR-5 lesions were histologically confirmed HCC.
- LR-4 lesions were of more uncertain diagnostic value, split between early-stage HCC and other malignancies (e.g. cholangiocarcinomas).

Thus, the LI-RADS system, using major (arterial hypervascularization, wash-out, enhanced capsule, nodule size) and minor criteria, has made it possible to avoid systematic recourse to biopsy.

Hypervascularisation à la phase artérielle (HVPA)		Pas de HVPA		HVPA non-périphérique		
Taille de l'observation (mm)		< 20	≥ 20	< 10	10-19	≥ 20
Nombre de critères majeurs: • « Capsule » se rehaussant • « Lavage » non-périphérique • Croissance supérieure au seuil de progression	Aucun	LR-3	LR-3	LR-3	LR-3	LR-4
	Un	LR-3	LR-4	LR-4	LR-4	LR-5
	≥ Deux	LR-4	LR-4	LR-4	LR-5	LR-5

Les observations dans ces cellules sont classées selon le critère majeur additionnel

- LR-4 - si « capsule » se rehaussant
- LR-5 - si « lavage » non périphérique ou croissance supérieure au seuil de progression

En cas d'incertitude sur la présence d'un critère majeur: considérer le critère comme absent

Figure1: LI-RADS categories

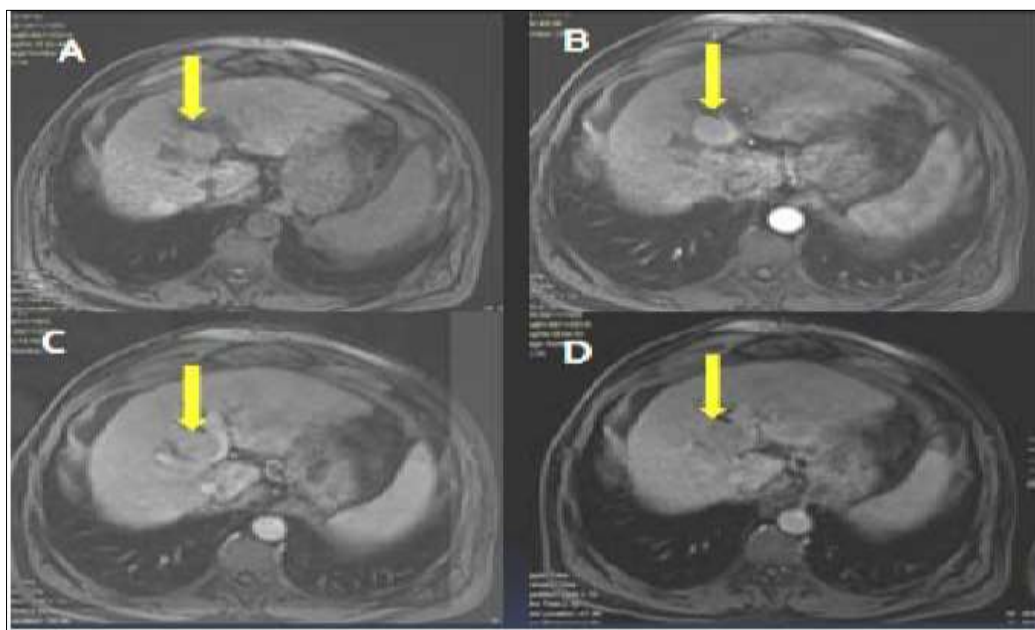


Figure 2: Liver MR: T1 fatsat-weighted sequence before and after Gadolinium injection at portal arterial time and late segment IV lesion with hypo T1 signal (A) enhanced at portal arterial time arterial (B) with portal lavage (C) AND individualization of an enhanced pseudocapsule at late time (D)

Comparison with international series

Several major works corroborate our observations:

- Hongyu Jin *et al.*, have shown that the LR-5 category achieves a sensitivity of 73% and a specificity of 88% for the diagnosis of HCC.
- Puengphong *et al.*, reported a sensitivity of 82.8% and a specificity of 94.7% for LR-5.
- Our study found similar performance, with a specificity of 100% for LR-5, reinforcing the value of this score for making a definitive diagnosis without invasive histological confirmation.

In addition, a recent systematic review reports an overall performance of the LI-RADS system, all categories combined, with a sensitivity of 89.5% and a specificity of 88.6%.

LI-RADS Strengths Highlighted in Our Study

- **Reliability:** High concordance between image classification and pathology.
- **Standardization:** Enables clear communication between radiologists, hepatologists, surgeons and oncologists.
- **Therapeutic orientation:** Decisions (abstention, monitoring, removal, transplantation) are facilitated according to the category assigned.
- **Longitudinal follow-up:** Allows rigorous monitoring of LR-3/LR-4 nodules, with adjustment of treatment according to progress.

Identified Limits

- Sample size reduced to 15 patients, due to collection difficulties during the COVID-19 pandemic.
- Lack of complete clinical data in some files, impacting the accuracy of correlations.
- No comparison between modalities (CT vs. MRI) in diagnostic accuracy.

- Atypical nodules (notably LR-4) may require biopsy or prolonged follow-up.

Prospects for Improvement

- Use of MRI with hepatobiliary agents to increase detection of small HCC.
- Development of artificial intelligence models to automate interpretation of LI-RADS criteria.
- Ongoing training for radiologists to ensure consistent application of the criteria.

Our study confirms that systematic use of the LI-RADS classification improves:

- Accurate non-invasive diagnosis of HCC,
- Multidisciplinary communication,
- And it contributes to better therapeutic orientation, by reducing unnecessary recourse to biopsy.

These results are perfectly in line with those published in major international journals.

CONCLUSION

The LI-RADS classification provides a reliable, reproducible and standardized tool for the diagnosis of liver tumors, particularly HCC, optimizing management and medical communication.

REFERENCES

- American College of Radiology. Liver Imaging Reporting and Data System (LI-RADS) v2018.
- Elsayes KM, *et al.*, 2017 LI-RADS Version 2017 Core. Radiology. 2017.
- Forner A, Reig M, Bruix J. Hepatocellular carcinoma. Lancet. 2018;391(10127):1301-1314.
- Sirlin CB, *et al.*, LI-RADS v2018 Diagnostic Algorithm. Radiology. 2018;289(3):816-830.