

## Multimodality Evaluation of Shoulder Pathologies

Taori, Abhijeet<sup>1\*</sup>, Malpani, Divya<sup>2</sup>

<sup>1</sup>Assistant Professor, Department of Radiodiagnosis, SAMC and PGI, Indore

<sup>2</sup>Consultant, Department of Radiodiagnosis, Suyash Hospital, Indore

DOI: <https://doi.org/10.36347/sjams.2024.v12i12.037>

| Received: 18.11.2024 | Accepted: 25.12.2024 | Published: 31.12.2024

\*Corresponding author: Dr. Abhijeet Taori

Assistant Professor, Department of Radiodiagnosis, SAMC and PGI, Indore

### Abstract

### Original Research Article

**Introduction:** A wide plethora of Shoulder Pathologies are frequently encountered in patients presenting with shoulder pain. They are routinely evaluated using High Resolution Ultrasonography, Magnetic Resonance Imaging and Arthrography. Despite good diagnostic accuracy in using each of these modalities, certain limitations persist. **Aims and Objectives:** To recognize common pathologies of the Shoulder on Ultrasonography and Magnetic Resonance Imaging. Correlate Ultrasonography and Magnetic Resonance Imaging findings and establish the superiority and determine diagnostic modality of choice for various pathologies. **Results:** Overall detection rates (sensitivity) of any kind of rotator cuff tears using ultrasound were 78.38 %. This sensitivity difference was statistically very significant. US has a very high specificity rate of 90.91 %. Ultrasound suffers severe handicaps when it comes to study the labroligamentous complex injuries in patients with instability, Whereas MRI proved to be far superior in labroligamentous complex injuries. **Conclusion:** High Resolution Ultrasonography and Magnetic Resonance Imaging are excellent modalities with high efficiency in the detection of various shoulder pathologies, provided user is adequately experienced / trained and familiar with complex shoulder anatomy. MRI is a versatile investigation tool for studying all shoulder pathologies affording great soft tissue contrast and multi-planar imaging and ultrasound has significant clinical applications outside rotator cuff evaluation.

**Keywords:** Rotator Cuff, Ultrasound, MRI, Shoulder.

Copyright © 2024 The Author(s): This is an open-access article distributed under the terms of the Creative Commons Attribution 4.0 International License (CC BY-NC 4.0) which permits unrestricted use, distribution, and reproduction in any medium for non-commercial use provided the original author and source are credited.

## INTRODUCTION

Of all the things that make human beings unique, one that gets overlooked literally is the shoulder. It has been proved out that the shoulder altered the course of human evolution by giving humans survival skills. Because it is pointing straight out, human arms are allowed to just about hang freely, and hence can flex arms at the elbow and have hands out front, which is useful for manipulation whereas in apes, the joint actually points almost toward the ceiling [1].

A wide plethora of Shoulder Pathologies are frequently encountered in patients presenting with shoulder pain. They are routinely evaluated using High Resolution Ultrasonography, Magnetic Resonance Imaging and Arthrography [2]. Despite good diagnostic accuracy in using each of these modalities, certain limitations persist.

The location of shoulder pain is a poor indicator of its origin, and the value of clinical examination alone is often limited with regard to making a decision for further management with certainty. The results of the

imaging of the shoulder may have clinical consequences as the decision to proceed with surgery or to continue conservative management depends on the accurate diagnosis of the nature of shoulder pathology [3].

### Study Aims and Objectives

1. To recognize common pathologies of the Shoulder on Ultrasonography and Magnetic Resonance Imaging
2. Correlate Ultrasonography and Magnetic Resonance Imaging findings and establish the superiority and determine diagnostic modality of choice for various pathologies

## MATERIALS AND METHODS

Study was conducted in Department of Radiodiagnosis, Suyash Hospital, Indore. This hospital based prospective study which will be conducted on the basis of data collected through proforma and radiological investigations from Jan 2022 to December 2022. Patients with symptoms of shoulder pathology and subsequently referred to Department of Radiodiagnosis will comprise the study population.

### Study Technique

All Patients with shoulder Pathology/Pain consenting to be a part of study will be initially evaluated using Philips iU22 or GE Voluson E8 Ultrasonography machine by L12-5 MHz Linear Probe in all planes followed by Magnetic Resonance Imaging with Siemens Spectra 96 Channel 3 Tesla machine using shoulder coil.

## RESULTS AND DISCUSSION

Males (77.15 %) were the majority and right shoulder (67.14 %) was more commonly affected than the left shoulder. Maximum patients were in the 41 to 60 year age range (38.57 %). Rotator cuff disorders affected older population compared to instability. Pain was the most common complaint in almost 45.71 % patients. Acromion morphology was studied under three types, of which Type II was most common (49 %)

Degenerative disease (52.86 %) and Trauma (27.14 %) were the most common etiologies. There were 24 patients with primary rotator cuff pathologies, 26 with instability and 20 patients with miscellaneous disorders. Both MRI and US diagnosed full thickness Supraspinatus tears with excellent and comparable sensitivity (100 %) and specificity (100 %). MRI was significantly superior to US in the detection to partial thickness Supraspinatus tears (80 % Sensitivity for US).

Overall detection rates (sensitivity) of any kind of rotator cuff tears using ultrasound were 78.38 %. This sensitivity difference was statistically very significant. US has a very high specificity rate of 90.91 %. Sensitivity of MRI is higher compared to ultrasound for any kind of rotator cuff tears with statistic significance.

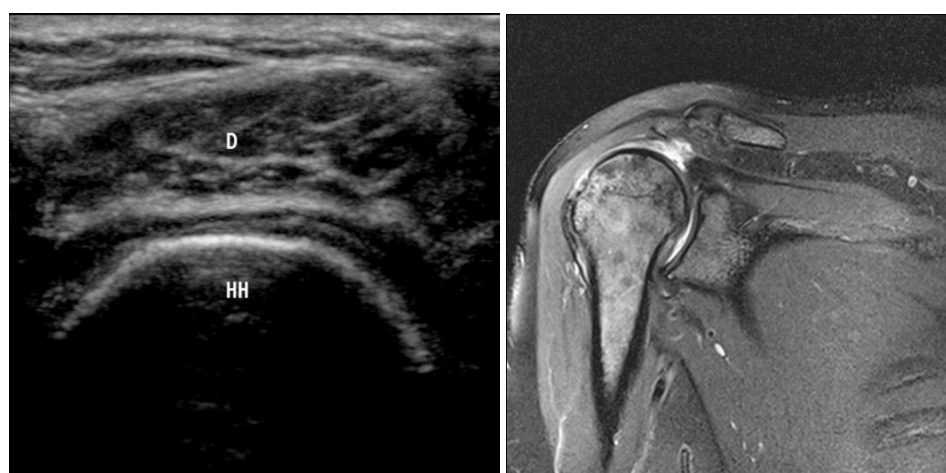
Thus there was high value for a positive or a negative report of a rotator cuff tear in predicting the diagnostic outcome using ultrasound.

Ultrasound suffers severe handicaps when it comes to study the labroligamentous complex injuries in patients with instability, Whereas MRI proved to be far superior in labroligamentous complex injuries. Bankarts lesion was the most common anteroinferior glenoid injury, with bony Bankarts lesion amenable to detection with ultrasound also, though it is deep and difficult to detect. Hill Sachs lesion was the most common detected lesion in instability and was well demonstrated and quantified on both MRI and US (77.78 %) with slight more efficiency on MRI (100 %).

Among miscellaneous pathologies, ultrasound and MRI both diagnosed two cases of infective arthritis and a case of subscapularis muscle tear. Three cases with tumors were diagnosed on MRI. Isolated GLAD lesion was suggested on MRI.

MRI is a versatile investigation tool for studying all shoulder pathologies affording great soft tissue contrast and multi-planar imaging [4].

The clinical applications of High Resolution Ultrasonography have been extended apart from rotator cuff evaluation, also the detection of Hill Sachs lesion, bony Bankart lesion, synovial thickening, effusions in joint and in subacromial bursa, bone irregularity, biceps tendinosis, rotator cuff calcifications and major muscle tears apart from guiding needle for MR arthrographic contrast injection. However it suffers serious drawbacks in evaluation of labral and cartilaginous lesions [5].



**Fig. 1: a (US) and b (MRI Coronal, PD FS Image) US Image shows complete absence of Supraspinatus tendon over humeral head with deltoid in direct opposition with humerus. Corresponding MRI image show PD FS Hyperintense signal throughout substance of Supraspinatus tendon with retraction of Supraspinatus muscle belly suggesting complete tear of supraspinatus tendon**

## CONCLUSION

High Resolution Ultrasonography and Magnetic Resonance Imaging are excellent modalities

with high efficiency in the detection of various shoulder pathologies, provided user is adequately experienced / trained and familiar with complex shoulder anatomy.

MRI is a versatile investigation tool for studying all shoulder pathologies affording great soft tissue contrast and multi-planar imaging and ultrasound has significant clinical applications outside rotator cuff evaluation.

**Declaration:** None

**Conflict of interest:** None

**Funding:** None

## BIBLIOGRAPHY

1. E. McCrum, "MR imaging of the rotator cuff," *Magnetic Resonance Imaging Clinics of North America*, vol. 28, no. 2, pp. 165–179, 2020.
2. Park J, Choi YH, Chai JW, et al. Anterior capsular abnormality: another important MRI finding for the diagnosis of adhesive capsulitis of the shoulder. *Skeletal Radiol* 2019; 48:543–552
3. Beggs I Shoulder ultrasound *Semin Ultrasound CT MR*. 2011 Apr; 32(2):101-13.
4. Huang BK et al Imaging of the rotator cuff *Sports Med Arthrosc*. 2011 Sep;19(3):279-99.
5. Papatheodorou A, Ellinas P, Takis F, Tsanis A, Maris I, Batakis N. US of the shoulder: rotator cuff and non-rotator cuff disorders. *Radiographics*. 2006 Jan-Feb;26(1):e23.