

Perioperative and Early Postoperative Outcomes Following Limberg Flap Surgery for Pilonidal Sinus

Dr. Rakesh Sah^{1*}, Dr Chowdhury Sazzad Hyder², Dr. Deepak Kumar Yadav³, Dr. Muhammad Ali Siddiquee⁴, Dr. Akanand Singh⁵, Prof. Dr. Md. Shahadat Hussain⁶, Dr. Mr Bishow Karki⁷, Dr Prarthana Subedi⁸

¹Consultant, Department of Colorectal Surgery, Everest Hospital, Kathmandu, Nepal

²Associate Professor, Department of Surgery, Shaheed Suhrawardy medical College, Dhaka, Bangladesh

³Registrar, Department of Anaesthesia, Critical Care and Pain Medicine, National Trauma Centre, Nepal

⁴Associate Professor, Department of Colorectal Surgery, Bangladesh Medical University, Dhaka, Bangladesh.

⁵Consultant, Department of Hepatobiliary Surgery, KIST Medical College & Teaching Hospital, Lalitpur, Nepal

⁶Professor, Department of Colorectal Surgery, Bangladesh Medical University, Dhaka, Bangladesh

⁷Higher Speciality Trainee Surgeon, Department of Pancrease Surgery, Leeds Teaching Hospitals NHS Trust, UK

⁸House officer, National Academy of Medical Sciences, India.

DOI: <https://doi.org/10.36347/sajs.2026.v12i03.004>

| Received: 22.01.2026 | Accepted: 07.03.2026 | Published: 12.03.2026

*Corresponding author: Dr. Rakesh Sah

Consultant, Department of Colorectal Surgery, Everest Hospital, Kathmandu, Nepal

Abstract

Original Research Article

Background: Pilonidal sinus disease is a common and debilitating condition that predominantly affects young adults, especially males, and is characterized by chronic inflammation of the natal cleft with a tendency for recurrence and significant morbidity despite various surgical treatment options. The purpose of the study is to evaluate the perioperative course and early postoperative outcomes of patients undergoing Limberg flap surgery for pilonidal sinus. **Methods:** This prospective observational study at the Department of Colorectal Surgery, Bangabandhu Sheikh Mujib Medical University, Dhaka, Bangladesh (July 2019–August 2020) included 18 adult patients with primary pilonidal sinus who underwent Limberg flap repair, with perioperative outcomes, complications, and recovery assessed at follow-up, and data analyzed using SPSS® 24 under ethical approval and patient consent. **Results:** Among 18 patients undergoing Limberg flap surgery for pilonidal sinus, the mean age was 26.9 ± 5.2 years, with 88.9% male. Mean operative time was 88.8 ± 12.7 minutes, hospital stay 4.17 ± 0.7 days, and return to work 12.7 ± 1.8 days. Postoperative complications occurred in 5 patients (27.7%), mainly seroma and tip necrosis, with no recurrences up to 9 months; overweight strongly correlated with complications ($r = 0.93$, $p < 0.001$). **Conclusion:** Limberg flap surgery for pilonidal sinus is safe and effective, allowing early recovery with low complication rates, though overweight patients have higher risk of postoperative complications.

Keywords: Pilonidal Sinus, Limberg Flap, Postoperative Outcomes.

Copyright © 2026 The Author(s): This is an open-access article distributed under the terms of the Creative Commons Attribution 4.0 International License (CC BY-NC 4.0) which permits unrestricted use, distribution, and reproduction in any medium for non-commercial use provided the original author and source are credited.

INTRODUCTION

Pilonidal sinus disease is a frequently encountered and disabling condition, with an annual incidence of 26 cases per 100,000 individuals [1]. The disease predominantly affects young, hirsute males. Pilonidal sinus (PS) typically occurs in the natal cleft of the sacrococcygeal region, where weak hairs accumulate in the hair follicles, leading to a chronic condition that may occasionally exacerbate acutely [2-3]. PS is recognized as a chronic, acquired disorder of the skin and subcutaneous tissue in the natal cleft. It primarily affects adults in their second and third decades of life, with decreasing frequency after 25 years and becoming uncommon beyond 45 years [4].

The prevalence in men is approximately two to three times higher than in women [5-6]. The condition's overall incidence is estimated at 26 per 100,000 people. Predisposing factors include obesity, local trauma, chronic irritation, and a sedentary lifestyle [7]. Young men are the most commonly affected population, and although PS is generally benign, its high incidence and chronicity contribute to significant clinical relevance [8-9]. These same risk factors—obesity, trauma, local irritation, and sedentary habits—are frequently associated with the development of pilonidal sinus disease (PSD) [7].

The accumulated hair induces a localized inflammatory response, leading to the formation of

Citation: Rakesh Sah, Chowdhury Sazzad Hyder, Deepak Kumar Yadav, Muhammad Ali Siddiquee, Akanand Singh, Md. Shahadat Hussain. Perioperative and Early Postoperative Outcomes Following Limberg Flap Surgery for Pilonidal Sinus. SAS J Surg, 2026 Mar 12(3): 197-203.

chronic draining sinuses and tracts and often resulting in secondary infection or abscess formation [10]. While a subset of patients may not experience recurrence after initial conservative management, many develop recurrent disease, characterized by persistent sinus formation and abscesses, causing notable pain, distress, and functional impairment [10]. Pilonidal sinus has substantial morbidity, particularly as it affects individuals during their most productive years, imposing significant socioeconomic burdens [11].

Management strategies for pilonidal sinus include various surgical options such as incision and drainage, laying open of the sinus tract, excision with healing by secondary intention, primary closure after excision, and excision with advancement or transposition flap closure. Among these, transposition flaps like the Limberg flap are preferred to minimize tension at the wound site. Originally described by Alexander Limberg in 1948, the Limberg flap is a transposition flap designed to cover a rhomboid-shaped defect, with opposite sides of equal length, medial and lateral angles of 120°, and superior and inferior angles of 60° [12-13]. Multiple studies have demonstrated that rhomboid excision followed by closure with a Limberg transposition flap is the procedure of choice for chronic sacrococcygeal pilonidal sinus disease [14-16]. Compared to other surgical techniques, flap reconstruction is considered superior because it addresses the underlying cause of the disease by flattening the intergluteal sulcus [17].

Despite the availability of multiple surgical techniques for pilonidal sinus, including primary closure and healing by secondary intention, recurrence rates and postoperative complications remain significant challenges. Flap-based procedures, particularly the Limberg flap, have shown promise in reducing tension on the wound, flattening the natal cleft, and minimizing recurrence; however, data on perioperative and early postoperative outcomes in different patient populations remain limited. Evaluating these outcomes is essential to optimize surgical care, reduce morbidity, and guide clinical decision-making. The purpose of the study is to evaluate the perioperative course and early postoperative outcomes of patients undergoing Limberg flap surgery for pilonidal sinus.

Objective

- To evaluate the perioperative course and early postoperative outcomes of patients undergoing Limberg flap surgery for pilonidal sinus.

METHODOLOGY & MATERIALS

This prospective observational study was conducted at the Department of Colorectal Surgery, Bangabandhu Sheikh Mujib Medical University (BSMMU), Dhaka, Bangladesh, from July 2019 to August 2020. A total of 18 patients with primary pilonidal sinus were included, selected based on predefined inclusion and exclusion criteria to evaluate the perioperative course and early postoperative outcomes following Limberg flap surgery.

Inclusion Criteria:

- Adult patients admitted for treatment of primary pilonidal sinus.

Exclusion Criteria:

- Patients with acute pilonidal abscess.
- Patients with recurrent pilonidal sinus.

The study assessed age and sex as demographic variables, and duration of operation, hospital stay, drain and suture removal, time to return to work, postoperative complications, and recurrence as outcome variables. Eligible patients provided written informed consent, and baseline demographics, clinical history, and relevant investigations were recorded using a predesigned data collection sheet. Follow-up assessments were conducted at 2 weeks, 1 month, 3 months, 6 months, and 9 months to document complications and functional recovery.

All patients underwent Limberg flap repair under spinal anesthesia in the prone jackknife position. Preoperative prophylaxis included a single intravenous dose of cefuroxime. The sacrococcygeal area was shaved and disinfected, and the sinus tracts were visualized using methylene blue prior to rhomboid excision. The flap was mobilized from the gluteus maximus to prevent tension, hemostasis was achieved with electrocautery, a suction drain was placed, subcutaneous tissue was closed with 2/0 polyglycolic acid sutures, and the skin was closed with interrupted 2/0 polypropylene sutures.

Data were analyzed using SPSS® version 24, with continuous variables presented as mean ± standard deviation and range, categorical variables as frequency and percentage, and correlation analyses performed where applicable. The study was approved by the Institutional Review Board of BSMMU, and patient confidentiality and the right to withdraw at any time were ensured.

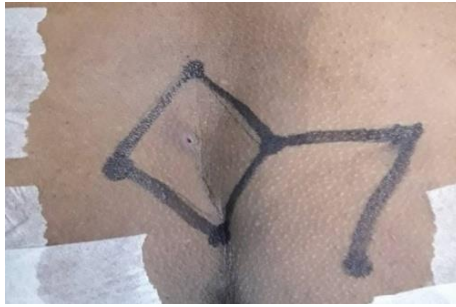

Figure 1: Rhomboid Marking Including Pilonidal Sinus and Planned Flap Extent Prior to Excision.

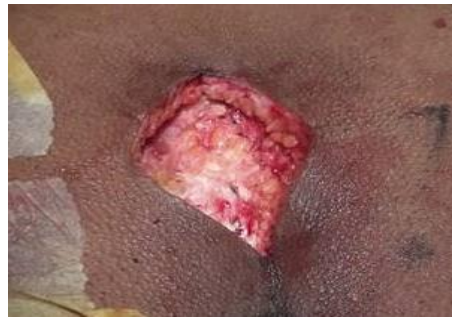

Figure 2: Excision of the Rhomboid Down to the Post-Sacral Fascia, Showing Intraoperative Exposure of the Defect.

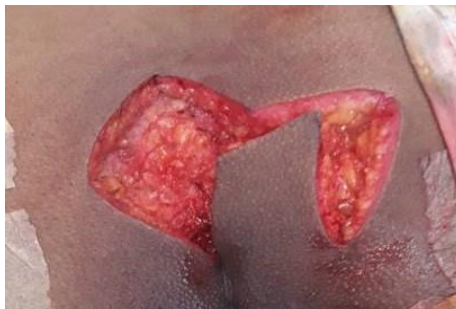

Figure 3: Preparation of a Right Gluteal Fascio-Cutaneous Limberg Flap Ready for Transposition.

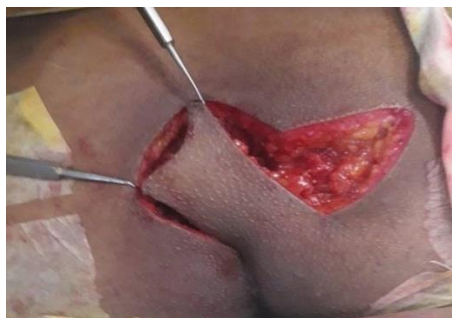

Figure 4: Flap Rotated on to the Defect to Achieve Tension-Free Closure.

RESULTS

Table 1: Age Distribution of the Study Participants (n = 18)

Age (years)	n	%
≤ 29	12	66.7
30–49	6	33.3
> 50	0	0.0
Mean ± SD (Min–Max)	26.9 ± 5.2 (16–35)	

Two-thirds of the patients were aged ≤29 years (12 patients, 66.7%), while 6 patients (33.3%) were aged between 30 and 49 years. No patient was older than 50

years. The mean age at presentation was 26.9 ± 5.2 years, ranging from 16 to 35 years.

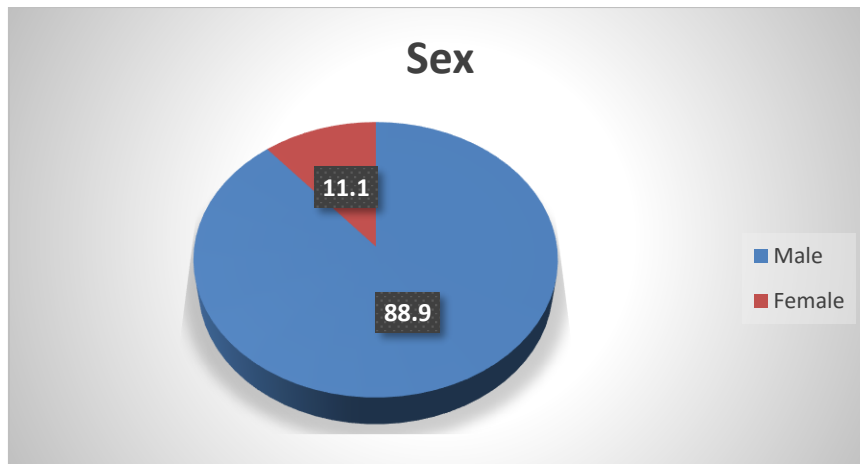


Figure 5: Sex Distribution of the Study Participants (n = 18)

Male patients predominated, accounting for 16 patients (88.9%), while only 2 patients (11.1%) were female.

Table 2: Perioperative and Early Postoperative Outcomes Following Limberg Flap Surgery (n = 18)

Variable		Number of Patients (N)	Percentage (%)
Duration of Operation (minutes)	70	2	11.1
	80	6	33.3
	90	5	27.8
	100	2	11.1
	110	3	16.7
	Mean ± SD	88.8 ± 12.7	
	Range (Min–Max)	70–110	
Duration of Hospital Stay (days)	3	3	16.7
	4	10	55.6
	5	4	22.2
	6	1	5.6
	Mean ± SD	4.17 ± 0.7	
	Range (Min–Max)	3–6	
Day of Drain Removal	3rd	12	66.7
	4th	4	22.2
	5th	2	11.1
	Mean ± SD	3.4 ± 0.7	
Day of Suture Removal	10	1	5.55
	12	10	55.5
	13	2	11.1
	14	1	5.55
	15	1	5.55
	16	3	16.7
	Mean ± SD	12.9 ± 1.7	
	Range (Min–Max)	10–16	
Time to Return to Work (days)	10	3	16.7
	11	1	5.55
	12	5	27.8
	13	2	11.1
	14	4	22.2
	15	2	11.1
	16	1	5.55
	Mean ± SD	12.7 ± 1.8	
	Range (Min–Max)	10–16	

The mean duration of operation was 88.8 ± 12.7 minutes (range 70–110 minutes), with most procedures

lasting 80 minutes (6 patients, 33.3%) or 90 minutes (5 patients, 27.8%). Postoperatively, the mean hospital stay

was 4.17 ± 0.7 days (range 3–6 days), with the majority of patients discharged on day 4 (10 patients, 55.6%). Drain removal occurred most commonly on the third postoperative day (12 patients, 66.7%), with a mean of 3.4 ± 0.7 days. Suture removal was most frequently performed on day 12 (10 patients, 55.6%), with a mean

of 12.9 ± 1.7 days (range 10–16 days). Patients returned to work between 10 and 16 days postoperatively, most commonly on day 12 (5 patients, 27.8%) and day 14 (4 patients, 22.2%), with a mean time to return to work of 12.7 ± 1.8 days.

Table 3: Postoperative Complications During Follow-Up (n = 18)

Complication Type	n	%
Seroma	2	11.1
Tip necrosis	3	16.7
Wound dehiscence	1	5.6
No complication	13	72.3
Overall complication rate	5	27.7
Recurrence (up to 9 months)	0	0.0

Seroma was observed in 2 (11.1%) patients and tip necrosis in 3 (16.7%) patients at the second week of follow-up. One of the patients with tip necrosis subsequently developed wound dehiscence at one month. No complications were observed at the third, sixth, or

ninth month follow-up visits. Overall, 5 (27.7%) patients developed postoperative complications, while 13 (72.3%) remained free of complications throughout the study period. No recurrence was noted up to 9 months.

Table 4: Correlation Between Overweight and Postoperative Complications

Variable	Complication (n)	No Complication (n)	Pearson's r	p-value
Overweight (N = 5)	4	1	0.93	<0.001

Among the 5 overweight patients, 4 developed postoperative complications and 1 remained complication-free. A strong positive correlation was observed between overweight status and postoperative complications ($r = 0.93$, $p < 0.001$).

DISCUSSION

Pilonidal sinus is a common sacrococcygeal condition causing significant morbidity if not properly managed. Limberg flap surgery aims for tension-free closure and low recurrence. This study shows that Limberg flap repair results in favorable perioperative and early postoperative outcomes, including short hospital stay, early return to work, and low complication rates, highlighting its effectiveness in managing primary pilonidal sinus.

The age distribution observed in the present study demonstrates that pilonidal sinus predominantly affects young adults, with two-thirds of patients (66.7%) aged ≤ 29 years and a mean age of 26.9 ± 5.2 years (range 16–35). No patient was older than 50 years, further reinforcing the tendency of this condition to occur in the younger population. These findings align with Devaprashanth *et al.* [18], who reported a mean age of 29.83 ± 4.99 years in patients undergoing Limberg flap repair, highlighting a predominance of young adults. Similarly, Karapolat *et al.* [19] observed a mean age of 27.5 ± 7.8 years among patients treated with the Limberg flap, and Khanna *et al.* [20] reported a mean age of 24.2 years (range 15–65), emphasizing that pilonidal sinus disease primarily affects adolescents and young adults. The concordance of these findings supports the well-

established understanding that pilonidal sinus is largely a disease of the young, likely attributable to hormonal influences, increased hair growth, and prolonged sitting habits common in this age group.

The present study also demonstrated a marked male predominance, with 16 out of 18 patients (88.9%) being male and only 2 patients (11.1%) female. This finding is consistent with the established epidemiology of pilonidal sinus. Luedi *et al.* [21], in a meta-analysis including 104,055 patients across 679 studies, reported that approximately 80% of affected individuals were male, confirming a consistent global male predominance. Similarly, Deo *et al.* [22] found that 86.7% of patients undergoing pilonidal sinus surgery were male, a proportion very similar to our cohort. These similarities reinforce the understanding that pilonidal sinus disease predominantly affects males, possibly due to factors such as increased body hair, deeper natal cleft anatomy, hormonal influences, and occupational or lifestyle factors involving prolonged sitting.

The perioperative and early postoperative outcomes in the current study further support the effectiveness of the Limberg flap procedure. The mean hospital stay was 4.17 ± 0.7 days, and patients returned to work at a mean of 12.7 ± 1.8 days, reflecting early recovery and satisfactory postoperative progress. Comparable results were reported by Topgöl *et al.* [23], who documented a mean hospital stay of 3.1 days and mean return-to-work time of 12.8 days following Limberg flap repair, closely paralleling our findings. Similarly, Ali *et al.* [11] reported return to work at a mean of 19.6 days postoperatively, still indicating

recovery within 2–3 weeks, supporting early functional restoration. Additionally, Akhunzada *et al.* [24] highlighted that the Limberg flap is associated with shorter hospital stay, minimal postoperative morbidity, and rapid return to daily activities, echoing the operative duration, timely drain and suture removal, and favorable convalescence observed in our cohort. These consistencies reinforce the reliability and practical advantages of the Limberg flap in achieving efficient perioperative outcomes with expedited patient recovery.

The postoperative complication profile observed in this study demonstrates that the Limberg flap procedure is associated with a relatively low rate of early morbidity. Seroma developed in 2 patients (11.1%), tip necrosis in 3 patients (16.7%), and wound dehiscence in 1 patient (5.6%), while 13 patients (72.3%) experienced no complications, and no recurrences were noted up to 9 months. These findings are comparable to Zubair *et al.* [25], who reported seroma in 2 of 46 patients (4.3%), with the majority (76%) remaining complication-free and only 1 recurrence (2.1%) over a 12-month follow-up. Similarly, Pn *et al.* [26] observed seroma in 8 patients and flap necrosis in 5 patients, along with a few cases of wound dehiscence, representing typical early postoperative complications. The alignment of our results with these studies reinforces the conclusion that the Limberg flap offers reliable early postoperative outcomes with low recurrence and acceptable rates of minor complications.

Finally, the study demonstrated a strong positive correlation between overweight status and postoperative complications, with 4 of the 5 overweight patients (80%) experiencing complications compared to only 1 patient remaining complication-free ($r = 0.93$, $p < 0.001$). These results are consistent with Arda *et al.* [27], who observed that overweight or obese adolescents had significantly higher rates of postoperative complications, whereas patients with normal weight experienced few or no adverse events. This concordance emphasizes that elevated BMI is an important risk factor for early postoperative morbidity in pilonidal sinus surgery, underscoring the need for careful perioperative management and patient counseling in overweight individuals.

Limitations of the study

The study had several limitations:

- The present study included a small sample size.
- It was conducted at a single center.
- The study had a short duration and limited follow-up period.

CONCLUSION

Pilonidal sinus predominantly affects young adults and shows a strong male predominance. Limberg flap surgery in this study proved to be safe and effective, with short operative time, brief hospital stay, early return

to work, and a low rate of early postoperative complications. Overweight patients were more likely to experience complications, highlighting the importance of risk stratification and careful perioperative management.

REFERENCES

1. FF F. Ferri's Clinical Advisor 2019 E-Book: 5 Books in 1.
2. Søndena K, Andersen E, Nesvik I, Søreide JA. Patient characteristics and symptoms in chronic pilonidal sinus disease. *International journal of colorectal disease*. 1995 Feb;10(1):39-42.
3. Petersen S, Aumann G, Kramer A, Doll D, Sailer M, Hellmich G. Short-term results of Karydakias flap for pilonidal sinus disease. *Techniques in coloproctology*. 2007 Sep;11(3):235-40.
4. Bascom J. Pilonidal disease: origin from follicles of hairs and results of follicle removal as treatment. *Surgery*. 1980 May 1;87(5):567-72.
5. Burney RE. Treatment of pilonidal disease by minimal surgical excision under local anesthesia with healing by secondary intention: results in over 500 patients. *Surgery*. 2018 Dec 1;164(6):1217-22.
6. Akinci ÖF, Bozer M, Uzunköy A, Düzgün ŞA, Coşkun A. Incidence and aetiological factors in pilonidal sinus among Turkish soldiers. *The European journal of surgery*. 1999 Jan 1;165(4):339-42.
7. Kosaka M, Kida M, Mori H, Kamiishi H. Pilonidal cyst of the scalp due to single minor trauma. *Dermatologic surgery*. 2007 Apr 1;33(4):505-7.
8. Akinci OF, Kurt M, Terzi A, Atak I, Subasi IE, Akbilgic O. Natal cleft deeper in patients with pilonidal sinus: implications for choice of surgical procedure. *Diseases of the colon & rectum*. 2009 May 1;52(5):1000-2.
9. McCallum IJ, King PM, Bruce J. Healing by primary closure versus open healing after surgery for pilonidal sinus: systematic review and meta-analysis. *Bmj*. 2008 Apr 17;336(7649):868-71.
10. Sinnott CJ, Glickman LT. Limberg flap reconstruction for sacrococcygeal pilonidal sinus disease with and without acute abscess: our experience and a review of the literature. *Archives of Plastic Surgery*. 2019 May;46(03):235-40.
11. Ali MA, Kumar S, Verma A, Aishwarya A. Limberg Flap Procedure for Pilonidal Sinus: Retrospective Study from A Tertiary Care Centre. *Formosan Journal of Surgery*. 2024 Oct 10:10-97.
12. AA L. Modern trends in plastic surgery: Design of local flaps. *Modern Trend Plast Surg*. 1966; 2:38-61.
13. Limberg AA. *Mathematical principles of local plastic procedures on the surface of the human body*. Leningrad: Medgis. 1946.
14. Ertan T, Koc M, Gocmen E, Aslar AK, Keskek M, Kilic M. Does technique alter quality of life after pilonidal sinus surgery?. *The American journal of surgery*. 2005 Sep 1;190(3):388-92.

15. Arslan K, Said Kokcam S, Koksall H, Turan E, Atay A, Dogru O. Which flap method should be preferred for the treatment of pilonidal sinus? A prospective randomized study. *Techniques in coloproctology*. 2014 Jan;18(1):29-37.
16. Abu Galala KH, Salam IM, Abu Samaan KR, El Ashaal YI, Chandran VP, Sabastian M, Sim AJ. Treatment of pilonidal sinus by primary closure with a transposed rhomboid flap compared with deep suturing: a prospective randomised clinical trial. *The European journal of surgery*. 1999 Jan 1;165(5):468-72.
17. Khatri VP, Espinosa MH, Amin AK. Management of recurrent pilonidal sinus by simple VY fasciocutaneous flap. *Diseases of the colon & rectum*. 1994 Dec 1;37(12):1232-5.
18. Devaprashanth M. *Limberg Flap Versus Primary Closure in the Treatment of Pilonidal Sinus; A Randomized Clinical Study* (Master's thesis, Rajiv Gandhi University of Health Sciences (India)).
19. Karapolat B, Büyükakıncak S, Kurnaz E, Küçükütülü Ü. Comparison of limberg flap and oval flap techniques in sacrococcygeal pilonidal sinus disease surgery. *Turkish journal of surgery*. 2018 Aug 28;34(4):311.
20. Khanna AK, Tiwary SK. Pilonidal sinus disease with especial reference to Limberg flap. *Apollo Medicine*. 2015 Sep;12(3):163-9.
21. Luedi MM, Schober P, Stauffer VK, Diekmann M, Anderegg L, Doll D. Gender-specific prevalence of pilonidal sinus disease over time: A systematic review and meta-analysis. *ANZ J Surg*. 2021 Jul;91(7-8):1582-1587.
22. Deo KK, Yogi P, Dawadi P, Bista S, Chand J, GC S, Acharya J. Patients Undergoing Surgery for Pilonidal Sinus in the Department of Surgery in a Tertiary Care Centre: A Descriptive Cross-sectional Study. *Post-Graduate Medical Journal of NAMS*. 2025 Jul 15;25(2):71-3.
23. Topgül K, Ozdemir E, Kiliç K, Gökbayir H, Ferahköşe Z. Long-term results of limberg flap procedure for treatment of pilonidal sinus: a report of 200 cases. *Dis Colon Rectum*. 2003 Nov;46(11):1545-8.
24. Akhunzada TS, Khan MA, Rehman MU, ul Muqim R, Zarin M. OUTCOME OF LIMBERG'S PROCEDURE FOR PILONIDAL DISEASE. *Journal of Medical Sciences*. 2015 Dec 11;23(4):224-7.
25. Zubair R, Channa MA. Limberg flap technique for pilonidal sinus disease treatment: an experience of Hamdard University Hospital. *Journal of Ayub Medical College Abbottabad*. 2022 Mar 3;34(2):230-4.
26. Pn V, Vp K. Limberg Flap Procedure for Sacrococcygeal Pilonidal Sinus Disease. *Asian Journal of Research in Surgery*. 2025 May 26;8(1):198-203.
27. Arda IS, Güney LH, Sevmiş S, Hiçsönmez A. High body mass index as a possible risk factor for pilonidal sinus disease in adolescents. *World J Surg*. 2005 Apr;29(4):469-71.