

Total White Cataract: Surgical Strategy Based on Risk Stratification for Optimal Outcomes

Salma Bennis^{1*}, A. Jeribi¹, C. Begnoug¹, Fatema El Ibrahimy¹, Louaï Serghini¹, El Hassan Abdallah¹

¹Department of Ophthalmology B, Specialties Hospital, CHU Ibn Sina, Mohammed V University, Rabat, Morocco

DOI: <https://doi.org/10.36347/sjams.2026.v14i04.028>

| Received: 23.02.2026 | Accepted: 14.04.2026 | Published: 25.04.2026

*Corresponding author: Salma Bennis

Department of Ophthalmology B, Specialties Hospital, CHU Ibn Sina, Mohammed V University, Rabat, Morocco

Abstract

Review Article

Total white cataracts represent a major surgical challenge due to increased intralenticular pressure, absence of red reflex, and high risk of capsular complications. Successful management requires careful preoperative preparation and adapted surgical techniques. This review proposes a structured surgical strategy based on risk stratification, including patient preparation, capsulorhexis techniques, decompression methods, and intraoperative precautions. Particular emphasis is placed on preventing capsular rupture and optimizing surgical safety. By combining proper anticipation and technique adaptation, excellent outcomes can be achieved even in high-risk cases.

Keywords: White cataract, capsulorhexis, phacoemulsification, surgical strategy, capsular risk.

Copyright © 2026 The Author(s): This is an open-access article distributed under the terms of the Creative Commons Attribution 4.0 International License (CC BY-NC 4.0) which permits unrestricted use, distribution, and reproduction in any medium for non-commercial use provided the original author and source are credited.

INTRODUCTION

Total white (intumescent) cataracts represent a major surgical challenge due to increased intralenticular pressure, absence of red reflex, and fragility of the capsular and zonular structures. These factors expose the surgeon to a high risk of uncontrolled capsulorhexis and capsular rupture, particularly during the initial steps of surgery.

A structured approach based on preoperative assessment and intraoperative adaptation is therefore essential. In this context, anterior segment OCT allows a better understanding of lens morphology and enables classification into different types, each corresponding to a specific surgical strategy.

Type I Cataracts: Low-Risk Profile

Type I cataracts are characterized by preserved lamellar cortical fibers without anterior capsular convexity, reflecting low intralenticular pressure.

From a surgical perspective, these cataracts behave in a relatively predictable manner. A standard continuous curvilinear capsulorhexis (CCC) can be safely performed. The anterior chamber should be stabilized using viscoelastic, and capsular staining with trypan blue remains recommended to enhance visualization.

Phacoemulsification can then be carried out using conventional parameters. The absence of

significant pressure minimizes the risk of capsular tear, allowing a routine surgical course.

Type II Cataracts: High-Pressure, High-Risk Profile

Type II cataracts present with anterior capsular convexity and intralenticular fissures, indicating markedly increased intralenticular pressure. These cases carry the highest risk of uncontrolled capsulorhexis and the occurrence of the Argentine flag sign.

In these situations, the key principle is controlled decompression before completing capsulorhexis. A small initial capsulorhexis (mini-rhexis) should be performed under high-viscosity viscoelastic to counteract capsular tension.

Subsequently, gentle aspiration of liquefied cortex using a needle or irrigation–aspiration system allows reduction of intralenticular pressure. Only after adequate decompression should the capsulorhexis be enlarged in a controlled manner.

Hydrodissection must be avoided or performed with extreme caution, as it may abruptly increase intracapsular pressure and lead to rupture.

Type III Cataracts: Partially Decompressed Cataracts

Type III cataracts are characterized by extensive cortical liquefaction with partial spontaneous fluid release. Although intralenticular pressure remains elevated, it is often less abrupt compared to Type II.

The recommended approach is initial aspiration of liquefied cortex prior to capsulorhexis. This step reduces residual pressure and stabilizes the capsular environment.

Capsulorhexis can then be performed more safely, although careful control remains necessary. Viscoelastic support is essential to maintain anterior chamber stability.

Surgical manipulation should remain gentle, as capsular behavior can still be unpredictable.

Type IV Cataracts: Unpredictable and Complex Cases

Type IV cataracts exhibit homogeneous liquefaction with loss of normal lens architecture and often a thin, fragile capsule. Intralenticular pressure is variable and intraoperative behavior is highly unpredictable.

These cases require a cautious and staged approach. Controlled decompression is essential and should be performed gradually to avoid sudden capsular collapse or tearing.

A two-step capsulorhexis technique is strongly recommended. A small initial capsulorhexis is created, followed by decompression and subsequent enlargement once the capsular bag is stabilized.

High-viscosity viscoelastic devices are crucial to maintain anterior chamber depth and protect the capsule. Particular attention should be paid to zonular integrity, as weakness is frequently associated.

Phacoemulsification should be performed using low vacuum and low flow settings, with gentle and

centered maneuvers to minimize stress on the capsular bag.

General Surgical Principles

Regardless of the cataract type, several key principles apply to all intumescent cataracts.

Adequate preoperative preparation is essential, including optimal pupillary dilation and, in selected cases, the use of intravenous mannitol to reduce intraocular pressure. Any maneuver that may increase pressure should be avoided.

At the beginning of surgery, a watertight corneal incision and a stable anterior chamber are mandatory. Viscoelastic agents play a central role in counterbalancing capsular tension and maintaining intraoperative control.

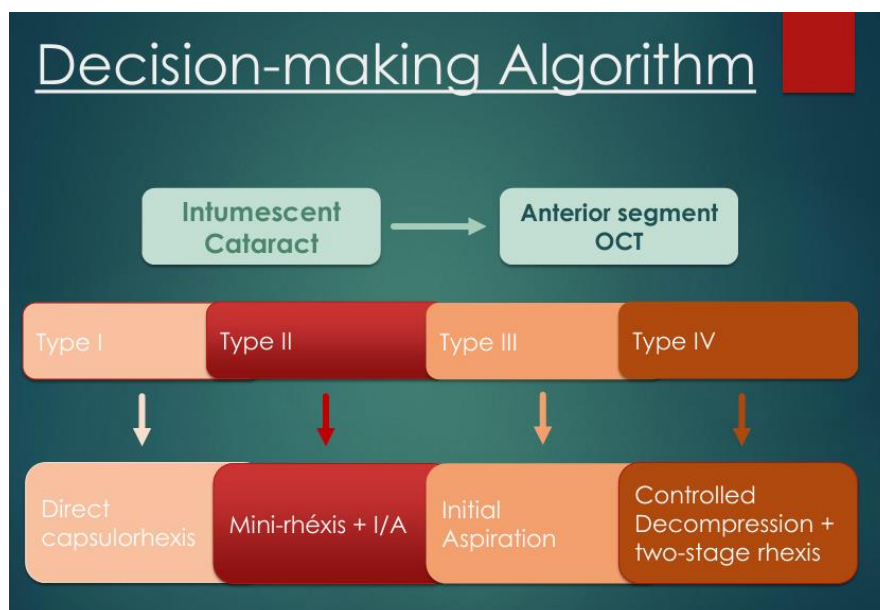
Capsular staining with trypan blue significantly improves visualization and enhances surgical safety.

Hydrodissection should be performed cautiously or avoided, especially in high-pressure cases.

Finally, all surgical steps must be performed with slow, controlled, and centered movements. Gentle handling of tissues is critical, particularly in the presence of fragile zonules and a weakened capsular bag.

Based on these morphological and surgical considerations, a decision-making algorithm can be proposed to guide the management of intumescent cataracts according to their AS-OCT classification.

Decision-Making Algorithm for Intumescent Cataract Surgery Based on Anterior Segment OCT



CONCLUSION

Total white cataracts require a structured and adapted surgical approach. Risk stratification, careful preparation, and appropriate intraoperative techniques are essential for minimizing complications. Anticipation and surgical precision transform a high-risk procedure into a controlled and successful intervention.

Acknowledgement

The authors would like to thank the medical and paramedical staff of the Department of Ophthalmology B, CHU Ibn Sina, Rabat, for their support in the clinical management of this patient.

REFERENCES

- Vajpayee, R. B., Bansal, A., Sharma, N., Dada, T., & Dada, V. K. (1999). Phacoemulsification of white hypermature cataract. *Journal of Cataract & Refractive Surgery*, 25(8), 1157-1160.
- Chakrabarti, A., Singh, S., & Krishnadas, R. (2000). Phacoemulsification in eyes with white cataract. *Journal of Cataract & Refractive Surgery*, 26(7), 1041-1047.
- Jacob, S., Agarwal, A., Agarwal, A., Agarwal, S., Chowdhary, S., Chowdhary, R., & Bagmar, A. A. (2002). Trypan blue as an adjunct for safe phacoemulsification in eyes with white cataract. *Journal of Cataract & Refractive Surgery*, 28(10), 1819-1825.
- Dada, V. K., Sharma, N., Sudan, R., Sethi, H., Dada, T., & Pangtey, M. S. (2004). Anterior capsule staining for capsulorhexis in cases of white cataract: Comparative clinical study. *Journal of Cataract & Refractive Surgery*, 30(2), 326-333.
- Figueiredo, C. G., Figueiredo, J., & Figueiredo, G. B. (2012). Brazilian technique for prevention of the Argentinean flag sign in white cataract. *Journal of Cataract & Refractive Surgery*, 38(9), 1531-1536.
- Dhingra, D., Balyan, M., Malhotra, C., Rohilla, V., & Jain, A. K. (2018). A multipronged approach to prevent Argentinian flag sign in intumescent cataracts. *Indian Journal of Ophthalmology*, 66(9), 1304-1306.
- Porwal, A. C., Singh, S., Raje, D., & Sharma, N. (2021). Role of preoperative Nd:YAG laser anterior capsulotomy in mature intumescent cataracts. *Asia-Pacific Journal of Ophthalmology*, 10(5), 473-477.
- Antunes, V. A. C., de Pádua Soares Bezerra, B., de Moraes, C. G., & collaborators. (2024). Automated capsular decompression to avoid Argentinian flag sign in intumescent cataract surgery. *Clinical Ophthalmology*, 18, 1841-1849.
- Venkatesh, R., Tan, C. S. H., Singh, G. P., Veena, K., Krishnan, K. T., Ravindran, R. D., & Chang, D. F. (2010). Phacoemulsification versus manual small-incision cataract surgery for white cataract. *Journal of Cataract & Refractive Surgery*, 36(11), 1849-1854.