SAS Journal of Medicine
Abbreviated Key Title: SAS J Med
ISSN 2454-5112
Journal homepage: https://saspublishers.com

OPEN ACCESS

Radiation Oncology

Management of Oropharyngeal Cancer: Experience of the Department of Radiation Oncology, Mohammed VI University Hospital, Marrakech

Houria Ezzamane[1]*, Kaoutar Khayioui[1], Tariq Igarramen[1], Sana Laatitioui[1], Mohamed Saadoune[1], Nezha Oumghar[1], Samire Barkiche[1], Mouna Darfaoui[1], Abdelhamid El Omrani[1], Mouna El Khouchani[1]

[1]Radiation Oncology Department, Oncology and Haematology Hospital, Mohammed VI University Hospital, Marrakech, Morocco

DOI: https://doi.org/10.36347/sasjm.2026.v12i11.023 | **Received:** 22.09.2026 | **Accepted:** 20.11.2026 | **Published:** 23.11.2026

***Corresponding author:** Houria Ezzamane
Radiation Oncology Department, Oncology and Haematology Hospital, Mohammed VI University Hospital, Marrakech, Morocco

Abstract | **Original Research Article**

Radiotherapy is central to the management of oropharyngeal cancer, whether delivered alone, with concurrent cisplatin or after surgery, yet Moroccan data remain scarce. We aimed to describe the therapeutic strategy, irradiation modalities, toxicity and outcomes in our department. This retrospective, descriptive, single-centre study included all patients with histologically confirmed oropharyngeal carcinoma managed at the Department of Radiation Oncology, Mohammed VI University Hospital, Marrakech, between January 2017 and December 2024. Tumours were staged according to the eighth edition of the TNM classification. Fifty-two patients were included. Mean age was 62.4 years, the male-to-female ratio was 2.25 and 73.1% of patients were smokers. All tumours were squamous cell carcinomas, arising from the tonsil in 46.2% of cases. Half of the tumours were T3 or T4a, 57.7% of patients had N2 disease and 11.5% had distant metastases at diagnosis. Twenty-three patients (44.2%) were deemed unsuitable for surgery. Thirty-nine patients (75%) received three-dimensional conformal radiotherapy, 70 Gy in 35 fractions to the high-risk volume: adjuvant radiotherapy in 22, concurrent cisplatin-based chemoradiotherapy in 12 and radiotherapy alone in 5. Mean overall treatment time was 61 days. Acute radiation dermatitis occurred in 38.5% of irradiated patients and late xerostomia in 15.4%. After a median follow-up of 53 months, the objective response rate was 69.2% (95% confidence interval 54.9 to 81.3), including 30.8% complete responses, and the disease control rate was 84.6% (95% confidence interval 71.9 to 93.1). In our setting, oropharyngeal cancer is diagnosed at a locally advanced stage and radiotherapy is part of treatment in three out of four patients. Access to intensity-modulated radiotherapy, adherence to the planned overall treatment time, wider use of concurrent chemotherapy in eligible patients and systematic p16 testing are the main areas for improvement.

Keywords: Oropharyngeal cancer, squamous cell carcinoma, radiotherapy, three-dimensional conformal radiotherapy, concurrent chemoradiotherapy, cisplatin, human papillomavirus, Morocco.

Copyright © 2026 The Author(s): This is an open-access article distributed under the terms of the Creative Commons Attribution **4.0 International License (CC BY-NC 4.0)** which permits unrestricted use, distribution, and reproduction in any medium for non-commercial use provided the original author and source are credited.

INTRODUCTION

Oropharyngeal cancer accounts for about 106,000 new cases worldwide each year according to GLOBOCAN 2022 estimates [1]. Alongside the classical forms related to tobacco and alcohol, whose effects potentiate each other [2], high-income countries have seen a rise in forms induced by human papillomavirus [3]. The latter carry a better prognosis [4].

Radiotherapy plays a central role in management. Like surgery, it is a curative treatment for early stages. Combined with cisplatin, it is the standard of care for locally advanced disease. It also complements surgery when examination of the surgical specimen reveals risk factors for relapse [5, 6]. The survival benefit of concurrent chemotherapy is established [7], and intensity-modulated radiotherapy has become the reference technique because it spares the salivary glands [8].

The choice between these strategies depends on parameters that the radiation oncologist must weigh for each patient: stage, resectability, viral status, performance status, renal function and available equipment. In Morocco, few series describe this tumour site or how these parameters guide the decision.

The aim of this study was to describe the therapeutic strategy, irradiation modalities, toxicity and outcomes of oropharyngeal cancers managed at the

Department of Radiation Oncology of Mohammed VI University Hospital, Marrakech, and to identify areas for improvement.

MATERIALS AND METHODS

Study design and period.

This was a retrospective, descriptive, single-centre study conducted at the Department of Radiation Oncology of Mohammed VI University Hospital, Marrakech, over eight years, from 1 January 2017 to 31 December 2024.

Population.

All patients aged 18 years or older managed for histologically confirmed oropharyngeal cancer were included. Incomplete records, benign or secondary tumours and other sites of the upper aerodigestive tract were excluded.

Data collection.

Epidemiological, clinical, paraclinical, therapeutic and follow-up data were extracted from the department registers, medical records and multidisciplinary tumour board reports, using a predefined data collection form.

Work-up and staging.

All patients had a neck computed tomography scan, completed by magnetic resonance imaging of the head and neck and by a chest, abdomen and pelvis computed tomography scan depending on the clinical context. Human papillomavirus status was assessed by p16 immunohistochemistry when available. Tumours were staged according to the eighth edition of the American Joint Committee on Cancer TNM classification [9].

Treatment decision.

The strategy was decided at the multidisciplinary tumour board according to the stage, site and resectability of the tumour, performance status and comorbidities. A blood count, renal function tests and liver function tests were performed before any treatment.

Preparation for irradiation.

A dedicated consultation preceded treatment: smoking and alcohol cessation, dental assessment and restoration, custom fluoride trays and, in case of feeding difficulties, placement of a nasogastric tube or gastrostomy.

Simulation and contouring.

The planning computed tomography scan was acquired in the supine position with neck hyperextension, a thermoplastic mask, intravenous contrast and 2 to 3 mm slices from the vertex to the carina. The gross tumour volume included the primary tumour and involved nodes. The high-risk clinical target volume was the gross tumour volume plus a 5 mm margin, and the intermediate-risk volume a 10 mm margin, both cropped at anatomical barriers. The low-risk volume covered nodal levels II to V on both sides, and level Ib when level II was involved. Planning target volumes were obtained with an additional margin of 3 to 5 mm.

Dose, fractionation and technique.

All patients were treated with three-dimensional conformal radiotherapy on a linear accelerator. The high-risk volume received 70 Gy in 35 fractions of 2 Gy, the intermediate-risk volume 60 to 66 Gy and the low-risk volume 50 to 54 Gy, at five fractions per week, for a planned overall treatment time of seven weeks. Dose constraints to organs at risk are listed in Table 1.

Table 1: Dose constraints to organs at risk

Organ at risk	Constraint
Brainstem	Maximum dose 55 Gy
Spinal cord	Maximum dose 50 Gy
Optic nerve and chiasm	Maximum dose 54 Gy
Temporal lobes	Maximum dose 60 Gy
Parotid gland	Mean dose 30 to 33 Gy
Larynx	Mean dose 40 Gy
Thyroid	Mean dose 50 Gy
Mandible and temporomandibular joint	Maximum dose 70 Gy
Cochlea	Maximum dose 40 Gy
Eye	Mean dose 35 Gy
Lens	Maximum dose 10 Gy

Quality control and on-treatment review.

Patient positioning was verified by portal imaging during the first two fractions, then weekly and after any change to the plan. A weekly consultation allowed acute toxicities to be detected and treated.

Chemotherapy.

Concurrent chemotherapy was based on cisplatin, at 100 mg/m² every three weeks for two to three cycles or 40 mg/m² weekly for six to seven cycles. Induction chemotherapy combined docetaxel, cisplatin and 5-fluorouracil, or cisplatin and 5-fluorouracil, for

two to three cycles. In the palliative setting, patients received cisplatin and 5-fluorouracil, or docetaxel alone.

Follow-up.

Follow-up included clinical examination with flexible endoscopy every one to three months during the first year, every two to six months during the second year, then every four to eight months until the fifth year. Magnetic resonance imaging of the head and neck was performed every six months for two years, then yearly.

Statistical analysis.

Data were entered and analysed in Microsoft Excel. The analysis was descriptive: counts and percentages for qualitative variables, mean or median with range for quantitative variables. The 95% confidence intervals of response rates were calculated with the exact Clopper-Pearson method.

Ethical considerations. Patient anonymity and data confidentiality were respected at all stages of the study.

RESULTS

Population

Fifty-two patients were included, about six per year. Mean age was 62.4 years (range 35 to 95). There were 36 men and 16 women, a male-to-female ratio of 2.25. Twenty-two patients (42.3%) lived in rural areas and 34 (65.4%) had a low socioeconomic status.

Smoking was reported by 38 patients (73.1%), alcohol consumption by 16 (30.8%) and cannabis use by 4 (7.7%). Five patients (9.6%) had a history of prior malignancy, three of them of the upper aerodigestive tract.

Clinical presentation

The median time from first symptoms to the first specialist consultation was 6.7 months (range 10 days to 24 months). Presenting symptoms were dysphagia in 38 patients (73.1%), odynophagia in 32 (61.5%) and weight loss in 30 (57.7%). Examination revealed an ulceroproliferative lesion in 36 patients (69.2%), as illustrated in Figure 1.



Figure 1: Clinical appearance of a squamous cell carcinoma of the right tonsil

Pathology and staging work-up

Diagnosis was based on a biopsy in 42 patients (80.8%) and on a surgical specimen in 10 (19.2%). All tumours were squamous cell carcinomas. p16 overexpression was documented in two patients.

Neck computed tomography, performed in all patients, showed the primary tumour in 48 (92.3%) and cervical lymphadenopathy in 34 (65.4%), mainly at levels II and III. Magnetic resonance imaging, performed in 13 patients (25%), better defined the limits of the primary tumour in 10 of them and revealed two cases of bone involvement not seen on computed tomography (Figure 2). It was co-registered with the planning scan for contouring in these 13 patients. Chest, abdomen and pelvis computed tomography, performed in 40 patients (76.9%), showed lung or liver metastases in 6.

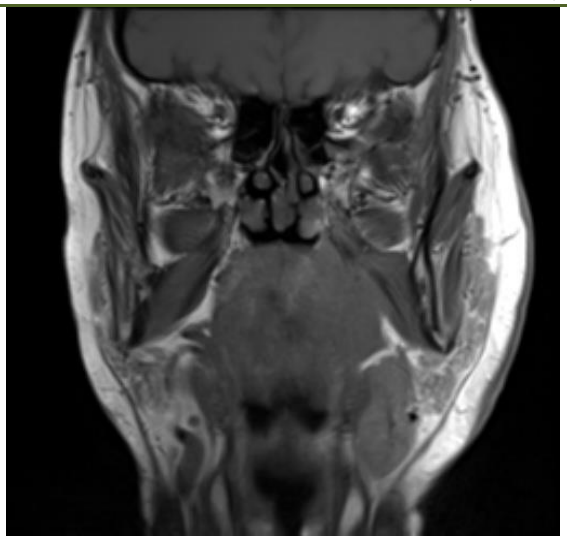

Figure 2: Coronal magnetic resonance image: large mass of the left palatine tonsil infiltrating the pillars and extending to the posterior oropharyngeal wall.

Half of the tumours were T3 or T4a and 30 patients (57.7%) had N2 disease. No patient had N3 disease. Tumour characteristics are detailed in Table 2.

Table 2: Tumour characteristics of the 52 patients

Characteristic	Number	Percentage
Site		
Tonsil	24	46.2%
Base of tongue	14	26.9%
Soft palate and uvula	8	15.4%
Posterior wall	6	11.5%
Differentiation		
Well differentiated	16	30.8%
Moderately differentiated	28	53.8%
Poorly differentiated	8	15.4%
Tumour size		
Less than 3 cm	18	34.6%
3 to 5 cm	24	46.2%
More than 5 cm	10	19.2%
T category		
T1	8	15.4%
T2	18	34.6%
T3	22	42.3%
T4a	4	7.7%
N category		
N0	18	34.6%
N1	4	7.7%
N2b	27	51.9%
N2c	3	5.8%
M category		
M0 on chest, abdomen and pelvis computed tomography	34	65.4%
M1	6	11.5%
Distant staging not performed	12	23.1%

Parameters guiding the treatment decision

Twenty-three patients (44.2%) were deemed unsuitable for surgery because of stage, tumour site or performance status. Six patients (11.5%) had renal impairment on the pre-treatment work-up, which limited the use of cisplatin. Table 3 lists the tumour-related and patient-related parameters that weigh on the choice between surgery, radiotherapy and chemotherapy.

Table 3: Parameters guiding the treatment decision in the 52 patients

Parameter	Number	Percentage	Consequence for the strategy
Tumour-related			
T3 or T4a tumour	26	50%	Function-preserving surgery difficult, combined treatment
N2b or N2c nodal disease	30	57.7%	Bilateral neck irradiation, concurrent chemotherapy
Muscle or soft tissue invasion on computed tomography	19	36.5%	Limited resectability, wider target volume margins
Bone involvement on computed tomography	4	7.7%	T4 tumour, major surgery or chemoradiotherapy
Trismus, mouth opening below 3 cm	10	19.2%	Transoral approach compromised
Distant metastases at diagnosis	6	11.5%	Palliative systemic treatment
Documented p16 overexpression	2	3.8%	More favourable prognosis, specific staging
On specimen or biopsy			
Lymphovascular invasion	10	19.2%	Argument for adjuvant radiotherapy
Perineural invasion	8	15.4%	Argument for adjuvant radiotherapy
Patient-related			
Renal impairment	6	11.5%	Contraindication to cisplatin
Anaemia	4	7.7%	Correction before irradiation
Abnormal liver function tests	2	3.8%	Chemotherapy adjustment
Hypertension	12	23.1%	Caution with cisplatin hydration
Diabetes	8	15.4%	Increased renal and infectious risk

Treatments received

Figure 3 summarises the strategy applied. Twenty-nine patients (55.8%) underwent surgery: partial pharyngectomy in 24 and transoral resection in 5, with neck dissection in 17. Twenty-two of them received adjuvant radiotherapy.

Among the 23 patients who did not undergo surgery, 12 received concurrent cisplatin-based chemoradiotherapy, 5 radiotherapies alone and 6 palliative chemotherapies. Induction chemotherapy was given to 8 patients.

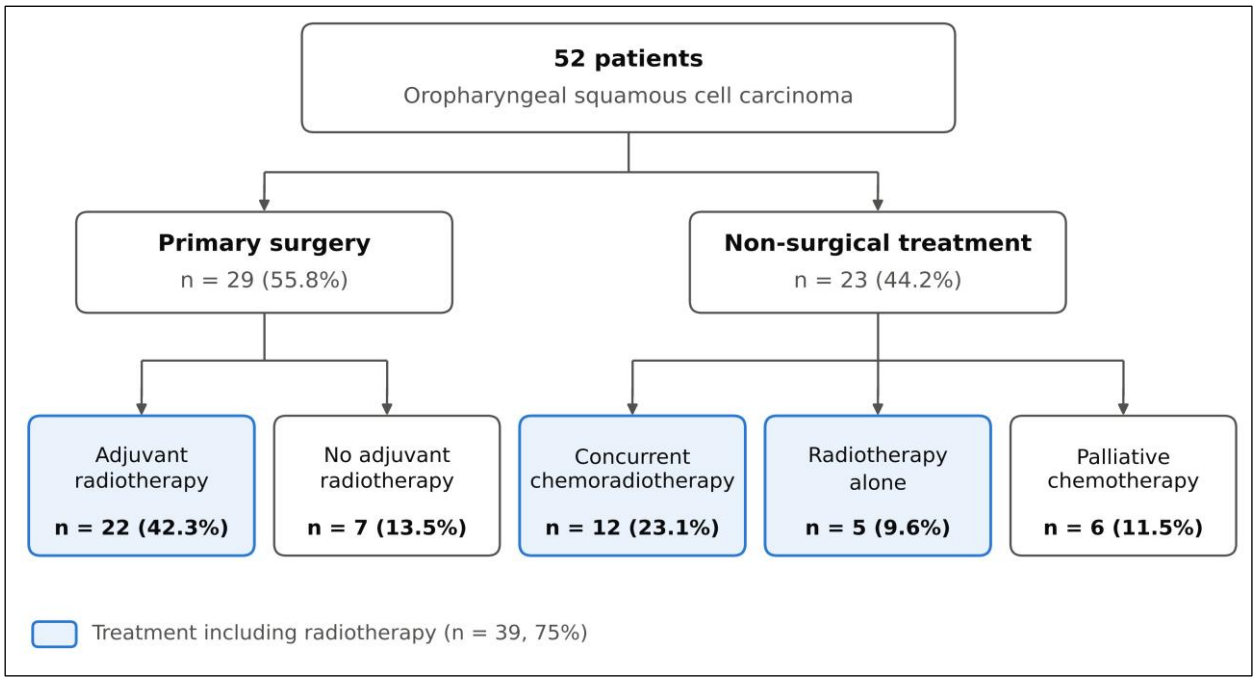

Figure 3: Therapeutic strategy applied to the 52 patients.

Overall, 39 patients (75%) were irradiated, all with three-dimensional conformal radiotherapy and the same fractionation. Figure 4 shows an example of contouring. Mean overall treatment time was 61 days (range 49 to 70), against 49 days planned. Interruptions were due to toxicities and machine downtime. Table 4 details the treatment modalities.



Figure 4: Axial and sagittal planning computed tomography images: gross tumour volume in red, high-risk clinical target volume in yellow, intermediate-risk clinical target volume in white.

Table 4: Treatment modalities

Treatment	Number	Percentage of the 52 patients
Surgery	29	55.8%
Partial pharyngectomy	24	46.2%
Transoral resection	5	9.6%
Neck dissection	17	32.7%
Radiotherapy	39	75%
Adjuvant	22	42.3%
Concurrent chemoradiotherapy	12	23.1%
Radiotherapy alone	5	9.6%
Co-registration with magnetic resonance imaging for contouring	13	25%
Chemotherapy	26	50%
Concurrent cisplatin	12	23.1%
Induction with docetaxel, cisplatin and 5-fluorouracil	3	5.8%
Induction with cisplatin and 5-fluorouracil	5	9.6%
Palliative cisplatin and 5-fluorouracil	4	7.7%
Palliative docetaxel	2	3.8%

Toxicity

Among the 39 irradiated patients, 15 (38.5%) developed acute radiation dermatitis, which never exceeded grade 2. Xerostomia was the most frequent late toxicity. Figure 5 details the toxicities of radiotherapy.

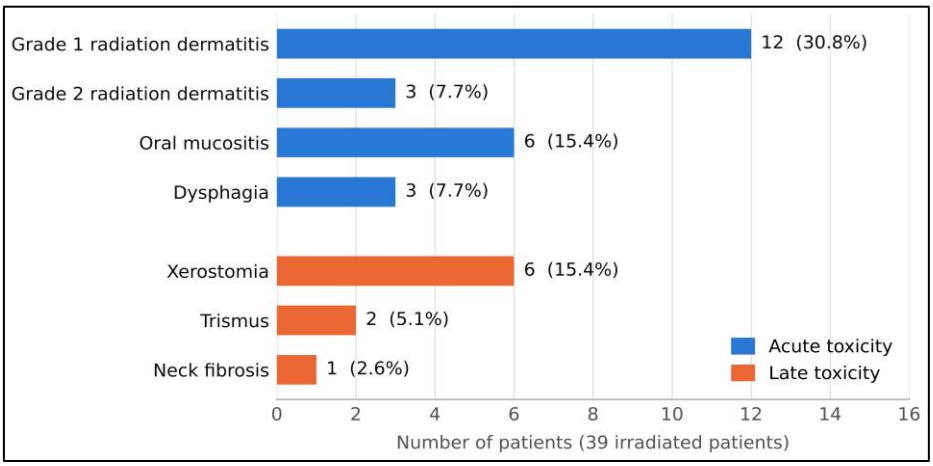

Figure 5: Acute and late toxicities of radiotherapy in the 39 irradiated patients.

Among the 26 patients who received chemotherapy, adverse events were fatigue in 18 (69.2%), haematological toxicity in 10 (38.5%), including 6 cases of neutropenia, alopecia in 9 (34.6%) and gastrointestinal toxicity in 8 (30.8%). Nephrotoxicity occurred in 3 patients (11.5%).

Treatment response

Median follow-up was 53 months (range 5 to 107). A complete response was obtained in 16 patients (30.8%) and a partial response in 20 (38.5%). Disease was stable in 8 patients (15.4%). Progression or relapse was observed in 8 patients (15.4%). The objective

response rate was therefore 69.2% (95% confidence interval 54.9 to 81.3). The disease control rate, combining responses and stable disease, was 84.6% (95% confidence interval 71.9 to 93.1).

DISCUSSION

In this series, radiotherapy was part of treatment in three out of four patients, most often after surgery, for locally advanced tumours in male smokers. Four issues directly concern the radiation oncologist: patient selection for each modality, the place of concurrent chemotherapy, the irradiation technique and the overall treatment time.

Epidemiological profile and stage at diagnosis

Smoking, present in 73.1% of patients, and the rarity of p16-positive tumours distinguish our series from those of high-income countries [3]. p16 status was not tested systematically, so the true proportion of HPV-related tumours remains unknown. This status changes both prognosis [4] and staging: the eighth edition provides two separate staging systems, the one for p16-positive tumours being based on the work of the ICON-S group [9, 10]. Systematic p16 immunohistochemistry is therefore needed to stage patients correctly.

The median consultation delay of 6.7 months explains the presentation observed. Half of the tumours were T3 or T4a and 57.7% of patients had N2 disease, situations that call for multimodal treatment [5].

Therapeutic strategy

For T1 or T2 tumours with no or limited nodal involvement, surgery and radiotherapy give equivalent oncological results, and the choice rests on the expected functional sequelae [5]. The aim is to cure with a single modality. Surgery is therefore worthwhile only if resection can be complete and the probability of adjuvant treatment is low.

In our series, 44.2% of patients were not candidates for surgery. The parameters in Table 3 explain this: soft tissue invasion in more than one third of patients, bone involvement, and trismus precluding a transoral approach. For these patients, concurrent chemoradiotherapy is the standard treatment [5, 6].

Conversely, 22 of the 29 operated patients received adjuvant radiotherapy. This high proportion means that most of them accumulated the morbidity of two treatments. Stricter surgical selection would direct some of them to upfront chemoradiotherapy.

Indications for postoperative radiotherapy

The EORTC 22931 and RTOG 9501 trials showed that adding cisplatin to postoperative radiotherapy improves locoregional control in high-risk patients [11, 12]. Their combined analysis identified the two factors that justify this combination: positive surgical margins and extranodal extension [13]. Other adverse features, namely T3 or T4 tumour, multiple nodal involvement, lymphovascular invasion and perineural invasion, call for adjuvant radiotherapy alone.

Our records documented lymphovascular invasion and perineural invasion, but not systematically margin status or extranodal extension. Both should appear in every pathology report, because they determine the indication for concurrent chemotherapy.

Timing also matters. In a randomised trial from the MD Anderson Cancer Center, the cumulative time from surgery to the end of irradiation significantly influenced locoregional control and survival in high-risk patients [14]. This interval was not collected in our study and deserves to be monitored as a quality indicator.

Concurrent chemotherapy: indications and contraindications

The MACH-NC meta-analysis reports an absolute overall survival gain of 6.5% at five years with concurrent chemotherapy [7], confirmed by its update, which also shows that this benefit decreases with age [15]. Only 12 of our patients received it, whereas 30 had N2 disease.

Several parameters limit the use of cisplatin. An expert consensus lists as contraindications a markedly impaired performance status, creatinine clearance below 50 mL/min, and pre-existing hearing loss or neuropathy [16]. In our series, 11.5% of patients had renal impairment before treatment, and age reached 95 years. These data explain part of the cases treated with radiotherapy alone.

The reference regimen remains cisplatin 100 mg/m² every three weeks. A weekly regimen of 30 mg/m² gave inferior locoregional control in a randomised trial [17]. The weekly 40 mg/m² regimen, used in some of our patients, is a common alternative when the high dose is poorly tolerated. Replacing cisplatin with cetuximab cannot be recommended in eligible patients: two randomised trials found it inferior in terms of survival in HPV-positive tumours [18, 19]. No de-escalation is therefore validated outside clinical trials.

Induction chemotherapy, given to 8 patients, is not a standard. When it is chosen, the combination of docetaxel, cisplatin and 5-fluorouracil is superior to cisplatin and 5-fluorouracil [20]. In the metastatic setting, pembrolizumab, alone or with chemotherapy, has become the first-line treatment [21], but its availability remains limited in our context.

Target volumes and irradiation technique

Our protocol systematically irradiates the nodal areas on both sides. For well-lateralised T1 or T2 tonsil tumours with no or limited nodal involvement, unilateral irradiation is possible: in the Princess Margaret Hospital

series, the contralateral neck failure rate was only 3.5% [22]. American guidelines endorse this option [6], and an international consensus specifies the selection of nodal levels to treat [23]. As the tonsil accounted for 46.2% of our sites, some patients could have benefited from it, with less salivary toxicity.

All our patients were treated with three-dimensional conformal radiotherapy. Two randomised trials showed that intensity modulation markedly reduces xerostomia without loss of tumour control [8, 24]. Our parotid constraint, a mean dose of 30 to 33 Gy, is difficult to meet on both sides without intensity modulation when neck irradiation is bilateral. The late xerostomia rate of 15.4% is lower than those of the arms without intensity modulation in these trials. The retrospective collection, without a grading scale, suggests under-reporting rather than better tolerance.

Co-registration with magnetic resonance imaging was possible in only one quarter of patients. Yet this examination better defined tumour limits in 10 of 13 cases. Its wider use would improve contouring, particularly for the base of tongue.

Overall treatment time

Mean overall treatment time was 61 days against 49 planned, a delay of nearly two weeks. Prolongation of overall treatment time favours tumour repopulation and reduces local control in head and neck squamous cell carcinomas. The causes were acute toxicities and machine downtime. Corrective measures are well known: supportive care from the first week, nutritional support, preventive maintenance and compensation for missed fractions by a Saturday session or two fractions in one day.

Summary and areas for improvement

Table 5 sets the indicators of our series against reference data, and Table 6 derives corrective measures from them.

Table 5: Indicators of the series against reference data

Indicator	Our series	Reference data
Irradiation technique	Three-dimensional conformal in all 39 irradiated patients	Intensity modulation recommended [5, 6]
Late xerostomia	15.4%, all grades, retrospective collection	Grade 2 or worse at 12 months: 74% with conventional technique versus 38% with intensity modulation [8]
Grade 2 or worse acute salivary gland toxicity	Not collected	89% with three-dimensional conformal technique versus 59% with intensity modulation [24]
Concurrent chemotherapy	12 patients (23.1%), for 30 patients with N2 disease	Absolute overall survival gain of 6.5% at five years [7, 15]
Overall treatment time of radiotherapy	61 days on average	49 days planned
p16 status	Documented positive in 2 patients, not tested systematically	63.8% of tumours positive in the RTOG 0129 trial, with three-year overall survival of 82.4% versus 57.1% [4]
Unilateral neck irradiation	Not performed	Contralateral failure of 3.5% in selected tonsil tumours [22]

Table 6: Findings and proposed measures

Finding	Proposed measure
Median consultation delay of 6.7 months	Awareness among primary care physicians and dentists, fast-track referral pathway
p16 status rarely available	Systematic p16 immunohistochemistry on every oropharyngeal biopsy
Adjuvant radiotherapy in 22 of 29 operated patients	Stricter surgical selection at the tumour board, upfront chemoradiotherapy when adjuvant treatment is foreseeable
Margins and extranodal extension not reported in a standardised way	Standardised pathology report
Concurrent chemotherapy in only 12 patients	Systematic assessment of cisplatin eligibility: performance status, creatinine clearance, hearing
Three-dimensional conformal technique in all patients	Access to intensity-modulated radiotherapy
Systematic bilateral neck irradiation	Unilateral irradiation of lateralised T1 or T2 tonsil tumours
Co-registration with magnetic resonance imaging in 25% of patients	Systematic magnetic resonance imaging before contouring
Mean overall treatment time of 61 days	Preventive maintenance, compensation for missed fractions, early supportive care
Toxicities not graded and survival not analysed	Prospective registry with standardised toxicity grading and event dates

CONCLUSION

In our experience, oropharyngeal cancer presents at a locally advanced stage and radiotherapy is part of treatment in three out of four patients. Four measures fall directly within the remit of the radiation oncologist: access to intensity-modulated radiotherapy, adherence to the planned overall treatment time, extension of concurrent chemotherapy to all eligible patients and unilateral irradiation of lateralised tonsil tumours. Systematic p16 testing, standardised reporting of margins and extranodal extension, and a prospective registry will make it possible to evaluate these changes.

Conflict of interest: The authors declare no conflict of interest.

Funding: This study received no specific funding.

Authors' contributions: All authors contributed to patient care and to the writing of the manuscript, and approved its final version.

REFERENCES

1. Bray, F., Laversanne, M., Sung, H., Ferlay, J., Siegel, R. L., Soerjomataram, I., & Jemal, A. (2024). Global cancer statistics 2022: GLOBOCAN estimates of incidence and mortality worldwide for 36 cancers in 185 countries. *CA: A Cancer Journal for Clinicians, 74*(3), 229–263. https://doi.org/10.3322/caac.21834
2. Hashibe, M., Brennan, P., Chuang, S. C., Boccia, S., Castellsague, X., Chen, C., Curado, M. P., Dal Maso, L., Daudt, A. W., Fabianova, E., Fernandez, L., Wünsch-Filho, V., Franceschi, S., Hayes, R. B., Herrero, R., Kelsey, K., Koifman, S., La Vecchia, C., Lazarus, P., … Boffetta, P. (2009). Interaction between tobacco and alcohol use and the risk of head and neck cancer: pooled analysis in the International Head and Neck Cancer Epidemiology Consortium. *Cancer Epidemiology, Biomarkers & Prevention, 18*(2), 541–550. https://doi.org/10.1158/1055-9965.EPI-08-0347
3. Chaturvedi, A. K., Engels, E. A., Pfeiffer, R. M., Hernandez, B. Y., Xiao, W., Kim, E., Jiang, B., Goodman, M. T., Sibug-Saber, M., Cozen, W., Liu, L., Lynch, C. F., Wentzensen, N., Jordan, R. C., Altekruse, S., Anderson, W. F., Rosenberg, P. S., & Gillison, M. L. (2011). Human papillomavirus and rising oropharyngeal cancer incidence in the United States. *Journal of Clinical Oncology, 29*(32), 4294–4301. https://doi.org/10.1200/JCO.2011.36.4596
4. Ang, K. K., Harris, J., Wheeler, R., Weber, R., Rosenthal, D. I., Nguyen-Tân, P. F., Westra, W. H., Chung, C. H., Jordan, R. C., Lu, C., Kim, H., Axelrod, R., Silverman, C. C., Redmond, K. P., & Gillison, M. L. (2010). Human papillomavirus and survival of patients with oropharyngeal cancer. *The New England Journal of Medicine, 363*(1), 24–35. https://doi.org/10.1056/NEJMoa0912217
5. Machiels, J. P., Leemans, C. R., Golusinski, W., Grau, C., Licitra, L., & Gregoire, V. (2020). Squamous cell carcinoma of the oral cavity, larynx, oropharynx and hypopharynx: EHNS-ESMO-ESTRO Clinical Practice Guidelines for diagnosis, treatment and follow-up. *Annals of Oncology, 31*(11), 1462–1475. https://doi.org/10.1016/j.annonc.2020.07.011
6. Sher, D. J., Adelstein, D. J., Bajaj, G. K., Brizel, D. M., Cohen, E. E. W., Halthore, A., Harrison, L. B., Lu, C., Moeller, B. J., Quon, H., Rocco, J. W., Sturgis, E. M., Tishler, R. B., Trotti, A., Waldron, J., & Eisbruch, A. (2017). Radiation therapy for oropharyngeal squamous cell carcinoma: Executive summary of an ASTRO Evidence-Based Clinical Practice Guideline. *Practical Radiation Oncology, 7*(4), 246–253. https://doi.org/10.1016/j.prro.2017.02.002
7. Pignon, J. P., le Maître, A., Maillard, E., & Bourhis, J. (2009). Meta-analysis of chemotherapy in head and neck cancer (MACH-NC): an update on 93 randomised trials and 17,346 patients. *Radiotherapy and Oncology, 92*(1), 4–14. https://doi.org/10.1016/j.radonc.2009.04.014
8. Nutting, C. M., Morden, J. P., Harrington, K. J., Urbano, T. G., Bhide, S. A., Clark, C., Miles, E. A., Miah, A. B., Newbold, K., Tanay, M., Adab, F., Jefferies, S. J., Scrase, C., Yap, B. K., A'Hern, R. P., Sydenham, M. A., Emson, M., & Hall, E. (2011). Parotid-sparing intensity modulated versus conventional radiotherapy in head and neck cancer (PARSPORT): a phase 3 multicentre randomised controlled trial. *The Lancet Oncology, 12*(2), 127–136. https://doi.org/10.1016/S1470-2045(10)70290-4
9. Lydiatt, W. M., Patel, S. G., O'Sullivan, B., Brandwein, M. S., Ridge, J. A., Migliacci, J. C., Loomis, A. M., & Shah, J. P. (2017). Head and Neck cancers-major changes in the American Joint Committee on cancer eighth edition cancer staging manual. *CA: A Cancer Journal for Clinicians, 67*(2), 122–137. https://doi.org/10.3322/caac.21389
10. O'Sullivan, B., Huang, S. H., Su, J., Garden, A. S., Sturgis, E. M., Dahlstrom, K., Lee, N., Riaz, N., Pei, X., Koyfman, S. A., Adelstein, D., Burkey, B. B., Friborg, J., Kristensen, C. A., Gothelf, A. B., Hoebers, F., Kremer, B., Speel, E. J., Bowles, D. W., … Xu, W. (2016). Development and validation of a staging system for HPV-related oropharyngeal cancer by the International Collaboration on Oropharyngeal cancer Network for Staging (ICON-S): a multicentre cohort study. *The Lancet Oncology, 17*(4), 440–451. https://doi.org/10.1016/S1470-2045(15)00560-4
11. Bernier, J., Domenge, C., Ozsahin, M., Matuszewska, K., Lefèbvre, J. L., Greiner, R. H., Giralt, J., Maingon, P., Rolland, F., Bolla, M., Cognetti, F., Bourhis, J., Kirkpatrick, A., & van Glabbeke, M. (2004). Postoperative irradiation with or without concomitant chemotherapy for locally

advanced head and neck cancer. *The New England Journal of Medicine, 350*(19), 1945–1952. https://doi.org/10.1056/NEJMoa032641

12. Cooper, J. S., Pajak, T. F., Forastiere, A. A., Jacobs, J., Campbell, B. H., Saxman, S. B., Kish, J. A., Kim, H. E., Cmelak, A. J., Rotman, M., Machtay, M., Ensley, J. F., Chao, K. S., Schultz, C. J., Lee, N., & Fu, K. K. (2004). Postoperative concurrent radiotherapy and chemotherapy for high-risk squamous-cell carcinoma of the head and neck. *The New England Journal of Medicine, 350*(19), 1937–1944. https://doi.org/10.1056/NEJMoa032646
13. Bernier, J., Cooper, J. S., Pajak, T. F., van Glabbeke, M., Bourhis, J., Forastiere, A., Ozsahin, E. M., Jacobs, J. R., Jassem, J., Ang, K. K., & Lefèbvre, J. L. (2005). Defining risk levels in locally advanced head and neck cancers: a comparative analysis of concurrent postoperative radiation plus chemotherapy trials of the EORTC (#22931) and RTOG (# 9501). *Head & Neck, 27*(10), 843–850. https://doi.org/10.1002/hed.20279
14. Ang, K. K., Trotti, A., Brown, B. W., Garden, A. S., Foote, R. L., Morrison, W. H., Geara, F. B., Klotch, D. W., Goepfert, H., & Peters, L. J. (2001). Randomized trial addressing risk features and time factors of surgery plus radiotherapy in advanced head-and-neck cancer. *International Journal of Radiation Oncology, Biology, Physics, 51*(3), 571–578. https://doi.org/10.1016/s0360-3016(01)01690-x
15. Lacas, B., Carmel, A., Landais, C., Wong, S. J., Licitra, L., Tobias, J. S., Burtness, B., Ghi, M. G., Cohen, E. E. W., Grau, C., Wolf, G., Hitt, R., Corvò, R., Budach, V., Kumar, S., Laskar, S. G., Mazeron, J. J., Zhong, L. P., Dobrowsky, W., … Pignon, J. P. (2021). Meta-analysis of chemotherapy in head and neck cancer (MACH-NC): An update on 107 randomized trials and 19,805 patients, on behalf of MACH-NC Group. *Radiotherapy and Oncology, 156*, 281–293. https://doi.org/10.1016/j.radonc.2021.01.013
16. Ahn, M. J., D'Cruz, A., Vermorken, J. B., Chen, J. P., Chitapanarux, I., Dang, H. Q., Guminski, A., Kannarunimit, D., Lin, T. Y., Ng, W. T., Park, K. U., & Chan, A. T. (2016). Clinical recommendations for defining platinum unsuitable head and neck cancer patient populations on chemoradiotherapy: A literature review. *Oral Oncology, 53*, 10–16. https://doi.org/10.1016/j.oraloncology.2015.11.019
17. Noronha, V., Joshi, A., Patil, V. M., Agarwal, J., Ghosh-Laskar, S., Budrukkar, A., Murthy, V., Gupta, T., D'Cruz, A. K., Banavali, S., Pai, P. S., Chaturvedi, P., Chaukar, D., Pande, N., Chandrasekharan, A., Talreja, V., Vallathol, D. H., Mathrudev, V., Manjrekar, A., … Prabhash, K. (2018). Once-a-Week Versus Once-Every-3-Weeks Cisplatin Chemoradiation for Locally Advanced Head and Neck Cancer: A Phase III Randomized Noninferiority Trial. *Journal of Clinical Oncology, 36*(11), 1064–1072. https://doi.org/10.1200/JCO.2017.74.9457
18. Gillison, M. L., Trotti, A. M., Harris, J., Eisbruch, A., Harari, P. M., Adelstein, D. J., Jordan, R. C. K., Zhao, W., Sturgis, E. M., Burtness, B., Ridge, J. A., Ringash, J., Galvin, J., Yao, M., Koyfman, S. A., Blakaj, D. M., Razaq, M. A., Colevas, A. D., Beitler, J. J., … Le, Q. T. (2019). Radiotherapy plus cetuximab or cisplatin in human papillomavirus-positive oropharyngeal cancer (NRG Oncology RTOG 1016): a randomised, multicentre, non-inferiority trial. *The Lancet, 393*(10166), 40–50. https://doi.org/10.1016/S0140-6736(18)32779-X
19. Mehanna, H., Robinson, M., Hartley, A., Kong, A., Foran, B., Fulton-Lieuw, T., Dalby, M., Mistry, P., Sen, M., O'Toole, L., Al Booz, H., Dyker, K., Moleron, R., Whitaker, S., Brennan, S., Cook, A., Griffin, M., Aynsley, E., Rolles, M., … Dunn, J. (2019). Radiotherapy plus cisplatin or cetuximab in low-risk human papillomavirus-positive oropharyngeal cancer (De-ESCALaTE HPV): an open-label randomised controlled phase 3 trial. *The Lancet, 393*(10166), 51–60. https://doi.org/10.1016/S0140-6736(18)32752-1
20. Vermorken, J. B., Remenar, E., van Herpen, C., Gorlia, T., Mesia, R., Degardin, M., Stewart, J. S., Jelic, S., Betka, J., Preiss, J. H., van den Weyngaert, D., Awada, A., Cupissol, D., Kienzer, H. R., Rey, A., Desaunois, I., Bernier, J., & Lefebvre, J. L. (2007). Cisplatin, fluorouracil, and docetaxel in unresectable head and neck cancer. *The New England Journal of Medicine, 357*(17), 1695–1704. https://doi.org/10.1056/NEJMoa071028
21. Burtness, B., Harrington, K. J., Greil, R., Soulières, D., Tahara, M., de Castro, G., Psyrri, A., Basté, N., Neupane, P., Bratland, Å., Fuereder, T., Hughes, B. G. M., Mesía, R., Ngamphaiboon, N., Rordorf, T., Wan Ishak, W. Z., Hong, R. L., González Mendoza, R., Roy, A., … Rischin, D. (2019). Pembrolizumab alone or with chemotherapy versus cetuximab with chemotherapy for recurrent or metastatic squamous cell carcinoma of the head and neck (KEYNOTE-048): a randomised, open-label, phase 3 study. *The Lancet, 394*(10212), 1915–1928. https://doi.org/10.1016/S0140-6736(19)32591-7
22. O'Sullivan, B., Warde, P., Grice, B., Goh, C., Payne, D., Liu, F. F., Waldron, J., Bayley, A., Irish, J., Gullane, P., & Cummings, B. (2001). The benefits and pitfalls of ipsilateral radiotherapy in carcinoma of the tonsillar region. *International Journal of Radiation Oncology, Biology, Physics, 51*(2), 332–343. https://doi.org/10.1016/s0360-3016(01)01613-3
23. Biau, J., Lapeyre, M., Troussier, I., Budach, W., Giralt, J., Grau, C., Kazmierska, J., Langendijk, J. A., Ozsahin, M., O'Sullivan, B., Bourhis, J., & Grégoire, V. (2019). Selection of lymph node target volumes for definitive head and neck radiation therapy: a 2019 Update. *Radiotherapy and*

Oncology, 134, 1–9. https://doi.org/10.1016/j.radonc.2019.01.018

24. Gupta, T., Agarwal, J., Jain, S., Phurailatpam, R., Kannan, S., Ghosh-Laskar, S., Murthy, V., Budrukkar, A., Dinshaw, K., Prabhash, K., Chaturvedi, P., & D'Cruz, A. (2012). Three-dimensional conformal radiotherapy (3D-CRT) versus intensity modulated radiation therapy (IMRT) in squamous cell carcinoma of the head and neck: a randomized controlled trial. *Radiotherapy and Oncology, 104*(3), 343–348. https://doi.org/10.1016/j.radonc.2012.07.001