Scholars Journal of Medical Case Reports
Abbreviated Key Title: Sch J Med Case Rep
ISSN 2347-9507 (Print) | ISSN 2347-6559 (Online)
Journal homepage: https://saspublishers.com

OPEN ACCESS

Radiotherapy

Radiotherapy Planning Considerations in Pediatric Cystic Craniopharyngioma Requiring Repeated Decompression: A Case Report

Dr Basri Wijdane[1]*, Dr Hasna Rkha[1], Pr Darfaoui Mouna[1], Pr Oussalem Rajaa[1], Pr Igarramen Tarik[1], Pr Saadoune Mohammed[1], Pr Barkich Samir[1], Pr Sanae Laatitioui[1], Pr Elomrani Abdelhamid[1], Pr Khouchani Mouna[1]

[1]Department of Radiotherapy, Mohammed VI University Hospital, Marrakech, Morocco

DOI: https://doi.org/10.36347/sjmcr.2026.v14i11.102 | **Received:** 13.09.2026 | **Accepted:** 16.11.2026 | **Published:** 26.11.2026

***Corresponding author:** Dr Basri Wijdane
Department of Radiotherapy, Mohammed VI University Hospital, Marrakech, Morocco

Abstract | **Case Report**

Pediatric craniopharyngioma can cause substantial visual, endocrine, and hypothalamic morbidity despite its low histological grade. Predominantly cystic lesions present particular therapeutic challenges when repeated decompression is required before radiotherapy. We report a 7-year-old girl presenting with progressive visual deterioration and divergent strabismus. Initial magnetic resonance imaging (MRI) revealed a 48 × 46 × 46 mm predominantly cystic sellar and suprasellar mass associated with obstructive hydrocephalus. Ventriculoperitoneal shunting was followed by partial tumor resection and placement of an intracystic Ommaya reservoir. Histopathological examination confirmed adamantinomatous craniopharyngioma (CNS WHO grade 1). The postoperative course was characterized by severe bilateral visual impairment, a history of central adrenal insufficiency, and marked obesity. Recurrent episodes attributed to increased intracranial pressure required repeated cyst aspirations through the Ommaya reservoir, approximately every 12 days according to the patient's mother. Follow-up MRI in September 2026 demonstrated a persistent compressive cystic lesion measuring 41 × 39.5 × 52.5 mm, described as nearly stable, with persistent ventricular asymmetry. Focal fractionated radiotherapy was initiated at a prescribed dose of 54 Gy in 30 fractions, with planned clinical and radiological follow-up to assess cyst-volume dynamics, tumor control, and treatment-related toxicity. This case highlights the challenges of managing pediatric cystic craniopharyngiomas requiring repeated decompression. It emphasizes the importance of coordinating cyst drainage with radiotherapy planning, monitoring cyst-volume changes during treatment, and considering adaptive replanning when anatomical modifications compromise target coverage or organ-at-risk protection.

Keywords: Pediatric Craniopharyngioma, Adamantinomatous Craniopharyngioma, Ommaya Reservoir, Visual Impairment, Cyst Drainage, Radiotherapy.

Copyright © 2026 The Author(s): This is an open-access article distributed under the terms of the Creative Commons Attribution **4.0 International License (CC BY-NC 4.0)** which permits unrestricted use, distribution, and reproduction in any medium for non-commercial use provided the original author and source are credited.

1. INTRODUCTION

The treatment of pediatric craniopharyngioma requires a balance between durable disease control and preservation of visual, hypothalamic and pituitary function. The degree of hypothalamic involvement can influence both surgical strategy and functional outcome [1]. Visual morbidity may be present at diagnosis and can evolve during long-term follow-up [2]. Contemporary multimodal approaches therefore assess success through functional outcomes as well as radiological control; prospective evidence supports limited surgery followed by radiotherapy as an effective treatment pathway in selected children [3].

Predominantly cystic disease adds a procedural and planning burden. A cyst can require repeated decompression, while its anatomical relationship to the optic apparatus and ventricular system complicates subsequent treatment. We describe a child with a large residual adamantinomatous craniopharyngioma, severe visual disability and repeated Ommaya-mediated drainage whose subsequent radiotherapy regimen was prescribed with conventional fractionation. The case focuses on the relationship between clinical morbidity, interval imaging and the transition from decompression to longer-term tumor-directed treatment.

2. CASE PRESENTATION

2.1. Clinical History

We report the case of a Moroccan girl aged 7 years at the time of radiotherapy referral, who initially presented with progressive visual deterioration. Initial

ophthalmological management included corrective spectacles followed by visual rehabilitation, without significant clinical improvement. Progressive worsening of visual acuity, accompanied by the development of divergent strabismus, prompted further neuroradiological investigations. The precise interval between symptom onset and diagnosis could not be established from the available medical records.

2.2. Initial Neuroimaging and Preoperative Assessment

Brain magnetic resonance imaging in February 2025 identified a well-circumscribed, predominantly cystic midline sellar and suprasellar mass measuring 48 × 46 × 46 mm. The lesion had a thin enhancing wall and extended posteriorly toward the brainstem and cerebral peduncles. It displaced the floor of the third ventricle and caused hydrocephalus involving both lateral ventricles, with transependymal cerebrospinal fluid passage. The lesion also displaced branches of the circle of Willis, which remained patent. Craniopharyngioma was the leading radiological diagnosis.

A preoperative endocrine assessment in March 2025 was reported as normal. Ophthalmological evaluation that month documented vision limited to perception of hand movements.

2.3. Neurosurgical Treatment and Pathological Diagnosis

A ventriculoperitoneal shunt was placed in March 2025 for hydrocephalus. Partial tumor resection and insertion of an Ommaya reservoir for intracystic drainage were performed in April 2025. The operative approach and the anatomical reason for limiting resection were not specified in the clinical summary.

The initial pathological assessment required further immunohistochemical characterization. An addendum issued in June 2025 established adamantinomatous craniopharyngioma, reported as World Health Organization grade 1 under the 2021 classification, with cystic changes and calcification. Individual immunohistochemical markers and molecular results were not documented in the clinical summary.

2.4. Postoperative Course and Recurrent Drainage

The postoperative course was marked by severe visual impairment. Central adrenal insufficiency was also diagnosed and treated with hydrocortisone. Endocrine follow-up subsequently reported a normal corticotropin stimulation test, after which replacement was withdrawn under endocrine supervision. The exact withdrawal date and complete stimulation-test results were unavailable. Recurrent clinical episodes attributed to raised intracranial pressure required repeated aspiration through the Ommaya reservoir. The mother reported a drainage interval of approximately 12 days; a procedure-by-procedure record of dates, aspirated volumes and associated clinical findings was unavailable.

2.5. Interval Imaging and Referral for Radiotherapy

Computed tomography in July 2025 demonstrated a residual sellar and suprasellar cystic lesion with a calcified wall measuring approximately 41 × 37 × 42 mm. The left lateral ventricle remained enlarged, raising the possibility of ventricular isolation, whereas the right lateral ventricle was collapsed, described as a slit ventricle possibly related to overdrainage. The Ommaya catheter tip was within the cyst, and the shunt catheter was visible in the right lateral ventricle. Repeat computed tomography in August 2025 was reported as stable.

Magnetic resonance imaging in September 2026 showed persistent compressive sellar and suprasellar cystic disease measuring 41 × 39.5 × 52.5 mm in the reported anteroposterior, transverse and craniocaudal axes. The interpreting radiologist described the appearance as nearly stable relative to the comparison examination. The lesion displaced the third ventricular floor and compressed the optic chiasm, both thalami and the midbrain, with posterior extension and displacement of the pons. Close relationships with the supracavernous internal carotid arteries and other vessels of the circle of Willis were described, with maintained vascular patency. Left ventricular enlargement and right ventricular collapse persisted. Measurements across these computed tomography and magnetic resonance examinations were not used to assign a formal response category because acquisition methods, comparison examinations and drainage timing were not standardized.

Ophthalmological assessment in September 2026 recorded counting fingers at 4 m in the right eye and perception of hand movements in the left eye, together with bilateral optic atrophy. At radiation oncology assessment in November 2026, the child was alert, with a Glasgow Coma Scale score of 15/15. Divergent strabismus persisted; motor strength, sensation and coordination were preserved. Weight was 42 kg and height 121 cm, corresponding to a body mass index of 28.7 kg/m², described as obesity on pediatric growth assessment. Longitudinal weight and height data and a formal hypothalamic imaging grade were unavailable.

Postoperative radiotherapy was recommended for the persistent residual lesion at radiation oncology referral. The subsequent dose and fractionation are detailed below. Table 1 summarizes the clinical course.

2.6. Radiotherapy

The treating team confirmed a focal postoperative external-beam radiotherapy prescription of 54 Gy in 30 fractions of 1.8 Gy, scheduled as five fractions per week. This corresponds to a planned treatment duration of six weeks. Treatment dates,

completion status and actual elapsed duration require confirmation from the treatment record.

[Complete from the treatment record: exact delivery technique; start and completion dates; simulation and image registration; GTV, CTV and PTV definitions and volumes; organ-at-risk doses; verification imaging; cyst aspirations during treatment; and any adaptive replanning. These technical details are not established by confirmation of dose and fractionation alone.]

2.7. Available Follow-Up

Post-radiotherapy clinical and imaging outcomes were not available for manuscript preparation. The duration of follow-up, cyst measurements, subsequent aspiration requirements, visual and endocrine assessments and acute toxicity remain to be documented. No radiological response or functional improvement is inferred from treatment delivery alone.

Table 1: Timeline of the principal clinical, imaging and treatment events

Period	Event and documented findings
February 2025	Diagnostic MRI. 48 × 46 × 46 mm sellar and suprasellar cystic mass with obstructive hydrocephalus
March 2025	Preoperative assessment and shunting. Severe visual loss; endocrine assessment reported normal; ventriculoperitoneal shunt placed
April 2025	Tumor surgery. Partial resection with intracystic Ommaya reservoir placement
June 2025	Pathological addendum and endocrine care. Adamantinomatous craniopharyngioma, grade 1; postoperative adrenal replacement documented
July and August 2025	Interval CT. Persistent cystic residue; asymmetric ventricular appearances; second scan reported stable
Postoperative follow-up	Repeated cyst drainage. Approximately every 12 days by maternal report; individual procedure data unavailable
September 2026	MRI and ophthalmology. Persistent compressive cyst; severe bilateral visual impairment and optic atrophy
November 2026	Radiation oncology referral. Marked obesity; radiotherapy recommended for persistent residual disease.
After referral [dates to confirm]	Focal postoperative external-beam radiotherapy prescribed: 54 Gy in 30 fractions of 1.8 Gy, scheduled five fractions per week. Post-treatment outcomes not yet documented.

CT, computed tomography; MRI, magnetic resonance imaging. Drainage frequency is based on maternal report. Radiotherapy dates, completion status and post-treatment assessments require completion from the clinical record.

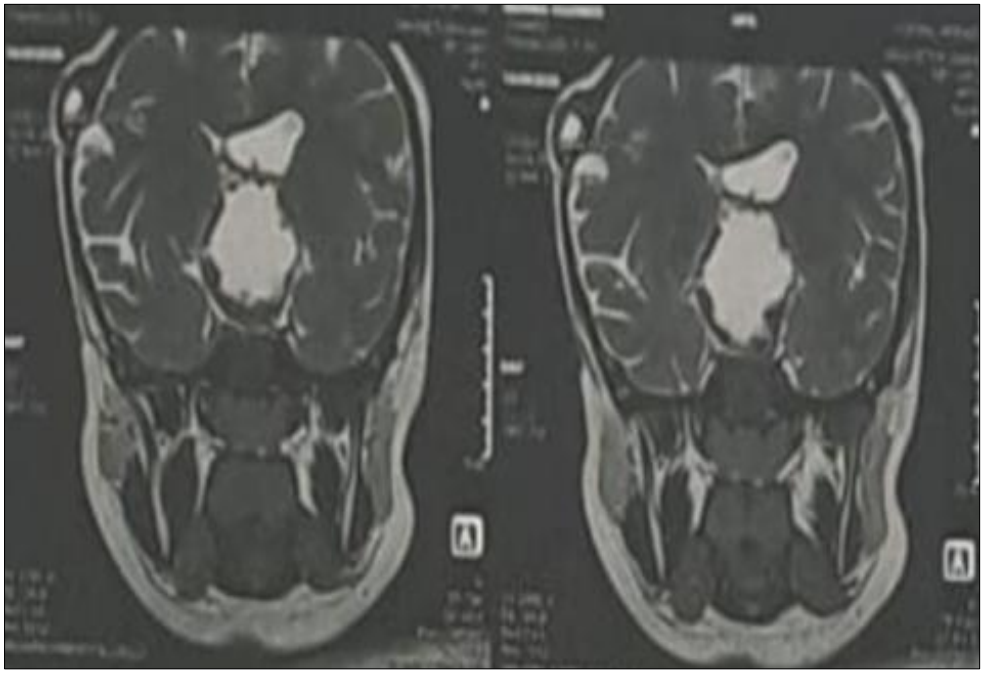

Figure 1: Coronal T2-weighted MRI demonstrating a large residual cystic sellar and suprasellar craniopharyngioma with compression of adjacent structures and distortion of the third ventricular region

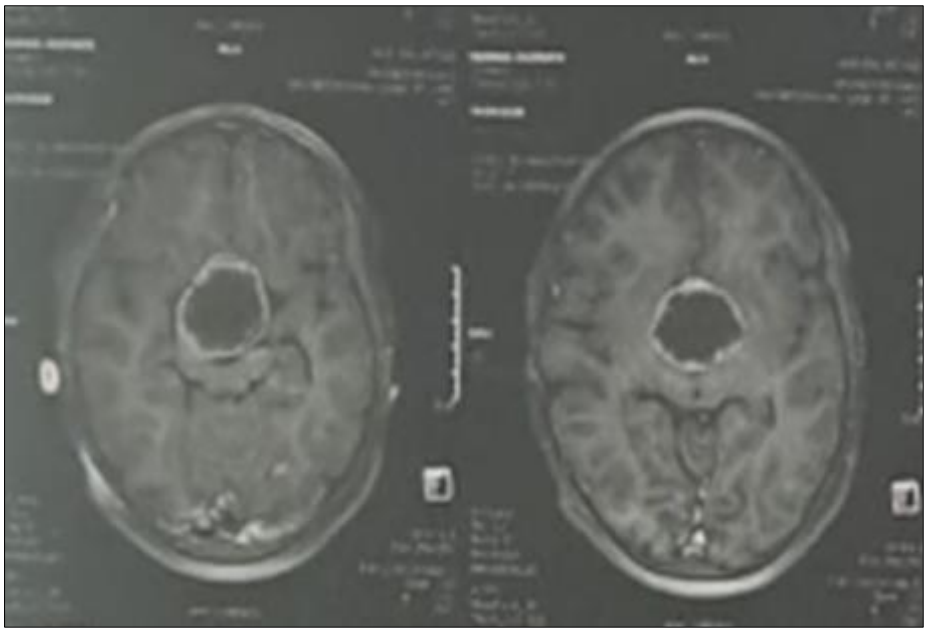

Figure 2: Axial contrast-enhanced T1-weighted MRI (T1 post-gadolinium) demonstrating a large residual cystic sellar and suprasellar craniopharyngioma with peripheral wall enhancement.

Table 2: Case-specific considerations for radiotherapy and assessment of outcome

Issue	Observation in this case	Implication and evidentiary limit
Cyst decompression	Repeated Ommaya aspirations, approximately every 12 days by maternal report	Record aspiration dates, volumes and clinical response; cyst kinetics cannot be reconstructed from frequency alone.
Ventricular dynamics	Persistent left ventricular enlargement and right slit ventricle	Correlate symptoms with shunt assessment and serial imaging before attributing them solely to cyst refilling.
Target anatomy	Large residual sellar and suprasellar cyst with optic and brainstem relationships	Coordinate decompression and simulation; interval imaging may identify anatomy requiring replanning [5–8].
Functional baseline	Severe visual impairment, optic atrophy, treated adrenal insufficiency and obesity	Document visual and endocrine status before treatment; a hypothalamic cause of obesity remains unconfirmed.
Radiotherapy regimen	54 Gy in 30 fractions of 1.8 Gy; exact technique and dates to be confirmed	Prescription dose and fractionation are established. Completion status, target coverage, organ-at-risk doses and use of replanning require the original treatment record.
Follow-up	Post-irradiation response and toxicity data unavailable	Document follow-up duration, cyst measurements, aspiration requirements, visual and endocrine outcomes, and toxicity before drawing conclusions about benefit.

3. DISCUSSION

3.1. Visual Morbidity beyond Histological Grade

The central educational feature is the extent of functional morbidity in a child whose tumor was classified as grade 1. Progressive visual deterioration persisted despite initial optical management and was followed by recognition of a large suprasellar lesion. This course supports reassessment when visual symptoms progress or are accompanied by acquired strabismus. However, the chronology does not establish a quantified diagnostic delay, nor can it determine whether a different referral interval would have altered the visual outcome.

Severe impairment was already documented before surgery. Subsequent visual disability therefore cannot be attributed solely to the operation. In a cohort of 59 children, Wan et al. reported visual decline during follow-up in 29%, with events occurring both early and years after diagnosis [2]. For the present child, serial age-appropriate visual acuity testing and optic nerve assessment are necessary to distinguish established damage from subsequent change. Divergent strabismus alone also does not establish an isolated oculomotor nerve palsy.

3.2. Clinical Significance of Repeated Cyst Drainage

The Ommaya reservoir provided ongoing access to the cyst after incomplete resection, but the reported need for frequent aspiration represents a substantial treatment burden. The association between recurrent symptoms and drainage is clinically relevant

even when an interval report uses the term stable. A scan obtained shortly after aspiration may depict a decompressed cyst and cannot establish the intervening behavior of that cyst. In this case, absent synchronization between procedures, symptoms and imaging prevents direct reconstruction of cyst kinetics.

Ommaya-assisted drainage has already been evaluated in conjunction with radiotherapy. Laville *et al*., reported volumetric and dosimetric observations in a small series treated with cyst puncture and hypofractionated stereotactic irradiation [4]. That experience provides a rationale for coordinating decompression with treatment planning, but it does not establish the optimal radiation schedule for this young child with extensive perioptic disease. The present case should consequently be interpreted as an illustration of a management problem rather than evidence for a novel procedure or a superior treatment strategy.

The asymmetric ventricular appearances add another consideration. Persistent left ventricular enlargement and right ventricular collapse could reflect cerebrospinal fluid compartmentalization or shunt-related dynamics, as suggested in the imaging reports. Recurrent symptoms cannot be assigned exclusively to cyst refilling without correlating cyst measurements, ventricular changes, shunt assessment and the response to aspiration. This distinction is important when deciding which intervention addresses the immediate cause of deterioration.

3.3. Rationale for Postoperative Radiotherapy

Partial resection can be appropriate when further surgery would threaten critical structures, although the reason for limiting resection in this child requires confirmation from the operative report [1]. Prospective RT2CR data support the feasibility of limited surgery followed by proton therapy: among 94 treated patients, the estimated 3-year progression-free survival was 96.8%. The study used historical photon-treated controls rather than randomized allocation and did not demonstrate a survival advantage for protons [3]. These findings support multimodal disease control while limiting the conclusions that can be drawn about comparative treatment effects.

Radiotherapy was recommended approximately 18 months after partial resection, and the treating team subsequently confirmed a prescription of 54 Gy in 30 fractions. The reasons for initial surveillance and the interval to treatment require documentation before assessing their clinical significance. This report does not establish that earlier irradiation would have prevented the recorded visual or endocrine morbidity.

3.4. Cyst Dynamics and Implications for Radiation Planning

For a frequently drained cyst, treatment planning must account for anatomical change after simulation. In the retrospective series of Lamiman *et al*., 11 of 27 patients developed cyst expansion within one year of intensity-modulated radiotherapy. Three had expansion during treatment and required adaptive planning [5]. Moorthy *et al*., also evaluated interval imaging during irradiation of residual cystic craniopharyngiomas, reinforcing the practical relevance of monitoring during treatment [6]. These studies address a risk relevant to this case; expansion during radiotherapy has not yet been documented in this child.

The RAPNO recommendations propose weekly rapid MRI during radiotherapy when feasible, or assessment during weeks 2 and 4 when weekly imaging is impractical. Their response framework also incorporates visual and endocrine function rather than relying on size alone [7]. French multidisciplinary consensus guidance recommends conventional fractionation, typically 50.4–54 Gy, and interval imaging to identify cyst-related changes that may require modification of target contours and dosimetry [8]. The confirmed prescription of 54 Gy in 30 fractions is consistent with this dose range. The imaging schedule, drainage timing and any replanning actually used in this child must be established from the treatment record. These elements cannot be inferred from the prescription alone.

3.5. Obesity and Endocrine Surveillance

Marked obesity is another important aspect of the presentation, but its mechanism remains incompletely characterized. In a comparative observational study, Elowe-Gruau *et al*., found less severe obesity after hypothalamus-sparing surgery than after an earlier extensive-resection strategy [9]. This evidence supports attention to hypothalamic preservation; it does not prove that the present child has acquired hypothalamic obesity. Her preoperative growth trajectory, timing of weight gain, appetite, sleep, medication exposure and direct hypothalamic imaging findings are needed before assigning that diagnosis.

Similarly, a previously normal endocrine assessment does not describe the entire subsequent course. The documented treatment for postoperative central adrenal insufficiency and reported later recovery warrant verification with the original endocrine records. Continued surveillance is relevant after surgery and any subsequent radiotherapy, including growth, thyroid and adrenal axes and water balance [8]. The visual, metabolic and endocrine outcomes should be reported separately rather than subsumed under a general neurological performance description.

3.6. Limitations and Learning Points

This single case cannot compare treatment strategies or establish causation between diagnostic timing, surgery and functional outcomes. Drainage frequency is based on maternal report, and longitudinal cyst volumetry, complete endocrine results and

standardized serial visual assessments are unavailable. Different imaging modalities and unspecified intervals from aspiration limit interpretation of size changes. Although the prescription of 54 Gy in 30 fractions has been confirmed, the technical treatment record and post-irradiation assessments remain incomplete. Radiation response, acute toxicity and any reduction in aspiration requirements therefore cannot yet be evaluated.

The principal learning points are:

- Progressive visual deterioration with acquired strabismus warrants reassessment, even after an initial ophthalmological treatment.
- Near-stable interval dimensions should be interpreted alongside the timing of drainage, symptom recurrence and ventricular dynamics.
- A frequently drained residual cyst creates a radiation-planning problem that requires coordination with neurosurgery and interval imaging.
- Visual, endocrine and metabolic outcomes must be reported separately; post-radiotherapy response cannot be inferred before treatment follow-up.

4. CONCLUSION

Pediatric cystic craniopharyngioma remains a therapeutic challenge despite its low histological grade, particularly when severe functional impairment and recurrent cyst expansion require repeated decompression. This case illustrates the complexity of managing a large residual adamantinomatous craniopharyngioma associated with profound visual impairment, altered ventricular dynamics, and frequent Ommaya-mediated cyst drainage. Focal fractionated radiotherapy was initiated at a prescribed dose of 54 Gy in 30 fractions to achieve durable local tumor control. From a radiation oncology perspective, the potential for cyst-volume fluctuations highlights the importance of multidisciplinary coordination, careful treatment planning, and interval imaging to identify anatomical changes that may require adaptive replanning. Long-term clinical, radiological, visual, and endocrine follow-up remains essential to evaluate treatment outcomes and functional morbidity.

REFERENCES

1. Puget S, Garnett M, Wray A, et al. Pediatric craniopharyngiomas: classification and treatment according to the degree of hypothalamic involvement. J Neurosurg. 2007;106(1 Suppl):3–12. doi:10.3171/ped.2007.106.1.3.
2. Wan MJ, Zapotocky M, Bouffet E, Bartels U, Kulkarni AV, Drake JM. Long-term visual outcomes of craniopharyngioma in children. J Neurooncol. 2018;137(3):645–651. doi:10.1007/s11060-018-2762-3.
3. Merchant TE, Hoehn ME, Khan RB, et al. Proton therapy and limited surgery for paediatric and adolescent patients with craniopharyngioma (RT2CR): a single-arm, phase 2 study. Lancet Oncol. 2023;24(5):523–534. doi:10.1016/S1470-2045(23)00146-8.
4. Laville A, Coutte A, Capel C, Maroote J, Lefranc M. Dosimetric and volumetric outcomes of combining cyst puncture through an Ommaya reservoir with index-optimized hypofractionated stereotactic radiotherapy in the treatment of craniopharyngioma. Clin Transl Radiat Oncol. 2020;23:66–71. doi:10.1016/j.ctro.2020.05.003.
5. Lamiman K, Wong KK, Tamrazi B, Nosrati JD, Olch A, Chang EL, Kiehna EN. A quantitative analysis of craniopharyngioma cyst expansion during and after radiation therapy and surgical implications. Neurosurg Focus. 2016;41(6):E15. doi:10.3171/2016.9.FOCUS16298.
6. Moorthy RK, Backianathan S, Rebekah G, Rajshekhar V. Utility of interval imaging during focused radiation therapy for residual cystic craniopharyngiomas. World Neurosurg. 2020;141:e615–e624. doi:10.1016/j.wneu.2020.05.258.
7. Hoffman LM, Jaimes C, Mankad K, et al. Response assessment in pediatric craniopharyngioma: recommendations from the Response Assessment in Pediatric Neuro-Oncology (RAPNO) Working Group. Neuro Oncol. 2023;25(2):224–233. doi:10.1093/neuonc/noac221.
8. Cuny T, Reynaud R, Raverot G, et al. Diagnosis and management of children and adult craniopharyngiomas: A French Endocrine Society/French Society for Paediatric Endocrinology & Diabetes Consensus Statement. Ann Endocrinol (Paris). 2025;86(1):101631. doi:10.1016/j.ando.2024.07.002.
9. Elowe-Gruau E, Beltrand J, Brauner R, et al. Childhood craniopharyngioma: hypothalamus-sparing surgery decreases the risk of obesity. J Clin Endocrinol Metab. 2013;98(6):2376–2382. doi:10.1210/jc.2012-3928.