

Post Traumatic Fat Embolism Syndrome Initially Suspected as COVID-19 Infection

M. El Abdi^{1*}, A. Zegmout², S. Akir³, A. Farouki⁴, M. Samali⁵, S. Khallikane⁵

¹Department of Orthopaedic Surgery, Military Hospital of Laayoun, Morocco

²Department of Pulmonology, Military Hospital of Laayoun, Morocco

³Department of Emergency, Military Hospital of Laayoun, Morocco

⁴Department of Radiology, Military Hospital of Laayoun, Morocco

⁵Department of Anesthesiology and Intensive Care, Military Hospital of Laayoun, Morocco

DOI: [10.36347/sjmc.2021.v09i11.002](https://doi.org/10.36347/sjmc.2021.v09i11.002)

| Received: 18.09.2021 | Accepted: 29.10.2021 | Published: 01.11.2021

*Corresponding author: Monsef Elabdi, MD

Abstract

Case Report

Acute respiratory distress is a clinico-biological syndrome in which acute hypoxemia is the main symptom. Various etiologies may be responsible. The SARS-COV-2 infection represents the first cause to be suspected because of the current pandemic context. However, several differential diagnoses may remain undetected. We present the case of a young patient admitted for a leg fracture complicated by a fat embolism syndrome after surgery with clinical and radiological manifestations mimicking a covid 19 infection.

Keywords: Fat embolism syndrome; COVID-19 infection; Respiratory distress; Fracture.

Copyright © 2021 The Author(s): This is an open-access article distributed under the terms of the Creative Commons Attribution 4.0 International License (CC BY-NC 4.0) which permits unrestricted use, distribution, and reproduction in any medium for non-commercial use provided the original author and source are credited.

INTRODUCTION

Post-traumatic fat embolism syndrome (FES) is a rare complication [1-2], first described in the literature in 1862 by Zenker [3]. It occurs in the hours or days following a long bone or multiple fractures [1-2, 4]. This potentially severe condition presents a polymorphic clinical picture with respiratory, neurological, and mucocutaneous signs [1]. It constitutes a major diagnostic challenge, especially in the era of COVID-19 infection [5, 6]. We report a case of suspected COVID-19 revealed to be fat embolism syndrome. Through this observation, we insist on the importance of the diagnostic and therapeutic approach in front of such clinical picture.

CLINICAL CASE

A 23-year-old man, with no previous pathological history, was the victim of a traffic accident on 08/3/2021, resulting in right leg trauma with a small puncture wound. X-ray of the leg showed a step-fracture of the tibia (Fig 1). The next day, the patient was operated on under spinal anesthesia. Nine hours after the operation, the patient presented acute respiratory distress with a fever of 39°.

Clinical examination revealed a conscious but agitated patient with polypnea at 25 cycles/min,

orthopnea and arterial oxygen saturation (SpO₂) at 80% on room air increased to 95% on O₂. The hemodynamic status was stable (BP 13/8, heart rate 110 b/min). The thighs and calves were supple. Pulmonary auscultation showed some crackling rales. Cardiovascular examination was unremarkable.

A chest X-ray showed diffuse bilateral nodular opacities (Fig 2). The biological workup showed hemoglobin at 13 g/dl, platelet at 158000/μl, CRP 153.7 mg/l, arterial blood gas (Pa O₂ at 55 mmhg; PH = 42; Pa CO₂ at 32 mmhg).

In view of the current situation, we suspected a covid-19 infection in the first line. Antigenic test or polymerase chain reaction (PCR) test on a nasopharyngeal swab was negative. Other diagnoses such as hemodynamic or lesional acute pulmonary edema, fibrino-cruciate or fat pulmonary embolism, or pneumonia were suggested.

CT angioscan revealed multiple bilateral and diffuse ground-glass nodules confluent in places associated with confluent areas of ill-limited condensation in posterobasal areas without image of thrombus at the level of the pulmonary bronchi to the segmental trunks (Fig 3) excluding a pulmonary embolism.

Despite the clinical presentation suggestive of covid-19, this diagnosis was eliminated in view of an incompatible radiological pattern (nodules), and the negativity of the diagnostic tests. The diagnosis of post-traumatic fat embolism seemed the most probable.

The patient was treated in intensive care unit with respiratory reanimation based on oxygen therapy associated with anticoagulants, diuretics and corticosteroids. 24 hours later, the evolution was good with clinical improvement and radiological lesion clearance (Fig 4). This fast evolution confirmed the diagnosis of fat embolism.

Table-1: Gurd's Criteria

Major criteria	Minor criteria
- Respiratory distress	- Tachycardia (> 110 bpm)
- Cerebral symptoms in non-head injury patients	- Fever (> 38.5 C)
- Petechial rash	- Jaundice
	- Renal changes
	- Retinal changes
	- Drop in hemoglobin
	- New onset thrombocytopenia
	- Elevated erythrocyte sedimentation rate (ESR)
	- Fat macroglobulinemia

2 major criteria or one major criterion and four minor criteria suggest a diagnosis of FES.

Table-2: Schonfeld's scoring system for FES

Petechial rash	5 points
Diffuse infiltrates on chest x-ray chest	4 points
Hypoxemia	3 points
Fever	1 point
Tachycardia	1 point
Confusion	1 point

Score > 5 diagnosis FES

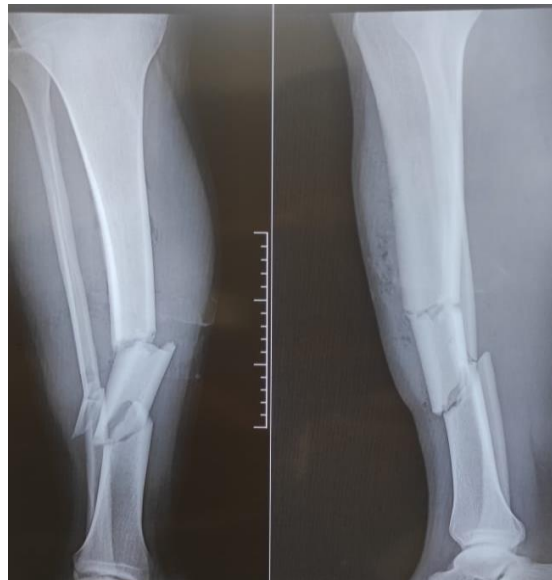

Fig-1: Anteroposterior and lateral leg X-ray at admission

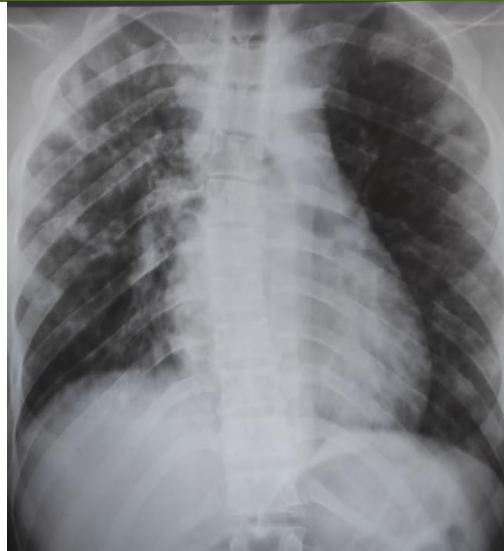


Fig-2: Chest X-ray

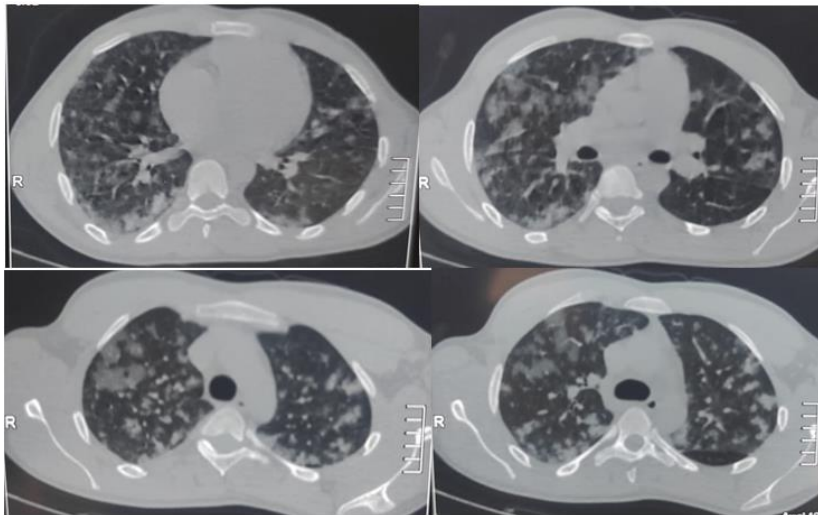


Fig-3: Computed Tomography Angiographic images reconstructed in the axial plane

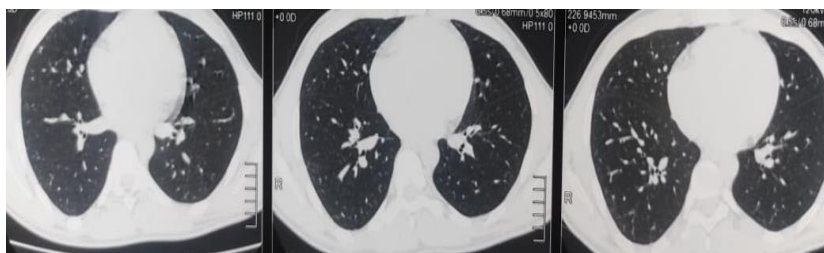

Fig-4: Radiological control (Computed Tomography Scan Thorax)

DISCUSSION

Covid 19 infection or SARS-COV-2 is a disease caused by coronavirus [7]. This dangerous and very contagious virus, identified in December 2019 in Wuhan, China, has caused a pandemic [7].

The pathology appears in different forms with polymorphic clinical manifestations from a simple cold to respiratory distress [8-11]. However, the fear of doctors in front of this viral pneumonia can cause

misdiagnosis with other pathologies with a similar clinical situation [8, 10, 12].

SEG is a severe complication in traumatology with a variable incidence from 0.5 to 30% in different studies [2]. It usually occurs within 48 hours, especially after a long bone fracture or a multiple fracture [4]. It is a combination of clinical, biological and radiological manifestations, due to dissemination of fat particles in the peripheral microcirculation or in the lung tissue [1, 5].

Diagnosis is difficult in the absence of specific paraclinical examinations. It is based on clinical signs that can be confused with other pathologies [5, 6]. It is an elimination diagnosis [3, 5, 6]. Diagnostic criteria have been proposed, such as those of Gurd in 1970 and the Schonfeld score [13-14] (Table 1, 2).

Treatment is primarily preventive, with thromboprophylaxis and early stabilization of the fracture site [1, 5, 15-17]. Curative treatment is based on medical reanimation with oxygen administration, adequate analgesia, vascular filling and stress management [1, 5, 15-17]. The benefit of corticosteroid therapy is discussed [18].

Our patient was a young man with a multiple fracture of the tibia. He presented acute respiratory distress a few hours after the operation with systemic manifestations realizing one major and 3 minor criterion according to Gurd; the Schonfeld score was 9. We considered the diagnosis SEG after exclusion of covid 19 diseases and fibrino-cruciate pulmonary embolism.

CONCLUSION

SEG represents a differential diagnosis of Covid 19 pneumonia. It should be evoked in the context of long bone trauma. This observation highlights the difficulty of the diagnostic approach to respiratory distress in the SARS-Cov-2 era.

Conflicts of interest

The authors have no conflicts of interest to declare.

REFERENCES

- Mellor, A., Soni, N. (2001). Fat embolism. *Anaesthesia*, 56; 145–54. <https://doi.org/10.1046/j.1365-2044.2001.01724.x>.
- Kirk, A., Elliott, J., Varma, D., & Kimmel, L. A. (2020). Fat embolism syndrome: Experience from an Australian trauma centre. *International journal of orthopaedic and trauma nursing*, 36, 100746.
- Zenker, F. A. (1862). *Beiträge zur normalen und pathologischen Anatomie der Lunge*. G. Schönfeld (CA Werner).
- Wilson, A., Hanandeh, A., Shamia, A. A., Louie, K., & Donaldson, B. (2020). Effective management of femur fracture using damage control orthopedics following fat embolism syndrome. *Cureus*, 12(3).
- Kosova, E., Bergmark, B., & Piazza, G. (2015). Fat embolism syndrome. *Circulation*, 131(3), 317-320.
- Shaikh, N., Parchani, A., Bhat, V., & Kattren, M. A. (2008). Fat embolism syndrome: clinical and imaging considerations: case report and review of literature. *Indian journal of critical care medicine: peer-reviewed, official publication of Indian Society of Critical Care Medicine*, 12(1), 32.
- Huang, C., Wang, Y., Li, X., Ren, L., Zhao, J., Hu, Y., ... & Cao, B. (2020). Clinical features of patients infected with 2019 novel coronavirus in Wuhan, China. *The lancet*, 395(10223), 497-506.
- Guo, T., Fan, Y., Chen, M., Wu, X., Zhang, L., He, T., ... & Lu, Z. (2020). Cardiovascular implications of fatal outcomes of patients with coronavirus disease 2019 (COVID-19). *JAMA cardiology*, 5(7), 811-818.
- Luo, L., Luo, Z., Jia, Y., Zhou, C., He, J., Lyu, J., & Shen, X. (2020). CT differential diagnosis of COVID-19 and non-COVID-19 in symptomatic suspects: a practical scoring method. *BMC pulmonary medicine*, 20(1), 1-9.
- Mazouz, S., Aissaoui, O., Fehdi, M. A., Nsiri, A., & AlHarrar, R. (2020). COVID-19 suspicion revealed to be fat embolism syndrome. *The Pan African medical journal*, 36.
- Meredith Wadman, J. C. F., & Jocelyn Kaiser, C. M. (2020). How does coronavirus kill? Clinicians trace a ferocious rampage through the body, from brain to toes. *Science*.
- Yang, Y., Yang, M., Yuan, J., Wang, F., Wang, Z., Li, J., ... & Liu, Y. (2020). Laboratory diagnosis and monitoring the viral shedding of SARS-CoV-2 infection. *The innovation*, 1(3), 100061.
- Gurd, A. R., & Wilson, R. I. (1974). The fat embolism syndrome. *The Journal of bone and joint surgery. British volume*, 56(3), 408-416.
- Schonfeld, S. A., Ploysongsang, Y., DiLISIO, R. A. L. P. H., Crissman, J. D., Miller, E., Hammerschmidt, D. E., & JACOB, H. S. (1983). Fat embolism prophylaxis with corticosteroids: a prospective study in high-risk patients. *Annals of internal medicine*, 99(4), 438-443.
- Shier, M. R., Wilson, R. F., James, R. E., Riddle, J. E. A. N. N. E., Mammen, E. F., & Pedersen, H. E. (1977). Fat embolism prophylaxis: a study of four treatment modalities. *The Journal of trauma*, 17(8), 621-629.
- Powers, K. A., & Talbot, L. A. (2011). Fat embolism syndrome after femur fracture with intramedullary nailing: case report. *American Journal of Critical Care*, 20(3), 267-266.
- Berdai, A. M., Shimi, A., & Khatouf, M. (2014). Le syndrome d'embolie graisseuse post traumatique. *The Pan African Medical Journal*, 17.
- Cavallazzi, R., & Cavallazzi, A. C. (2008). O efeito do corticosteroide na prevenção da síndrome da embolia gordurosa após fratura de osso longo dos membros inferiores: revisão sistemática com meta-análise. *Jornal Brasileiro de Pneumologia*, 34, 34-41.