

Giant Maxillary Sinus Mucocele: A Case Report

Dr. Dani Bouchra^{1*}, Dr. Sarra Benwadih¹, Dr. Olaya Hamidi¹, Pr. Boulaadas Malik²

¹Maxillofacial Surgery and Stomatology Department, IBN SINA University Hospital, Rabat, Morocco

²Mohammed V University, Faculty of Medicine and Pharmacy, Rabat, Morocco

DOI: [10.36347/sasjs.2022.v08i05.005](https://doi.org/10.36347/sasjs.2022.v08i05.005)

| Received: 24.03.2022 | Accepted: 04.05.2022 | Published: 10.05.2022

*Corresponding author: Dr. Dani Bouchra

Maxillofacial Surgery and Stomatology Department, IBN SINA University Hospital, Rabat, Morocco

Abstract

Case Report

Maxillary sinus mucocele is a benign cyst formation that originates within the sinus and is lined by epithelium containing mucus. It's a rare pathology characterized by a clinical polymorphism. This study reports the case of a giant left maxillary sinus mucocele in a 61-year-old female patient. Through clinical examination, vestibular deformation from tooth 23 to tooth 26 was determined, and also an exophthalmos. Facial CT scan showed a cystic mass of the left maxillary sinus with bone thinning. The treatment consisted in the excision of the mucocele pocket through Caldwell-Luc approach under general anesthesia.

Keywords: Mucocele, maxillary sinus, Caldwell Luc.

Copyright © 2022 The Author(s): This is an open-access article distributed under the terms of the Creative Commons Attribution **4.0 International License (CC BY-NC 4.0)** which permits unrestricted use, distribution, and reproduction in any medium for non-commercial use provided the original author and source are credited.

INTRODUCTION

Maxillary mucocele is a benign cyst formation that originates within one of the paranasal sinuses, lined by epithelium (sinus mucosa) containing mucus, which is caused by the progressive accumulation of mucus. It presents a slowly expanding growth and is asymptomatic at the beginning. It develops as a result of an obstruction of the maxillary sinus due to chronic sinusitis, polyps, bone tumors, trauma or after surgery [1, 2]. Maxillary sinus mucocele is caused by obstruction of the drainage ostium or a compartment of a septate sinus. Mucoceles in the maxillary sinuses are exceptional, with prevalence ranging from 3 to 10% [6]. The diagnosis is guided by the clinical and radiological outcome. Confirmed by the histological study of the specimen.

CASE REPORT

A 61-year-old female patient, with no history of sinus disease, allergies, facial trauma, or dental disease.

She presented a progressive left periorbital swelling, nasal obstruction and tearing, involving for one month. The patient reported numbness and pain in her left eye with no diplopia or limitation of the ocular movement.

The clinical examination of our patient founded a deformation of the left side of her face, with obliteration of the nasolabial fold and exophthalmos.

DIAGNOSTIC AIDS

A facial CT scan was performed showing a rounded formation with fluid density and regular contours filling the left maxillary sinus, expanding its walls, responsible for grade first exophthalmos and closing the left nasolacrimal duct (Figure 1 & 2).

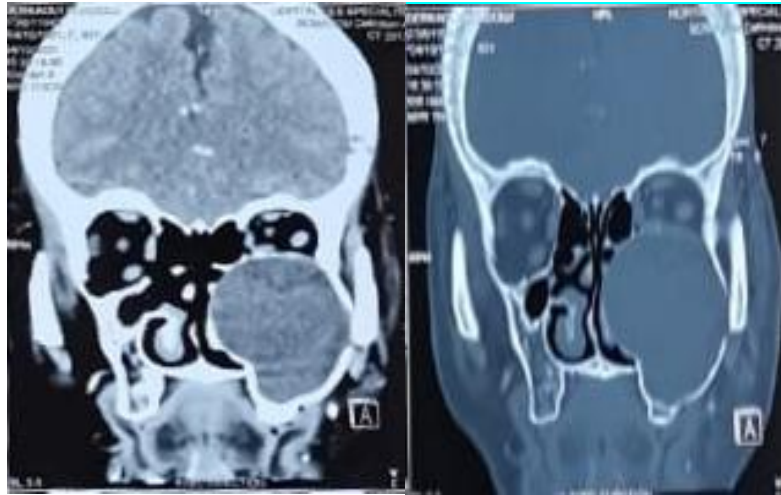


Figure 1: Coronal section of a facial CT scan showing a left maxillary sinus mucocoele

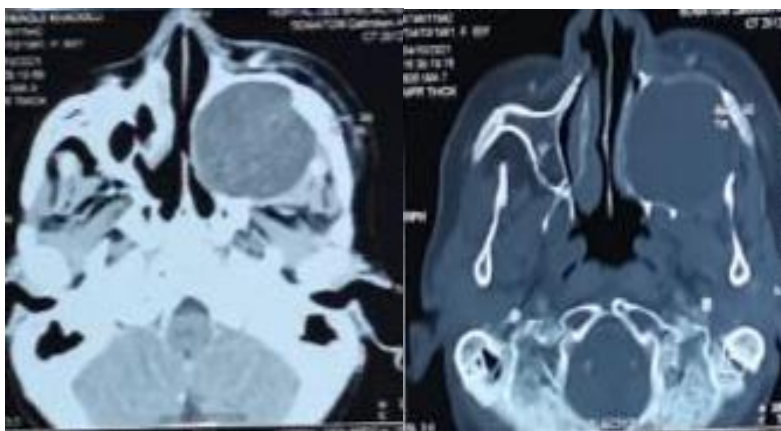


Figure 2: Axial section of a facial CT scan showing a left maxillary sinus mucocoele

TREATMENT AND OUTCOMES

The cystic mass was approached by Caldwell Luc surgical approach under general anesthesia, the anterior wall of the maxillary sinus was thinned. The opening of the cystic mass brought back a seromucous fluid. After aspiration of secretions, curettage of the mucocoele pocket was performed until its complete excision.

FOLLOWUP

The follow-ups were simple. Histopathology of the cyst wall confirmed our diagnosis of mucocoele demonstrating an exudate of neutrophils and macrophages enmeshed in fibrin, with foci of hemorrhage and lined with pseudostratified ciliated columnar epithelium. Clinical and radiological surveillance showed no recurrence with a 1-year follow-up.

DISCUSSION

Mucocoeles of the maxillary sinuses are epithelial-lined, mucus-containing sacs inside a maxillary sinus. They typically arise from chronic inflammation, scarring or surgical manipulation resulting in obstruction of the sinus ostia, although a

compartment of a septated sinus can similarly become obstructed.

Mucocoeles may occur at any age with no sex predilection, however, higher incidence is noted between the third and fourth decades of life. Mucocoeles in the maxillary sinuses are exceptional, with prevalence ranging from 3 to 10% [6].

Mucocoeles typically develop in two stages [10, 11]. An asymptomatic initial phase, where the mucocoele is discovered during an endoscopic or radiological examination performed during the monitoring of an initial rhino-sinus pathology. This is followed by the externalization or complication phase, corresponding to the clinical expression of the mucocoele. It is at this second phase that it is often diagnosed. The clinic is very polymorphic and varies according to the volume and location of the mucocoele.

Clinically, the maxillary sinus mucocoele can present swelling in the cheek, diplopia, hypoesthesia in the territory of the infraorbital nerve, teeth problems or swelling in the supraorbital margin; without pain [3].

CT scan is the examination of choice, the majority of mucocoeles images are homogeneous, hypodense with an absence of enhancement after the injection of contrast product with a typical rounded contour of the bone [3, 5].

The bone walls of the sinus can be remodeled, thinned or absent in some cases; however, they can keep their normal thickness in other situations [7].

The MRI, not systematic, allows to better evaluate the sub cranial and orbital contact or extension and to differentiate mucocoele from a tumor [7].

MRI will typically reveal variable intensity on T1, with relatively new mucocoeles appearing hypointense and gradually becoming more hyperintense as mucus becomes more inspissated with chronicity. T2 weighted images show a hyperintense mass [4].

Histologically, the maxillary sinus mucocoele is confined by an epithelial connective capsule made up of normal respiratory mucosa (pseudostratified ciliated cylindrical epithelium), with an underlying chorion that has fibrosis and chronic inflammation. Finding metaplastic squamous epithelium is rare, since the most common lining is ciliated respiratory mucosa.

The recommended treatment for maxillary sinus mucocoeles with no extension to soft tissues of the cheek is endoscopic evacuation with wide middle meatal antrostomy. Traditionally, the recommended treatment is a Caldwell-Luc technique with total removal of the mucocoele capsule and wide nasoorbital window [2]. But nowadays the traditional method has been replaced by replaced by endoscopic marsupialization with very low recurrence rate at or close to 0% and minimally invasive with a shorter postoperative recovery and less morbidity [11]. However, a Caldwell Luc approach is reserved for more extensive mucocoeles involving facial soft tissues, pterygomaxillary fossa. Similarly, mucocoeles developed as a result of facial trauma or previous surgery or those with incomplete enucleation by endoscopic sinus surgery require an open approach.

In our case, we performed enucleation via Caldwell Luc approach. The post operative period was uneventful. He was discharged on the 7th postoperative day. There were no signs of complications or disease recurrence on subsequent followup. The patient was compliant with the treatment provided.

CONCLUSION

Maxillary sinus mucocoeles are rare benign lesions and are often diagnosed during complications especially facial deformity and rarely in nervous disorders of the face. CT scanning is essential for diagnosis. Recommended treatment for mucocoeles of the maxillary sinus without extension, is endoscopic

drainage with a broad antrostomy of the middle meatus. A Caldwell Luc surgical approach can be indicated in cases with extension into the soft tissues of the face or the pterygopalatine fossa.

Conflicts of Interest: The authors declare no competing interest.

Authors' Contributions: All the authors participated in the treatment of this patient and in the redaction of this article.

Declaration of patient consent

The authors certify that they have obtained all appropriate patient consent forms. In the form, the patient(s) has/have given his/her/their consent for his/her/their images and other clinical information to be reported in the journal. The patients understand that their names and initials will not be published and due efforts will be made to conceal their identity, but anonymity cannot be guaranteed.

Financial support and sponsorship: None.

REFERENCES

1. Costan, V. V., Popescu, E., & Stratulat, S. I. (2013). A new approach to cosmetic/esthetic maxillofacial surgery: surgical treatment of unilateral exophthalmos due to maxillary sinus mucocoele. *The Journal of craniofacial surgery*, 24(3), 914-916.
2. Mohan, S. (2012). Frontal sinus mucocoele with intracranial and intraorbital extension: a case report. *Journal of maxillofacial and oral surgery*, 11(3), 337-339.
3. Trimarchi, M., Bertazzoni, G., & Bussi, M. (2013). Endoscopic treatment of frontal sinus mucocoeles with lateral extension. *Indian Journal of Otolaryngology and Head & Neck Surgery*, 65(2), 151-156.
4. Capra, G. G., Carbone, P. N., & Mullin, D. P. (2012). Paranasal sinus mucocoele. *Head and neck pathology*, 6(3), 369-372.
5. Sreedharan, S., Kamath, M. P., Hegde, M. C., Bhojwani, K., Alva, A., & Waheeda, C. (2011). Giant mucocoele of the maxillary antrum: a case report. *Indian Journal of Otolaryngology and Head & Neck Surgery*, 63(1), 87-88.
6. Natvig, K., & Larsen, T. E. (1978). Mucocoele of the paranasal sinuses: A retrospective clinical and histological study. *The Journal of Laryngology & Otolaryngology*, 92(12), 1075-1082.
7. Harnsberger, H., & Wiggins, D. (2005). Radiologie de poche tête et cou. *Paris: Maloine*, 335.
8. Sreedharan, S., Kamath, M. P., Hegde, M. C., Bhojwani, K., Alva, A., & Waheeda, C. (2011). Giant mucocoele of the maxillary antrum: a case report. *Indian Journal of Otolaryngology and Head & Neck Surgery*, 63(1), 87-88.

9. Klossek, J. M., Dufour, X., Ferrie, J. C., & Fontanel, J. P. (2003). Pneumosinus dilatans et mucocèles des cavités naso-sinusiennes. EMC (Elsevier Masson SAS, Paris) Oto-Rhino-Laryngologie, 20-730-A-10, 8p.
10. du Mayne, M. D., Moya-Plana, A., Malinvaud, D., Laccourreye, O., & Bonfils, P. (2012). Mucocèle des cavités naso-sinusiennes: histoire naturelle et fréquence des récives à long terme. *Annales françaises d'Oto-rhino-laryngologie et de Pathologie Cervico-faciale*, 129(3), 153-158.
11. Ba, M. C., Tall, A., Hossini, A. D. I. L., Ba, A. L., Ndoeye, N., Sakho, Y., & Badiane, S. B. (2005). Les mucocèles du sinus frontal en milieu neurochirurgical. A propos de 6 cas dakarois. *African Journal of Neurological Sciences*, 24(2), 40-46.