

Subcutaneous Scalp Meningioma: Case Study and Literature Review

Alas Ouammou^{1*}, Moudoumou Jean Davy¹, Oboa Cheryl Merveille¹, Mouna Bougrine¹, Fahd Derkaoui Hassani¹, Najia El Abbadi¹

¹Department of Neurosurgery, Cheikh Zaid International University Hospital, Abulcasis International University of Health Sciences, Rabat, Morocco

DOI: <https://doi.org/10.36347/sasjs.2025.v11i06.008>

| Received: 02.05.2025 | Accepted: 10.06.2025 | Published: 14.06.2025

*Corresponding author: Alas Ouammou

Department of Neurosurgery, Cheikh Zaid International University Hospital, Abulcasis International University of Health Sciences, Rabat, Morocco

Abstract

Case Report

Backgrounds: Subcutaneous scalp meningiomas are lesions that remain exceptional. Usually spread through iatrogenic ways, they can constitute a post-operative recurrence after the excision of an intracranial meningioma of usual location. The purpose of this study is to describe a rare of subcutaneous scalp meningiomas. **Methods:** We report a case of falco-sinusal meningiomas that underwent surgical removal. The follow-up was done for 10 years, by annual clinical examinations and brain MRI. The patient presented a recurrence as a subcutaneous scalp meningioma. We compared our case to the literature based on clinical, histological and radiological features. **Results:** We report the case of a 70 years old man who benefited from a surgical resection of a falco-sinusal meningioma 10 years ago. A year after surgery, a small recurrence at the surgical site was treated with Gamma-Knife radiosurgery with a relapse that led to a second surgery 7 years later. The patient presented three years later 2 scalp tumefactions that were removed. The pathological examination was in favor of a WHO 2016 grade 2 atypical meningioma infiltrating the connective-adipose tissue. **Conclusion:** Subcutaneous scalp meningiomas form a rare entity which is still under-described. Only 14 cases are reported in the literature. They represent a possible recurrence of a more classically located intracranial meningioma. We should consider this diagnosis when facing subcutaneous lesions in previous meningioma operative sites.

Keywords: Meningioma, subcutaneous, scalp, radiosurgery.

Copyright © 2025 The Author(s): This is an open-access article distributed under the terms of the Creative Commons Attribution 4.0 International License (CC BY-NC 4.0) which permits unrestricted use, distribution, and reproduction in any medium for non-commercial use provided the original author and source are credited.

INTRODUCTION

Meningiomas are a type of nervous system neoplasm which arise from the leptomeninges and are the most frequent benign intracranial brain tumors, with a female predominance [1]. Since the 2021 WHO tumor classification, meningiomas are now regarded as a single tumor type with 15 subtypes, and the malignancy grading has been changed to a within-tumor grading regardless of subtype (histological malignancy grading from 1 to 3) [2]. Usually, the risk of post-operative recurrence for grade 1 meningiomas is low, but for grade 2 and 3 it can be respectively 29-52% and 50-94% [3]. Metastasis in meningiomas a rare events, occurring in less than 0,76% of cases [4]. Subcutaneous scalp meningiomas are lesions that remain exceptional. Usually spread through iatrogenic ways, they can constitute a post-operative recurrence after the excision of a classical intracranial meningioma. We describe the case of a 70 years-old man who presented a subcutaneous scalp meningioma after the excision of a recurrent atypical grade 2 falcosinusal meningioma.

CASE REPORT

A 70 years-old man with no medical history undertook 4 surgeries for a recurrent left frontal falcosinusal meningioma. (Fig 1) The first surgery was a gross total removal of the lesion, with coagulation of dural attachment (Simpson II). Histology was in favor of WHO 2016 grade I meningioma and surgery outcome was good.

A year after surgery, a small recurrence was treated with Gamma-Knife radiosurgery. (Fig 2) 3 years follow up noticed a tumor progression after radiosurgery. (Fig 3) The patient underwent a second surgery, which took place seven years after the first one, was a gross total removal with resection of the falx cerebri, resection and ligation of the longitudinal superior sinus and cranioplasty. Surgical outcome was good. The pathological examinations of the tumors were in favor of WHO 2016 grade 2 atypical meningioma.

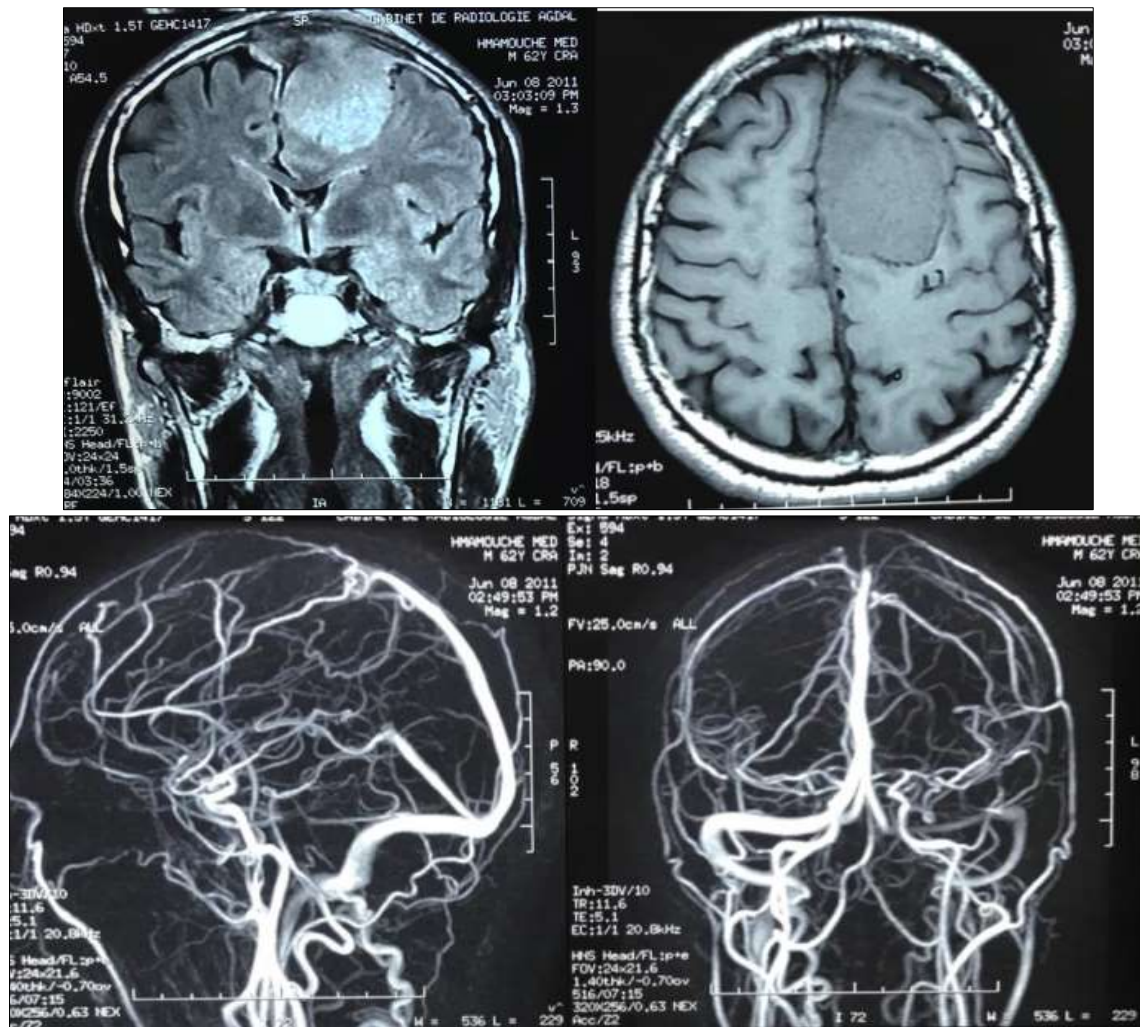


Fig. 1: Cerebral MRI showing the initial falcosinus meningeoma, before the first surgery. The lesion is showed to have mass effect on brain parenchyma. It has an extension to the cranial bone and venous reconstruction shows an occluded superior longitudinal sinus

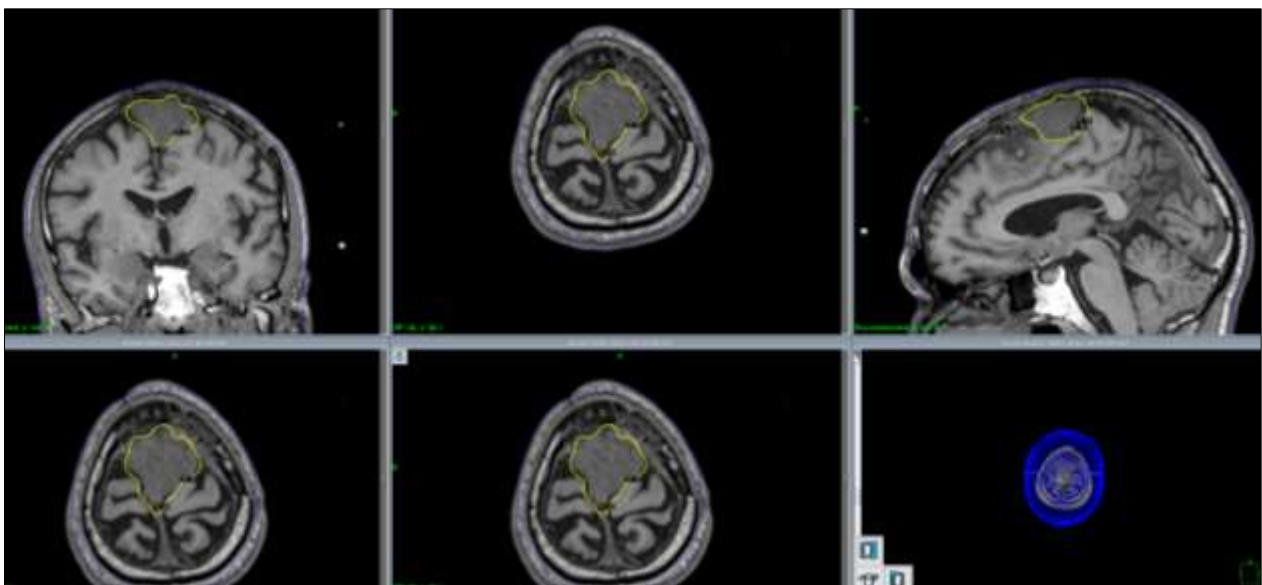


Fig. 2: Cerebral MRI showing recurrence of the meningeoma, a year after the first surgery. It shows the initial radiosurgery planning

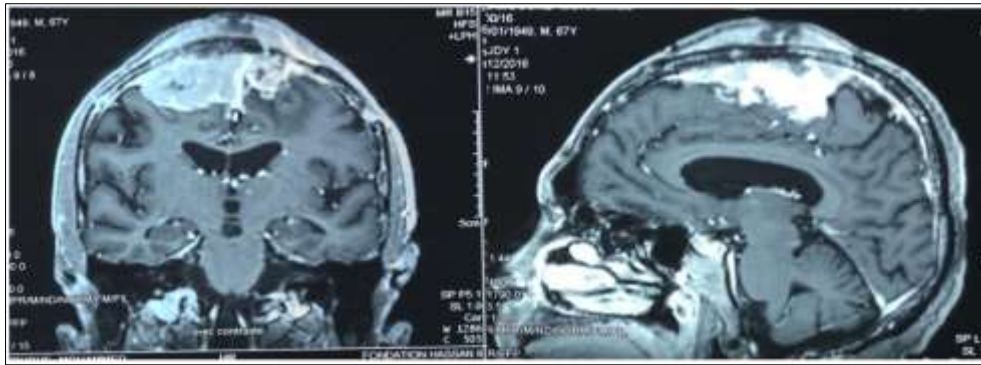


Fig. 3: Cerebral MRI showing progression of the meningioma 3 years after Gamma-knife radiosurgery

Three years later (ten years after the first surgery), he presented 2 scalp tumefactions over the operation site. These lesions were renitent, adhering to the deep plane and one had a reddish aspect. MRI showed 2 T1 and T2 iso-intense lesions of the scalp of 1,5 and 2 cm in diameter with a heterogeneous enhancement. And no intracranial recurrence. (Fig.4)

The patient underwent a gross total removal of both the lesions which had a macroscopic aspect evoking meningiomas. The pathological examination was in favor of a WHO 2016 grade 2 atypical meningioma infiltrating the connective-adipose tissue. After multidisciplinary discussion, radiotherapy was not retained in the absence of intracranial recurrence.

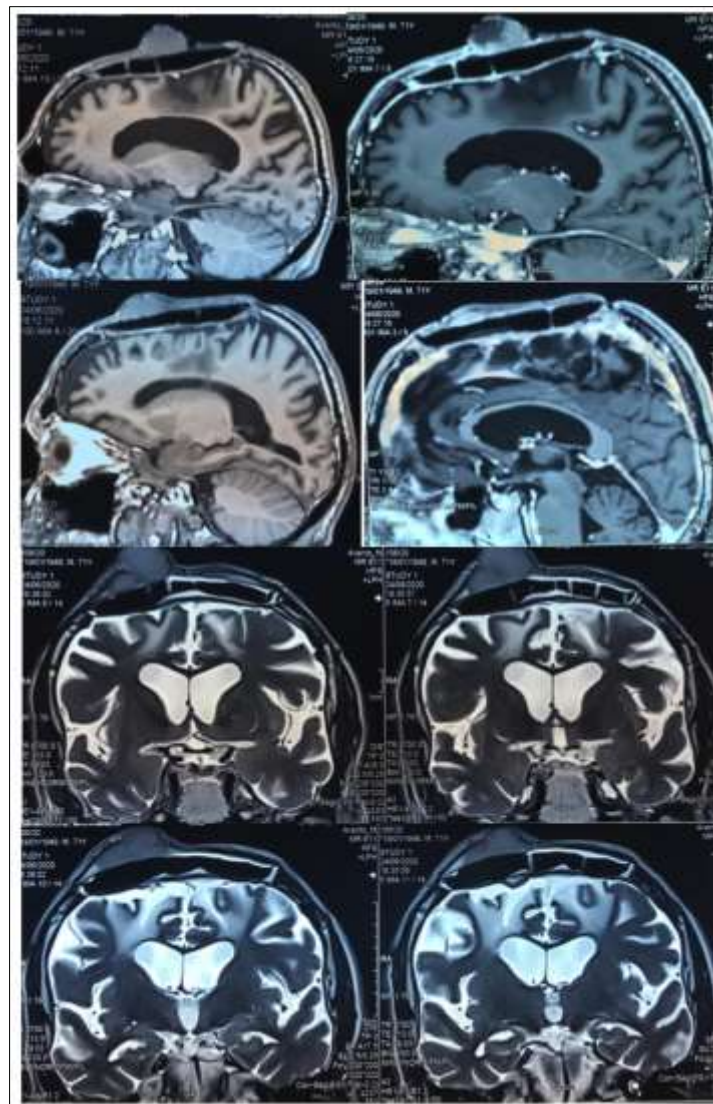


Fig. 4: Cerebral MRI ten years after first surgery, showing 2 subcutaneous meningioma recurrences

He again presented himself three years later (thirteen years after first surgery) with another recurrence of the lesions. This time there was a

subcutaneous as well as an intradural involvement of the meningioma. (Fig 5 and 6) He benefited from a partial removal of the lesion. Surgical outcome was good.

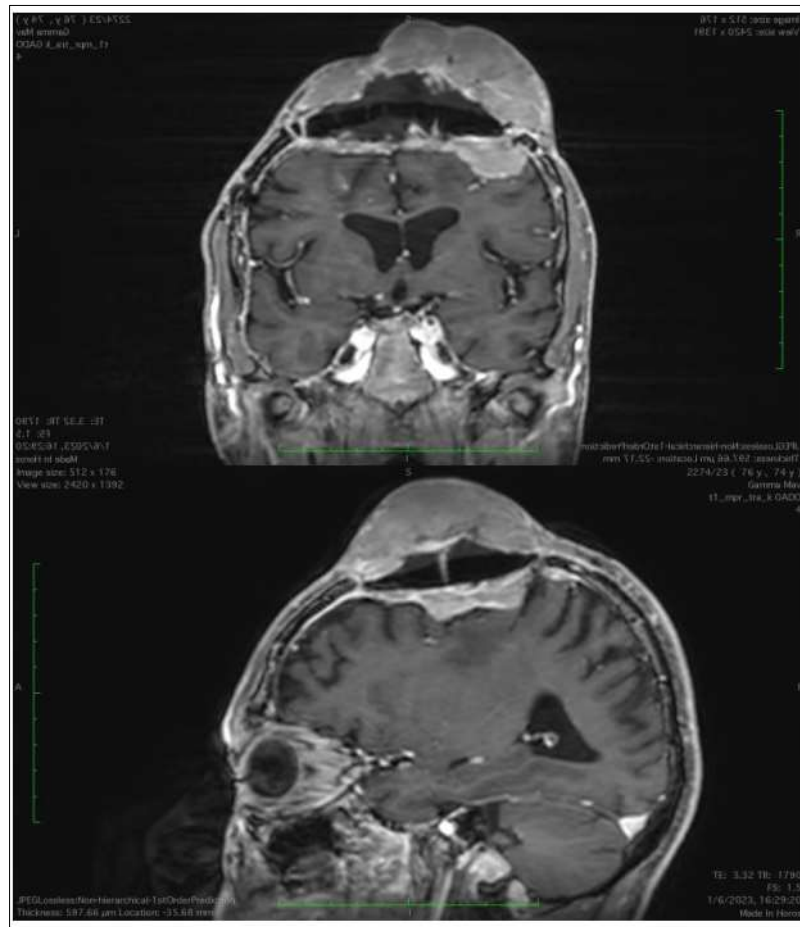


Fig. 5: Cerebral MRI showing the last recurrence to date

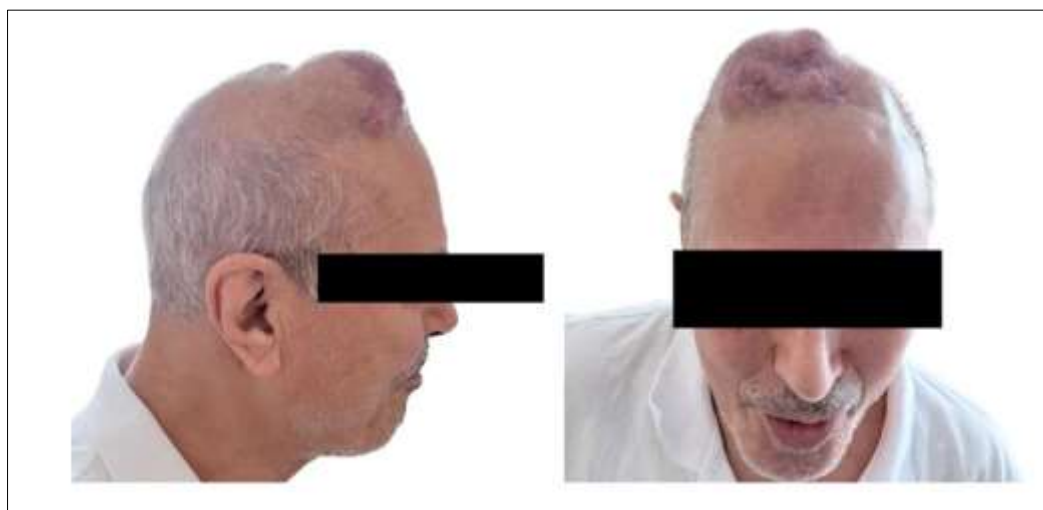


Fig. 6: Aspect of the scalp during last recurrence

DISCUSSION

Subcutaneous scalp meningiomas are a rare entity which are still under described. Only 14 cases are reported in the literature [5]. Of these 14 cases of

subcutaneous scalp meningiomas, 42,86% were grade 1 meningiomas and 50% were grade 2 meningiomas. Of the 14 patients, 6 had radiation, 5 had no radiation and 3 were not reported.

The time interval between the first surgery and the diagnosis of subcutaneous meningioma recurrence range between 5 months and 13 years, and the median interval is 41,50 months [5]. Our patient had an interval of 10 years.

Of the cases described, 42,86% of them occurred in patients with WHO grade 1 meningiomas, like in our case. That suggests that we can expect metastasis not only in high grade, but even in low grade meningiomas. Of these 6 cases of WHO grade 1 meningiomas, 2 benefited from radiation and they both evolved from WHO grade 1 to WHO grade 2 and 3 respectively on the metastatic site [5]. Our patient also had a WHO grade 1 meningioma that evolved into multiple WHO grade 2 subcutaneous tumors.

Usually, radiation-induced meningiomas appear more frequently as multiple lesions and with a higher recurrence rate. The surgical treatment should involve larger bone and dura margins [1]. Also the recurrence rate is up to 25,6% [6], as compared with recurrence rates of up to 11,4% in nonradiation-induced meningiomas. These recurrences are also more rapid, happening 4 years earlier than nonirradiated patients [1].

The follow-up of subcutaneous meningiomas should therefore be closer than regular meningiomas especially if the patient was irradiated and if the recurrence was multiple, because it is a highly invasive form of meningioma.

Avecillas-Chasin *et al.*, describe a 4 cases study which identifies different favoring factors as multiple operations, immunosuppression, radiotherapy, CSF fistula and histological progression [7].

Some operative precautions are suggested to avoid subcutaneous recurrences like the meticulous wash of the operation site with saline and regular tool changes during the different operative times to avoid these recurrences [5].

Distant meningiomas metastasis occur infrequently, with an incidence of less than 1 per 1000. They can involve vertebral bodies, lungs, liver, long bones and the spinal cord [4]. No specific management seem to be defined. Some authors suggest radiation therapy and chemotherapy with hydroxyurea, sunitinib

or mifepristone, but there is still little evidence supporting these claims [8].

CONCLUSION

Subcutaneous scalp meningiomas are a possible recurrence of a more classically located intracranial meningioma. We should take in consideration this diagnosis when facing subcutaneous lesions over a previous meningioma operative site. Post-surgical follow-up should be closer than regular meningiomas, as this form might be highly invasive.

REFERENCES

1. DeMonte F, McDermott MW, Al-Mefty O. Al-Mefty's Meningiomas. 2nd ed. New York: Thieme medical; 2011.
2. Torp SH, Solheim O, Skjulsvik AJ. The WHO 2021 Classification of Central Nervous System tumours: a practical update on what neurosurgeons need to know—a minireview. *Acta Neurochir (Wien)*. 2022;164(9):2453-64.
3. Buttrick S, Shah AH, Komotar RJ, Ivan ME. Management of Atypical and Anaplastic Meningiomas. *Neurosurg Clin N Am*. 1 avr 2016;27(2):239-47.
4. Ather Enam S, Abdulrauf S, Mehta B, Malik GM, Mahmood A. Metastasis in meningioma. *Acta Neurochir (Wien)*. 1 oct 1996;138(10):1172-8.
5. Liu Y, Li J, Duan Y, Ye Y, Xiao L, Mao R. Subcutaneous Metastasis of Atypical Meningioma: Case Report and Literature Review. *World Neurosurg*. juin 2020;138:182-6.
6. Rubinstein AB, Shalit MN, Cohen ML, Zandbank U, Reichenthal E. Radiation-induced cerebral meningioma: a recognizable entity. *J Neurosurg*. nov 1984;61(5):966-71.
7. Avecillas-Chasin JM, Saceda-Gutierrez J, Alonso-Lera P, Garcia-Pumarino R, Issa S, López E, et al. Scalp Metastases of Recurrent Meningiomas: Aggressive Behavior or Surgical Seeding? *World Neurosurg*. juill 2015;84(1):121-31.
8. Paix A, Waissi W, Antoni D, Adeduntan R, Noël G. Visceral and bone metastases of a WHO grade 2 meningioma: A case report and review of the literature. *Cancer/Radiothérapie*. 1 févr 2017;21(1):55-9.