SAS Journal of Surgery
Abbreviated Key Title: SAS J Surg
ISSN 2454-5104
Journal homepage: https://www.saspublishers.com

OPEN ACCESS

Paediatrics Surgery

Ruptured Patent Urachus: A Case Report

Dr Kshitija Pokharkar[1]*, Dr Audrey Pais[2], Dr Paras Kothari[3], Dr Abhaya Gupta[4], Dr Shahaji Deshmukh[5]

[1]1st Year Mch Resident, Department of Pediatric Surgery, Lokmanya Tilak municipal Hospital, Sion
[2]Assistant Professor, Department of Paediatrics Surgery, LTMMC, Sion
[3]Head of Department, Department of Paediatrics Surgery, LTMMC, Sion
[4]Additional Professor, Department of Pediatric Surgery, LTMMC Sion
[5]Associate Professor, Department of Pediatric Surgery, LTMMC Sion

DOI: https://doi.org/10.36347/sasjs.2026.v12i10.007 | **Received:** 19.08.2026 | **Accepted:** 14.10.2026 | **Published:** 15.10.2026

***Corresponding author:** Dr Kshitija Pokharkar
1st Year Mch Resident, Department of Pediatric Surgery, Lokmanya Tilak municipal Hospital, Sion

Abstract **Case Report**

A patent urachus is a congenital anomaly resulting from complete failure of obliteration of the urachus, producing a persistent tubular communication between the apex of the urinary bladder and the umbilicus.[1] Herein, we report a case of ruptured patent urachus in a neonate. The day after delivery, the neonate underwent Examination under Anesthesia wherein patent urachus was confirmed by inserting an infant feeding tube which runs through the ruptured urachus exposing bladder The mechanism of patent urachus rupture is unknown. As the fetus matures in utero, it is thought that the higher intravesical pressure may affect the rupture of the cyst. Patent urachus could be ruptured in the uterus spontaneously, and surgical correction is needed.

Keywords: Patent urachus, Neonate, Congenital anomaly, Umbilicus, Vesicoureteric reflux, Urachal tract excision.

Copyright © 2026 The Author(s): This is an open-access article distributed under the terms of the Creative Commons Attribution **4.0 International License (CC BY-NC 4.0)** which permits unrestricted use, distribution, and reproduction in any medium for non-commercial use provided the original author and source are credited.

Introduction

Patent urachus, a remnant of the embryonic allantois, is defined as an abnormality of the umbilicus connecting with the bladder. Patent urachus is rare as it is reported in 1 to 2 or 2.5 per 1,000,000 live births.[1] The urachus develops from the allantois, which connects the fetal bladder to the yolk sac through the umbilical cord. Normally, between the 4th and 5th months of gestation, the bladder descends into the pelvis and the urachal lumen progressively obliterate which becomes the median umbilical ligament after birth. Failure of involution leads to urachal remnants. However, there are a few cases of patent urachus prenatally ruptured in the uterus. Herein, we report a case of ruptured patent urachus detected after birth.

Case Presentation

A day of life 1 male child, normal vaginal delivery was referred to our hospital with exposed mucosa at the umbilicus with suspected urine discharge from the umbilicus. Patient had passed urine in good stream per urethral and meconium within 24 hours of birth. The day after delivery, neonate underwent examination under anaesthesia wherein an infant feeding tube was inserted per urethral which was seen passing through the ruptured urachus at umbilical cord insertion. No ureteric openings were visualized.[3]

Figure 1: Picture of an Infant feeding tube passing through ruptured urachus at the umbilical cord insertion.The arrow indicates beginning of infant feeding tube

Patient underwent further investigations where ultrasonography report was suggestive of tubular structure measuring 1x1.1cm with an pproximate length of 7-8cm from superior aspect of urinary bladder reaching upto the anterior abdominal wall through the umbilicus.

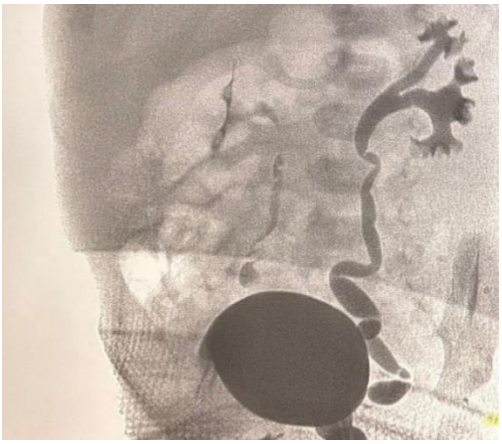

Figure 2(a): VCUG showing Bilateral vesicoureteric reflux

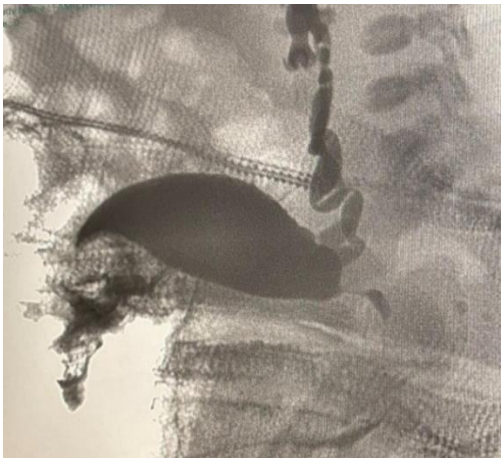

Figure 2(b): Lateral film with black arrow denoting trickling of dye from ruptured urachus

Patient also underwent a VCUG wherein dye was seen trickling from the umbilicus and patient also had Bilateral vesicoureteric reflux. At the age of 3 months, patient underwent Diagnostic cystoscopy cause of obstructive uropathy was ruled out. Patient underwent Umbilical Exploration with delineation of urachal tract and ligation and excision of urachul tract with closure of bladder wall defect in two layers. Post operative course was uneventful and patient was discharged on post operative day 5 on full feeds and chemoprophylaxis.

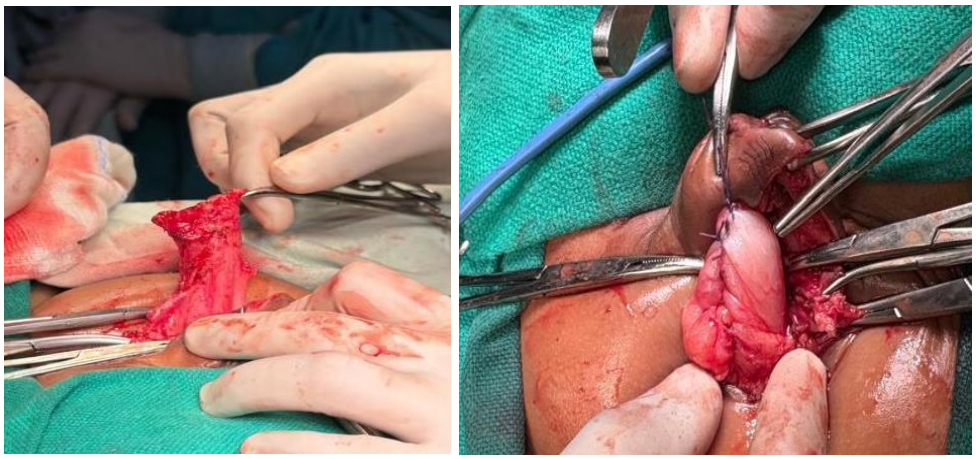

Figure 3(a): Intraoperative picture of ruptured urachus connecting to bladder
3(b): Intraoperative picture of bladder closure

Discussion

The classical presentation of a patent urachus is persistent leakage of urine from the umbilicus shortly after birth. However, the clinical spectrum may vary considerably depending on the degree of patency and the presence of infection. In rare instances, a patent urachus may present as an umbilical mass, recurrent umbilical

infection, cellulitis, or spontaneous rupture of a cystic swelling with urinary discharge. The occurrence of a ruptured patent urachus in the neonatal period is particularly uncommon and may lead to diagnostic confusion with other causes of umbilical discharge. These anomalies include patent urachus (47%), urachal cyst (30%), umbilical-urachal sinus (18%), classified by the level of persistence of the embryonic urachal remnants between the bladder and umbilicus. The mechanism of patent urachus rupture is unknown.[1] One hypothesis related to patent urachus is increased pressure within the bladder, such as in obstructive uropathy which could be the cause of vesicoureteric reflux. As the fetus matures, it is thought that the higher intravesical pressure may impact the rupture of the cyst. The classical presentation of a patent urachus is persistent leakage of urine from the umbilicus shortly after birth. However, the clinical spectrum may vary considerably depending on the degree of patency and the presence of infection. The occurrence of a ruptured patent urachus in the neonatal period is particularly uncommon and may lead to diagnostic confusion with other causes of umbilical discharge. The differential diagnosis of neonatal umbilical discharge includes umbilical granuloma, omphalitis, persistent omphalomesenteric duct, umbilical polyp, infected urachal remnants, and congenital abdominal wall anomalies. Distinguishing among these conditions is crucial because management strategies differ significantly. The presence of clear fluid discharge that increases during micturition or crying should raise suspicion of a communication with the urinary tract.[2]Imaging studies play a central role in diagnosis. In the present case, imaging findings were consistent with a patent urachus and facilitated appropriate surgical planning.

The definitive treatment of patent urachus is complete surgical excision of the urachal tract with closure of the bladder dome. Early surgical intervention is recommended to prevent recurrent infection, persistent urinary leakage, skin excoriation, and ascending urinary tract infections. Complete excision also eliminates the risk of future complications associated with persistent urachal remnants. Advances in minimally invasive surgery have enabled laparoscopic management in selected patients; however, open surgical excision remains a safe and effective option in neonates and small infants.

Conclusion

A high index of suspicion, coupled with appropriate radiological evaluation, is essential for early diagnosis and exclusion of associated urinary tract anomalies. Prompt surgical excision of the urachal remnant with secure bladder closure remains the treatment of choice and provides excellent functional and cosmetic outcomes. This case underscores the importance of considering urachal anomalies in neonates presenting with persistent umbilical leakage or unusual umbilical masses and highlights that timely recognition and definitive management can prevent potentially serious infectious and urinary complications.

References

1. Prenatally Ruptured Patent Urachus: A Case Report and Review of Literature by Ji-Young Kwon1 and Seung-Yeon Pyeon
2. Svigos, J.; Khurana, S.; Munt, C.; Sinhal, S.; Bernardo, J. Presentation of an umbilical cord cyst with a surprising jet: A case report of a patent urachus. F1000Research 2013, 2, 38. [Google Scholar] [CrossRef] [PubMed
3. Srisupundit, K.; Mahawong, P.; Charoenratana, C.; Tongsong, T. Prolapsed bladder following rupture of patent urachal cyst, mimicking bladder exstrophy: A case report and literature review. J. Med. Ultrason. 2018, 45, 529–533. [Google Scholar] [CrossRef] [PubMed]