

## A Case of Fatal Laparoscopic Tubectomy in a Young Woman – Case Report

Dr Vijay Kumar A G<sup>1</sup>, Dr Kumar U<sup>1</sup>, Dr M G Shivaramu<sup>2</sup>, Dr Satish NT<sup>1</sup>, Dr Vinay J<sup>1</sup>

<sup>1</sup>Associate Professor, Department Of Forensic Medicine And Toxicology, Adichunchanagiri Institute Of Medical Sciences, Bg Nagara, Nagamangala Taluk, Mandya District

<sup>2</sup>Professor and Principal, Department Of Forensic Medicine And Toxicology, Adichunchanagiri Institute Of Medical Sciences, BG Nagara, Nagamangala Taluk, Mandya District

### Case Report

#### \*Corresponding author

Dr Vijay Kumar A G

#### Article History

Received: 25.09.2017

Accepted: 30.09.2017

Published: 30.10.2017



**Abstract:** Tubal ligation surgery is the mainstay of sterilization method in India. Every year over 4 million female sterilization operations are conducted across our country. In rural areas, the local bodies usually organize camps in collaboration with Department of Family Welfare of the Government at regular intervals for such procedure. On 23 May 2017 at around 9:00 am, a 28 year old female is said to have suffered cardiac arrest on table during laparoscopic tubectomy in a camp organized by local bodies in the limits of Thuruvekere PS. She was brought dead to the Casualty, AIMS Hospital. The deceased was subjected to autopsy after receiving the inquest from police. However minor vascular injuries are named so, but these are by no means minor in nature. Medical litigations can be minimised by adopting safe methods of laparoscopic entry and maintaining vigilance for early identification of missed intraoperative injury.

**Keywords:** Laporcopy, Tubal Ligation, air embolism, Sudden Death.

### INTRODUCTION

Tubal ligation surgery is the mainstay of sterilization method in India. Every year over 4 million female sterilization operations are conducted across our country. In rural areas, the local bodies usually organize camps in collaboration with Department of Family Welfare of the Government at regular intervals for such procedure [1,2]. Laparoscopic tubectomies are becoming more popular now days on account of lesser morbidity rates and reduced hospital stay. Although the absolute risk from laparoscopic surgery is low, if death occurs during such procedure it is inconsolable to the family and disastrous to the medical personnel [3,4].

### CASE-HISTORY

On 23 May 2017 at around 9:00 am, a 28 year old female is said to have suffered cardiac arrest on table during laparoscopic tubectomy in a camp organized by local bodies in the limits of Thuruvekere PS. She was brought dead to the Casualty, AIMS Hospital. The deceased was subjected to autopsy after receiving the inquest from police.

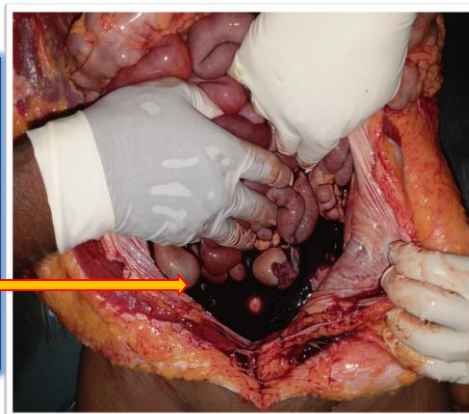
### SALIENT AUTOPSY FINDINGS

#### External examination

- Female aged 28 years,
- Moderately built and nourished,
- Post mortem staining present over back and was fixed,
- Rigor mortis appreciated all over.
- A surgical incised wound (port) measuring 1.5 cm x 0.5 cm x abdominal cavity deep present just below the umbilicus.

## Internal examination

- On opening abdominal-pelvic cavity, showed 600 ml of blood and blood clots.

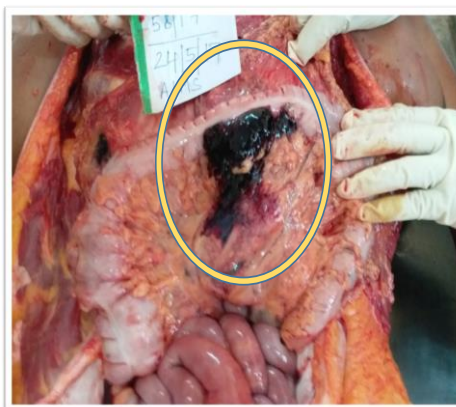


Photograph-1: Internal Examination

## Internal examination

Transverse meso-colon showing ante-mortem blood clots.

On further examination, injury to mesenteric vessels was noted on transverse mesocolon.



Photograph-2: Internal Examination

### Histopathological examination

- **Lungs: Edematous and congested, c/s** - intra alveolar and interstitial edema with alveolar microhemorrhages noted.
- **Uterus: endometrium** – Secretory phase
- **Cervix** – chronic polypoidal endocervicitis
- **Right ovary** – Multiple simple mucinous cyst with congestion
- **Other structures** – Unremarkable

After enquiry with the operating surgeon, anaesthetist along with scrutinizing of the records, it was

found that, the deceased suffered a sudden bradycardiac arrest with convulsions on table at the time of insufflation of air into the peritoneum (to create pneumoperitoneum) using veress needle. Patient could not be revived or stabilized in spite of best resuscitative efforts by on duty anaesthetist and surgeon, she succumbed. Initially anaphylaxis was suspected due to doctor convinced as he has made peri-umbilical incision only.

On post mortem, there was evidence of collection of blood in the peritoneum indicating the nick

in the vessel resulting in the probability of air entry into the circulation. Also at autopsy, the frothy fluid blood indicated more in favor of air embolism. Taking into account the clinical history, the post mortem findings and HPE report, an exact sequence of fatal events cannot be concluded on post mortem accurately, as there is divergence in clinical picture and with that of post mortem findings. It is a sort of paradox where opining about exact cause of death in such contrasting clinico-autopsy findings is very confusing and puzzling.

Differential causes of deaths on table during laparoscopic access

- Neurogenic shock,
- Air embolism,
- Anaphylaxis
- Major vascular injury or
- Combination of any of the above.

## DISCUSSION

**The laparoscopic entry techniques include**

- Closed method (**Veress technique**)
- Open method (Hasson) - the direct trocar insertion.

**Blind Veress needle insertion technique is the most widely used.**

Access into the abdomen is the one challenge of laparoscopy that is particular to the insertion of surgical instruments through small incisions.

In a prospective observational study of 5764 laparoscopic procedures, 57% of complications were caused only by laparoscopic access itself [4].

Risks of access are quoted as 0.4 per 1000 incidence of bowel injury and 0.2 per 1000 incidence of major vascular injury [4].

However major vascular injury is a much feared complication as because it is a major cause of death with a reported mortality rate of 15% compared to bowel injury (2.5-5%) [5].

Typically, it is believed that the hemodynamic compromise occurs due to a “gas lock” that occurs after high pressure insufflation [6].

Air embolism is a dramatic and often catastrophic complication of pneumoperitoneum.

Fortunately, its incidence is rare, but it occurs more frequently than the occasional reported in the literature would seem to indicate [7].

Hence, inadvertent intravenous placement of the Veress needle into open vessels and passage of air into abdominal cavity was considered as the likely

cause for the catastrophic event, even though there may not be conclusive findings on dissection of heart. So keeping in mind about above picture and past documented cases with statistics/studies, my opinion as to the cause of death would be on the following lines.

## FALLACIES AT CAMP

- **Inadequate pre- anaesthetic evaluation - Bowel preparation was not adequate – loaded transverse colon can sag even below to the level of umbilicus.**
- The probability of **Embolism** could have been avoided by using **CO2** which has high margin of safety and greater solubility.

## FALLACIES AT AUTOPSY

- **Pre-autopsy radiograph** could have been done.
- We could have used spirometer to collect air and to confirm the presence of air.

## CONCLUSION

However minor vascular injuries are named so, but these are by no means minor in nature. Medical litigations can be minimised by adopting safe methods of laparoscopic entry and maintaining vigilance for early identification of missed intraoperative injury. Proper pre anaesthetic evaluation, supported by surgical skills and good knowledge of the technology and instrumentation is the keystone to safe access and prevention of complications during laparoscopic surgery.

## REFERENCES

1. Knight B. Knights Forensic Pathology, 3<sup>rd</sup> Ed. UK. CRC press book. 2004. 347.
2. Kumar V, Abbas AK, Aster JC. Robbins Basic Pathology E-Book. Elsevier Health Sciences; 2017 Mar 8.
3. Reddy KSN. Essentials of forensic medicine. 34 ed. New Delhi. Jaypee. 2017.276.
4. Ahmed H. Risks of laproscopic surgery. Obs and Gyn Int. Journal. 2015;3(4);4-7
5. Krishnakumar S, Tambe P. Entry complications in laparoscopic surgery. Journal of gynecological endoscopy and surgery. 2009 Jan;1(1):4–11.
6. Dunn PF, Alston TA, Baker KH, Davison JK, Kwo J, Rosow CE. *Clinical Anesthesia Procedures of the Massachusetts General Hospital*. 7th ed. Philadelphia, PA: Lippincott Williams & Wilkins; 2007.348.
7. Trimble, HG, Wardrip BH. Pneumoperitoneum in Treatment of Pulmonary Tuberculosis, Am. Rev. Tuberc. 1937;3(6): 111-2.