

## Laparoscopic Management of Advanced Un-ruptured Caesarean Scar Ectopic Pregnancy

Bangal V.B<sup>1</sup>, Ghorpade N<sup>2</sup>, Mandade K<sup>3</sup>, Gavhane S<sup>4</sup>, Gamit R<sup>5</sup>

Department of Obstetrics and Gynaecology

Rural Medical College, Pravara Institute of Medical Sciences, Loni, India

### Case Report

\*Corresponding author

Bangal V.B

### Article History

Received: 04.10.2017

Accepted: 13.10.2017

Published: 30.10.2017



**Abstract:** The implantation of conceptus within previous caesarean section scar is the rare site of ectopic pregnancy. Early diagnosis and treatment can avoid life threatening complications and save the uterus and future reproductive career of woman. However, a delay in either diagnosis or treatment can lead to uterine rupture, hysterectomy, and significant maternal morbidity. A case of laparoscopic management of an advanced ectopic pregnancy in a previous Caesarean section scar is reported. A 23 year old woman was admitted to our hospital with pelvic supra-pubic pain following six months of caesarean section. Abdominal ultrasound revealed a bulging gestational sac over the lower anterior uterine wall measuring 8.4 X 7.3 X 8.9 cm. Diagnostic laparoscopy revealed bulging lower part of uterus with extreme vascularity and large tortuous vessels on the surface. Hysteroscopy revealed empty uterine cavity. Prophylactic bilateral uterine artery ligation was performed. An incision was made over the most prominent area of the mass by operative laparoscopy. A well formed fetus and placenta was removed from the anterior wall. Some placental bits could not be removed. Laparotomy was performed to secure hemostasis from the incision site and remove the adherent placenta. Two-layer of continuous sutures along the affected uterine wall was made with 1 vicryl. Surgical management enabled the successful treatment of an un-ruptured ectopic pregnancy in a previous Caesarean scar and made it possible to preserve the patient's reproductive capability.

**Keywords:** Caesarean Scar ectopic pregnancy, cervical ectopic pregnancy, Laparoscopic management of advanced scar ectopic pregnancy.

### INTRODUCTION

Caesarean section scar is the rarest site for development of ectopic pregnancies, and probably one of the most dangerous because of the risk of rupture and haemorrhage [1-3]. The possible mechanism for formation of scar site ectopic is entry of early conceptus into the myometrium through a microscopic tract. This tract may arise due to a previous Caesarean section, a previous dilatation and curettage, or due to adenomyosis[4-5]. It carries a high risk of uterine rupture and uncontrollable intra-peritoneal haemorrhage. Preoperative confirmation of diagnosis is difficult and hysterectomy is often required to control bleeding during operation.

### CASE REPORT

Twenty three year old, second gravida, uncooked case, referred from nearby town with history of three and half months amenorrhoea and suprapubic pain since eight days. She had undergone caesarean section six months back for eclampsia. She lost the baby four days

after due to complex congenital heart disease. She did not use any contraceptives following caesarean section and conceived spontaneously two months after caesarean section. There was no history of bleeding per vaginam or any urinary or bowel complaints. There was no history of nausea, vomiting, giddiness or syncope or trauma to abdomen. The pain was located in the supra-pubic region in the area of previous caesarean scar. Pain developed gradually and was intermittent and of moderate to severe intensity and at times unbearable to patient.

The obstetric ultrasound was performed in private clinic which revealed a live pregnancy of 14 weeks, located in the lower uterine segment in the region of previous caesarean scar. The upper part of uterine cavity was empty and there was fullness in the utero-vesical pouch with increased peripheral vascularity, with anterior location of placenta, raising suspicion of caesarean scar ectopic gestation.

Repeat ultrasound examination revealed similar findings with possibility of cervical pregnancy. Magnetic resonance imaging of pelvis revealed gravid uterus with endometrial thickness measuring 10mm. There was evidence of 8.4X7.3X8.9cm sized gestational sac and well-formed fetus within, in the region of the cervix. Placenta was located anteriorly. A thin continuous hypointense line was seen anterior to the placenta. Findings were suggestive of cervical pregnancy. Other pelvic organs were normal.

Patient and relatives were counseled about the condition, risk involved and the plan of management. Patient was posted for diagnostic laparoscopy and so laparotomy after adequate preoperative evaluation and arrangements of blood and components. Diagnostic laparoscopy revealed bulky uterus with a bulge on the lower part. There were big grossly engorged tortuous vessels on the lower part of uterus, indicating extreme vascularity. (Fig 1) It was decided to proceed with hysterotomy by laparoscopic route. Prophylactic bilateral uterine arteries were ligated at its origin. Gentle hysteroscopy was performed to visualize the uterine cavity and to differentiate between scar ectopic and cervical pregnancy. Hysteroscopy revealed bulge in the anterior cervico-isthmic region. Hysteroscope could be negotiated through cervical canal. The uterine cavity was found to be empty. These findings confirmed the diagnosis of scar ectopic and ruled out

the possibility of cervical pregnancy. Eight number lubricated Hegar's dilator was kept in the uterine cavity as a guide during next steps of surgery. Through laparoscope, a horizontal incision was made on the most prominent part of the bulge on the lower part of uterus after dissecting and separating the utero-vesical fold of peritoneum. A well formed 14 weeks fetus and placenta was removed through the incision. (Fig 2) The uterine or cervical cavity was not opened during this procedure. The Hegar's dilator served as a guide while removing the products of conception from ectopic site. Some part of placenta was adherent to the myometrium and thus could not be removed. Decision of laparotomy was taken to achieve complete hemostasis and removal of placenta as much as possible. The uterine incision was closed in two layers after achieving complete hemostasis. (Fig 3) Peritoneal drain was kept. The intra-operative blood loss was about 600-800 ml, following incision on the vascular lower segment. Prior ligation of uterine vessels helped in control of bleeding from the incision site. As patient's hemoglobin dropped to 7.5 grams in post operative period, two units of blood transfusion was given. The peritoneal drain was removed after 72 hours and patient was given injection methotrexate 60 mg, as some part of placental tissue was left in the myometrium. Patient was discharged from hospital on sixth post operative day and was counseled again about the need for contraception for minimum two years and need for regular follow up.

#### CLINICAL PHOTOGRAPHS

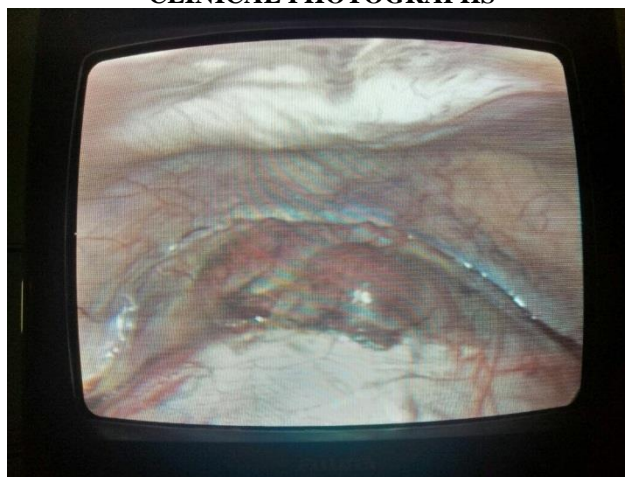
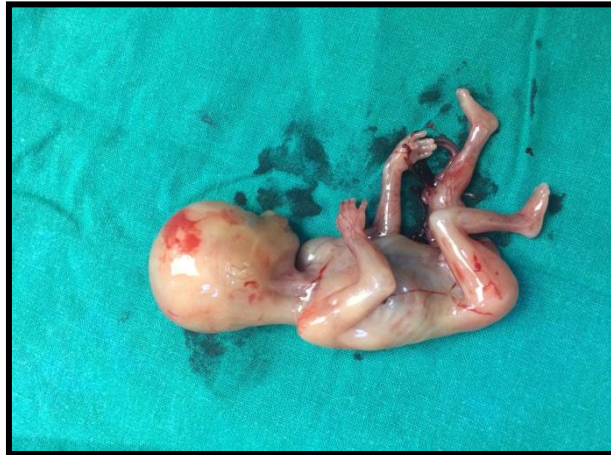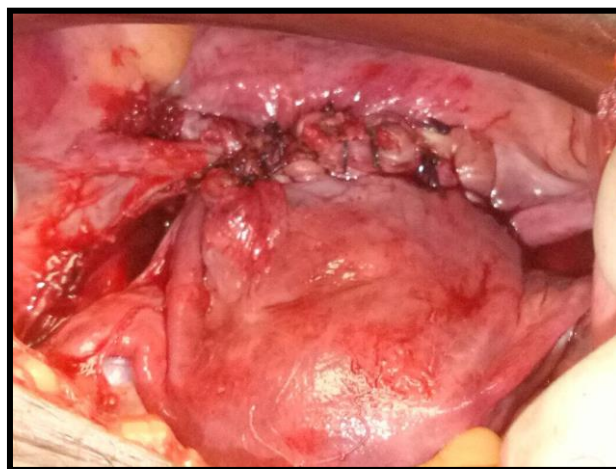


Fig-1: Showing laparoscopic view of scar ectopic site with engorged vessels



**Fig-2: Showing well developed (14 weeks) fetus after removal from scar ectopic site**



**Fig-3: Showing removal of ectopic gestation sac and suturing of uterine wall**

## DISCUSSION

Ectopic pregnancy is one of the important causes of mortality among women of reproductive age group. Common sites of ectopic gestations are fallopian tube, ampulla being the most common location. However, ectopic pregnancies are also known to occur in the cervix, ovary, previous caesarean scar, and abdomen. Intramural pregnancy with implantation in a previous caesarean section scar is probably the rarest location for ectopic pregnancy [6]. This type of pregnancy is prone for complications like uterine rupture, life-threatening haemorrhage, and hypovolemic shock [7-9].

Although the use of ultrasonography in the diagnosis of ectopic pregnancy is well established [10-11], differential diagnosis between spontaneous abortion in progress, cervico-isthmic pregnancy and ectopic pregnancy developing in a previous Caesarean section scar remains difficult. Magnetic resonance imaging helps in arrival of correct diagnosis. Direct visualization of ectopic site using endoscopic procedures confirms the diagnosis. In this case, hysteroscopy together with laparoscopy proved to be a

useful in differentiating between cervical pregnancy and scar ectopic pregnancy.

There is still a lack of information concerning the adequacy of management strategies for previous Caesarean section scar pregnancy including local injections of potassium chloride (KCl), methotrexate (MTX) or abdominal hysterectomy. The treatment needs to be individualized depending upon the women's parity, site of ectopic, and size of ectopic, duration of pregnancy, availability of blood bank and operation theatre facilities and availability of surgical expertise. In the present case, the endoscopic surgeon did prophylactic uterine artery ligation before opening the gestational sac by laparoscopic route. Laparotomies were required for better control the haemorrhage and remove the adherent placenta from ectopic gestation site. Patient recovered well and was discharged from hospital with proper counselling about contraception and careful monitoring of pregnancy at tertiary care hospital from very beginning.

## CONCLUSION

Caesarean section scar ectopic is a rare but life threatening condition. Early diagnosis is possible by first trimester obstetric ultrasonography. Condition is either managed by medical methods using methotrexate or by surgical methods. Non recognition or late detection can result into spontaneous rupture of ectopic gestation and torrential intra-peritoneal bleeding. Condition needs to be differentiated from cervical pregnancy or inevitable abortion. Magnetic resonance imaging can help in confirmation of diagnosis. Surgical management requires expertise and institutional set up, as there is likelihood of severe life threatening haemorrhage during surgery and need for either pelvic vessel ligation or hysterectomy and massive blood transfusion. In the present case, the gestation was quite advanced. Part of the surgical management could be done by laparoscopic route. Laparotomy was needed to achieve hemostasis and remove the adherent placenta from the ectopic site.

## REFERENCES

1. Fait G, Goyert G, Sundareson A, Pickens Jr A. Intramural pregnancy with fetal survival: case history and discussion of etiologic factors. *Obstetrics & Gynecology*. 1987 Sep 1;70(3):472-4.
2. Timor-Tritsch IE, Monteagudo A, Mandeville EO, Peisner DB, Anaya GP, Pirrone EC. Successful management of viable cervical pregnancy by local injection of methotrexate guided by transvaginal ultrasonography. *American journal of obstetrics and gynecology*. 1994 Mar 31;170(3):737-9.
3. Atri M, Leduc C, Gillett P, Bret PM, Reinhold C, Kintzen G, Aldis AE, Thibodeau M. Role of endovaginal sonography in the diagnosis and management of ectopic pregnancy. *Radiographics*. 1996 Jul;16(4):755-74.
4. Abbott J, Roe J, Budenholzer B, Scaletta T, Kaplan B, Salzberg M, Kendig J, Howard F, Janas J, Carson S, Buster J. Ectopic Pregnancy. Authors'reply. *The New England Journal Of Medicine*. 1994;330(10):712-4.
5. De Meerssche MV, Verdonk P, Jacquemyn Y, Serreyn R, Gerris J. Cervical pregnancy: three case reports and a review of the literature. *Human Reproduction*. 1995 Jul 1;10(7):1850-5.
6. Fylstra DL, Pound-Chang T, Miller MG, Cooper A, Miller KM. Ectopic pregnancy within a cesarean delivery scar: a case report. *American journal of obstetrics and gynecology*. 2002 Aug 31;187(2):302-4.
7. Herman A, Weinraub Z, Avrech O, Maymon R, Ron-El R, Bukovsky Y. Follow up and outcome of isthmic pregnancy located in a previous caesarean section scar. *BJOG: An International Journal of Obstetrics & Gynaecology*. 1995 Oct 1;102(10):839-41.
8. Fylstra DL. Ectopic pregnancy within a cesarean scar: a review. *Obstetrical & gynecological survey*. 2002 Aug 1;57(8):537-43.
9. Jurkovic D, Hillaby K, Woelfer B, Lawrence A, Salim R, Elson CJ. First-trimester diagnosis and management of pregnancies implanted into the lower uterine segment Cesarean section scar. *Ultrasound in obstetrics & gynecology*. 2003 Mar 1;21(3):220-7.
10. Brown DL, Doubilet PM. Transvaginal sonography for diagnosing ectopic pregnancy: positivity criteria and performance characteristics. *Journal of ultrasound in medicine*. 1994 Apr 1;13(4):259-66.
11. Cava EF, Russell WM. Intramural pregnancy with uterine rupture: a case report. *American journal of obstetrics and gynecology*. 1978 May 15;131(2):214-6.