

## Pancreatic Lipoma: A Case Report and Review of Literature

Dr Sanjib Kumar Das, Dr Ipsita Acharya, Dr Jayashree Mohanty, Dr sasmita parida, Dr Basanta Manjari Swain

Dept of Radiodiagnosis SCB Medical College, Cuttack (Utkal University)

### Case Report

#### \*Corresponding author

Dr Ipsita Acharya

#### Article History

Received: 16.10.2017

Accepted: 25.10.2017

Published: 30.10.2017



**Abstract:** Pancreatic lipomas are mostly incidentally detected when patient undergoes imaging studies for some other reason. Uncommonly, they can present with nonspecific symptoms like abdominal pain or features of pancreatic or biliary obstruction. Pathologically, the lipomas are benign lesions made up of mature fat cells surrounded by a thin collagenous capsule. We present a case of pancreatic lipoma incidentally detected in a 65 yr female patient complaining of swelling in right iliac fossa many years after appendicectomy which turned out to be an incisional hernia.

**Keywords:** Pancreatic tumors, Lipoma

### INTRODUCTION

Pancreatic tumours can be of epithelial, non-ductal or mesenchymal origin. While epithelial tumors constitute majority of the pancreatic tumors accounting for about 85% of the cases, the non-ductal tumors account for only 5- 15%. The mesenchymal tumors constitute only 1% of the pancreatic tumours [1,2].

Pancreatic lipoma and liposarcoma are rare mesenchymal tumors of the pancreas. In 1969, Bigard described the first ever reported case of pancreatic lipoma on sonography as a hypoechoic mass in the head of pancreas which was latter histologically confirmed as lipoma [3]. In 1993, a case of incidentally detected pancreatic tail lipoma was described by Boglino *et al.* in an 11-month child. De jong *et al.* reported a case of pancreatic head lipoma in 1993 which was associated with elevated serum bilirubin and alkaline phosphatase level due to the obstruction of the common bile duct[4].

Since then many studies have been conducted to study the pancreatic lipomas using different modalities. In 1980, Elliot *et al.* described a case of large epigastric mass detected on plain abdominal radiographs which was later histopathologically proved as pleomorphic pancreatic liposarcoma [5]. In 1998, Katz *et al.* conducted a retrospective study and described 4 cases of pancreatic lipoma and concluded that CT appearance of these lesions are diagnostic and these lesions only require conservative management if these are incidentally detected and do not cause any obstruction of the biliary or pancreatic duct [4]. Legman *et al.* described the characteristics of pancreatic lipoma on CT [6]. Itai *et al.* in 1995 studied 5 cases of pancreatic lipoma on sonography and CT[8]. In 2006, Di Matteo *et al.* described a case of pancreatic lipoma diagnosed on endoscopic ultrasound [7]. In 2012, Stadnik *et al.* described CT and MRI features of 13 cases of pancreatic lipoma [9].

Thereafter, a series of studies were conducted to study the incidence of pancreatic lipoma. In 2006, Hois *et al.* found only 5 cases of pancreatic lipoma (0.083%) of 6000 analysed CT scans. Xu *et al.* in 2008 reported only one case of pancreatic lipoma (0.59%) out of 169 cases of protruding lesions of lipoma confirming the rarity of lipoma [10]. However, in 2014 Gossner reported 6 such cases out of 100 reviewed abdominal CT scans contraindicating the rarity of the lipomas and stating that pancreatic lipomas are not rare as previously thought [11]. Pancreatic lipomas are mostly incidentally detected when patient undergoes imaging studies for some other reason. Uncommonly, they can present with nonspecific symptoms like abdominal pain or features of pancreatic or biliary obstruction.

### CASE REPORT

A 65 yrs old female patient presented to our department with complaints of swelling in right iliac fossa. History of surgery was present for appendicitis when she was 35 yrs old, though we could not get any

documented evidence. There was no history of pain. Bowel habit was normal. There was no history of any medication other than PPIs. We did an ultrasound to find out a ventral hernia with herniating bowel loops. Incidentally we took note of a hypoechoic mass lesion in the head of pancreas (fig.1). Upon repeated asking,

we could not collect any complaints of any pancreatic pathology. We advised a CT scan to look for the lesion. CECT scan revealed a hypodense lesion in pancreatic head and uncinata process showing fat attenuation without any soft tissue component (fig.2). A diagnosis of pancreatic lipoma was given.

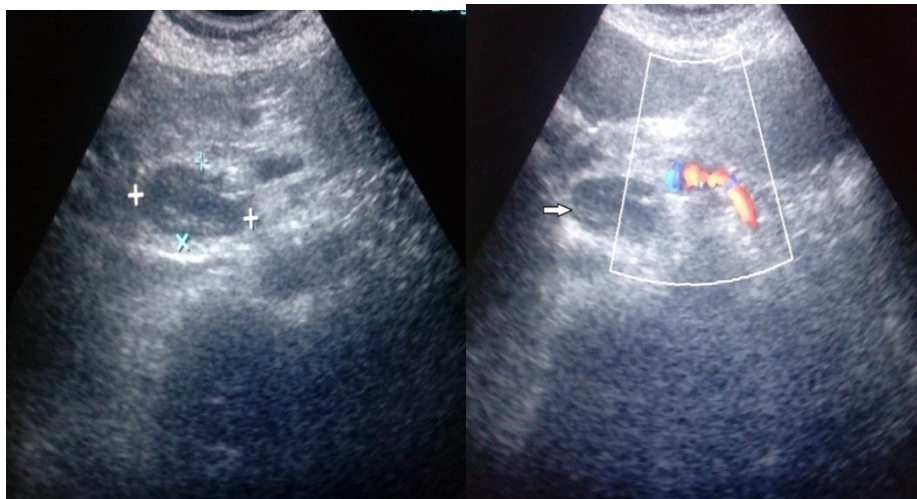


Fig-1: Ultrasonography images showing a well-defined hypoechoic lesion in pancreatic head.

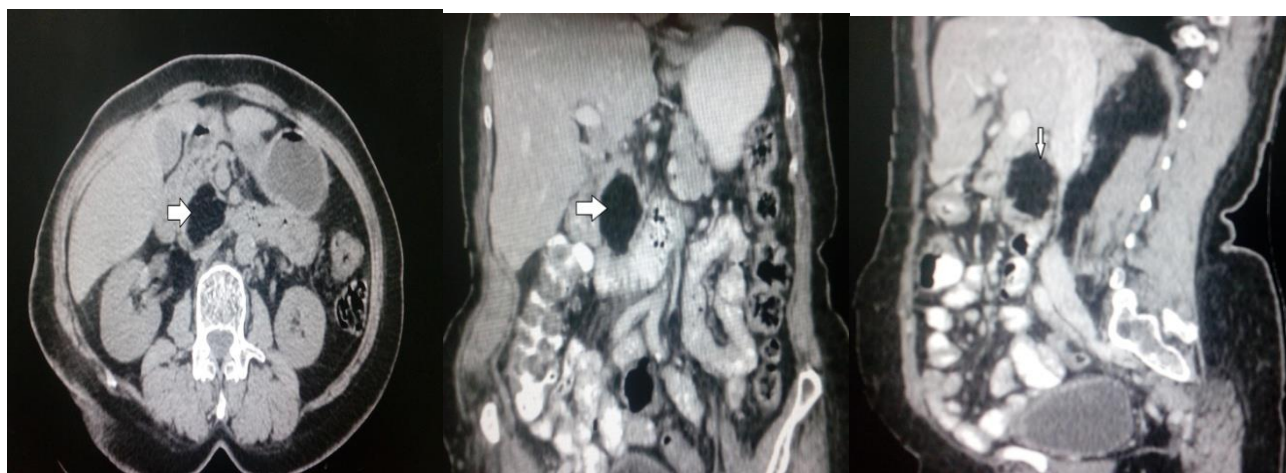


Fig-2: CECT image in axial, coronal and sagittal view showing a hypodense lesion of fat attenuation in pancreatic head and uncinata process.

## DISCUSSION

Pathologically, the lipomas are benign lesions made up of mature fat cells surrounded by a thin collagenous capsule. On ultrasound, these lesions usually appear hyperechoic but sometimes can appear hypoechoic, thus can be confused with pancreatic mass [12]. CECT shows well-margined homogenous non-enhancing low density lesion (-80 to -120 HU). On MRI evaluation, pancreatic lipomas appear as well defined lobulated lesions that show T1 and T2 hyperintensity with suppression of signal on fat suppressed images [10, 12]. Being benign lesions, these usually do not require any treatment and are managed conservatively. These may require resection when they are large in size

and cause obstructive features or significant mass effect.

The differentials of pancreatic lipoma include focal fatty infiltration of pancreas, liposarcoma and pancreatic teratoma. Focal fatty infiltration and pancreatic lipoma may appear similar but focal fatty replacement appears heterogenous with ill-defined margins and may show faint inhomogenous contrast enhancement. They also lack the well-defined capsule of lipomas. Differentiation between liposarcoma and lipoma is necessary as liposarcomas require surgery whereas lipomas do not. Liposarcomas are usually larger (>5cm, mostly >10cm), heterogenous with solid

enhancing components and infiltration into adjacent structures. Teratoma of pancreas is very rare. They contain fat, solid components, calcifications [9, 10, 12].

#### CONCLUSION

Pancreatic lipomas are benign tumors, which are often asymptomatic and do not need treatment. Ultrasound may sometimes be confusing due to varied appearance. It may appear hypoechoic relative to echogenic pancreas leading to suspicion of malignancy. CT scan should be done to confirm the diagnosis.

#### REFERENCES

1. Barutcu O, Cihangiroglu M, Yildirim T et al. Fat containing unusual tumor of the pancreas. *Eur Radiol* 2002; 12:770–73.
2. Raut CP, Fernandez-del CC. Giant lipoma of the pancreas. Case report and review of lipomatous lesions of the pancreas. *Pancreas* 2003; 26:97-9.
3. Bigard MA, Boissel P, Regent D, Froment N. Intrapancreatic lipoma: first case in the literature. *Gastroenterol Clin Biol* 1989; 13:505-507
4. Katz DS, Nardi PM, Hines J, Barckhausen R, Math KR, Fruauff AA, Lane MJ. Lipomas of the pancreas. *AJR. American journal of roentgenology*. 1998 Jun;170(6):1485-7.
5. Elliott TE, Albertazzi VJ, Danto LA. Pancreatic liposarcoma: case report with review of retroperitoneal liposarcomas. *Cancer*. 1980;45:1720–1723.
6. Baert AL. *Radiology of the Pancreas*. Springer Science & Business Media; 1999.
7. Di Matteo FM, Shimpi L, Pandolfi M, Rabitti C, Fabio C, Gabbrielli A, Costamagna G. EUS diagnosis of pancreatic lipoma: a case report. *Gastrointestinal endoscopy*. 2006 Jul 1;64(1):146-8.
8. Itai Y, Saida Y, Kurosaki Y, Kurosaki A, Fujimoto T. Focal fatty masses of the pancreas. *Acta Radiologica*. 1995 Mar;36(2):178-81.
9. Stadnik A, Cieszanowski A, Bakoń L, Grodzicka A, Rowiński O. Pancreatic lipoma: An incidentaloma which can resemble cancer—analysis of 13 cases studied with CT and MRI. *Polish journal of radiology*. 2012 Jul;77(3):9.
10. Aithal SS, Bashini M, Gunasekaran K, Barathi SD. Pancreatic lipoma: a pancreatic incidentaloma; diagnosis with ultrasound, computed tomography and magnetic resonance imaging. *BJR Case Rep* 2016; 2: 20150507.
11. Gossner J. Pancreatic Lipomas—Prevalence in Patients Undergoing Abdominal CT. *Polish journal of radiology*. 2014;79:259.
12. Meena BK. Rare Case of Pancreatic Lipoma Diagnosed Incidentally on CT scan and Its Review of Literature. *Meena, J Clin Case Rep* 2013, 3:10