

Facial Asymmetry with Unilateral Condylar Hyperplasia – Three Case Reports With Review of Literature

Dr. Saraswathi Gopal K* MDS¹, Dr. Harsha Vardhan B.G, MDS², Dr. Aarthi S Lankupalli, MDS³, Dr. Padma M

¹Professor and Head, Department of Oral Medicine and Radiology, Meenakshi Ammal Dental College, Chennai, India

²Professor, Department of Oral Medicine and Radiology, Meenakshi Ammal Dental College, Chennai, India

³Reader, Department of Oral Medicine and Radiology, Meenakshi Ammal Dental College, Chennai, India

⁴Post graduate student, Department of Oral Medicine and Radiology, Meenakshi Ammal Dental College, Chennai, India

Case Report

*Corresponding author

Dr. Saraswathi Gopal K

Article History

Received: 02.03.2018

Accepted: 14.03.2018

Published: 30.04.2018

DOI:

10.21276/sjds.2018.5.4.4



Abstract: Condylar hyperplasia is a complex deformity of temporomandibular joint which involves excessive growth of condyle. Asymmetric facial deformity (AFD) is one of the consequences of condylar hyperplasia, which may often cause an alteration of the dental occlusion with unilateral crossbite or open bite. It affects more commonly women in adolescence age group, although it does not discriminate by age or gender. There are two types of condylar hyperplasia, horizontal and vertical growth. Correct diagnosis is critical in determining the proper treatment plan. This article highlights on case reports of unilateral condylar hyperplasia in three patients and the diagnosis was made on clinical presentation and radiographic interpretation.

Keywords: Facial asymmetry, Hyperplasia, Unilateral, Mandibular condyle, Temporomandibular joint, adolescence, investigations.

INTRODUCTION

Condylar hyperplasia is an uncommon malformation of the mandible, created by excessive growth of one of the condyles [1]. Condylar hyperplasia is characterized by hypertrophy of the head and/or the neck of the condyle with hyperactivity of one, but rarely both, of the mandibular condyles. It is linked to uncontrolled pre-chondroblastic cellular activity at the head and/or neck of the condyle. Condylar overgrowth manifests itself differently according to whether it is expressed vertically or transversely.

Thus one can describe two very different clinical scenarios:

- Condylar hyperplasia with vertical growth;
- Condylar hyperplasia with transverse growth [2].

Condylar hyperplasia with vertical growth

Asymmetry of the lower one-third of the face resulting from condylar hyperplasia presents as excessive vertical height on the affected side, a canting of the mandibular plane of occlusion on the same side that is responsible for a general infraocclusion compensated by eruption of the affected dento-alveolar sectors. Adaptive alteration of the maxilla is a secondary compensation of the skeletal deformation.

elongation of the mandibular neck resulting in facial asymmetry and shifting of the midline of the chin to the unaffected side. The aetiology of condylar hyperplasia is controversial and not well understood. Suggested theories for etiology include neoplasia, trauma, response to infection, abnormal loading, partial hemihypertrophy, arthrosis, osteochondromatosis, local circulatory disturbances, and neurotrophic disturbances [3].

Condylar hyperplasia with transverse growth

Facial Asymmetry manifests itself essentially by a lateral shift of the chin. Expression of the chin in vertical hyperplasia is conversely weak to non-existent. Dento-alveolar compensations are more transverse than vertical: the arches are skewed

Condylar hyperplasia is observed more frequently in female than male. Association between sexual hormones and condylar growth could be the reason for women predilection. Young adults as well as subjects over 50 years can exhibit condylar hyperplasia in progress. The severity of the asymmetry was also associated with age and gender of the patient; the type of condylar deformity may present as horizontal in 53%, vertical in 31% and combined in 16% of cases[4]. Histological examination reveals overactivity in

articular cartilage, increased thickness of proliferative zone and hypertrophic fibrocartilagenous zone. Endochondreal bone formation occurs with intact articular zone [5]. Here we are describing in detail three case reports of patients with three different clinical manifestations of condylar hyperplasia.

CASE REPORT-1

A fourteen year old male patient reported to the department of Oral Medicine and Radiology with a chief complaint of deviation of lower jaw towards left side. History revealed that the patient first noticed the problem one year back, and associated with difficulty while chewing food on right side (Fig 1-4). His medical and surgical history was non-contributory. Intraoral On local examination, inspection revealed the deviation of the lower jaw towards the left side on opening, closing and at rest. On palpation, tenderness present on right TMJ and click sound felt on left TMJ region. On auscultation crepitus heard on left TMJ. With the given history and clinical findings we arrived at a provisional diagnosis of internal derangement with reduction of Left TMJ and a differential diagnosis of right side

condylar hyperplasia. Routine radiographic investigation OPG orthopantomogram (Fig-5) revealed bifid right condylar head and condylar neck is thicker in right side and appear elongated. The posterior border of the ramus and condylar neck has a posterior inclination, enlarged mandibular ramus and body of the mandible and shift in midline of the mandible towards left side. TMJ tomogram (Fig-6) reveals bifid right condylar head. PA view (Fig-7) of skull reveals shift in mandibular midline towards left side. Computed tomography sagittal image (Fig-8a & b) of mandible showed bifid condyle on the right side. Bone scintigraphy (Fig 9) was taken for functional imaging which showed features that are compatible with persistence of active bone growth in the Condylar process of right mandible. The pattern of tracer uptake in the left mandible appears to be within normal limits. These findings are negative for metastatic bone disease. Under general anesthesia Right side condylectomy was performed and immediate post op image after one week (Fig 10) was recorded, followed by orthodontic fixed appliance therapy for treating the malocclusion.

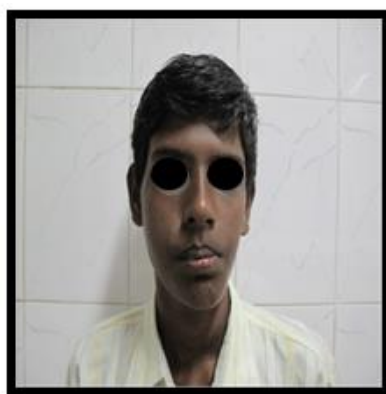

Fig-1: Patient Profile

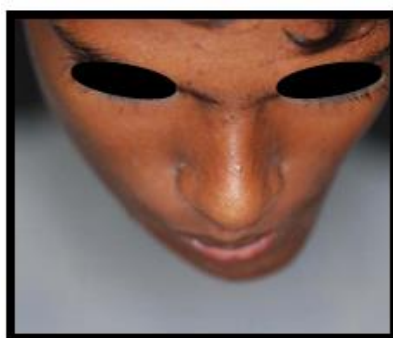

Fig-2: Superior View Profile

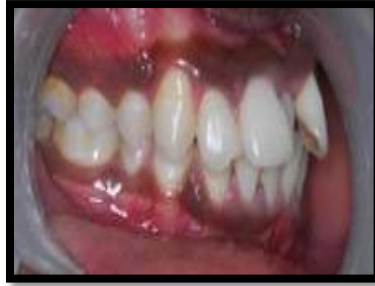

Fig-3: Intra Oral – Right Side

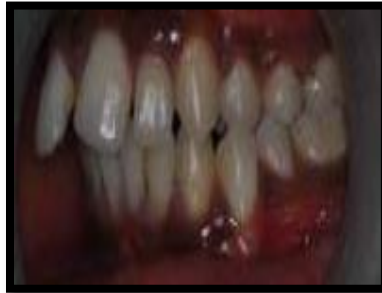

Fig-4: Intra Oral– Left Side

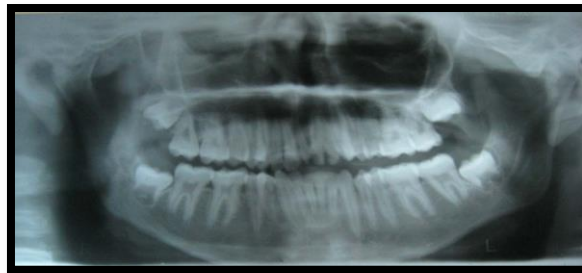

Fig-5: OPG reveals bifid right condylar head and shift in midline of the mandible

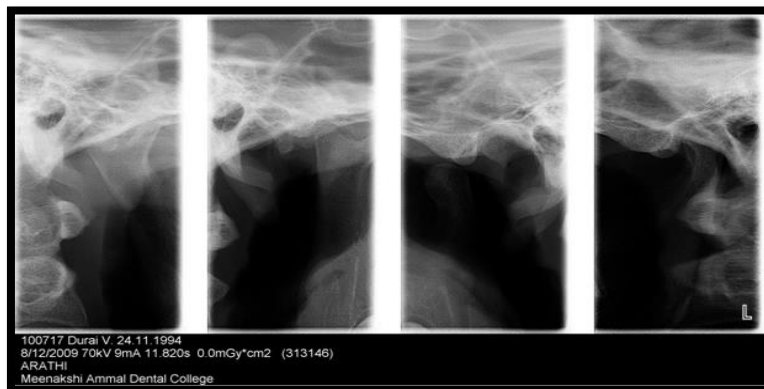


Fig-6: TMJ tomogram reveals bifid right condylar head with normal gliding movements towards left side

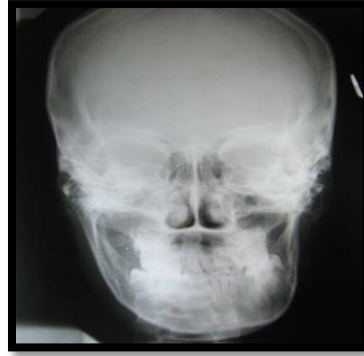

Fig-7: AP skull radiograph reveals shift in mandibular midline towards left side.

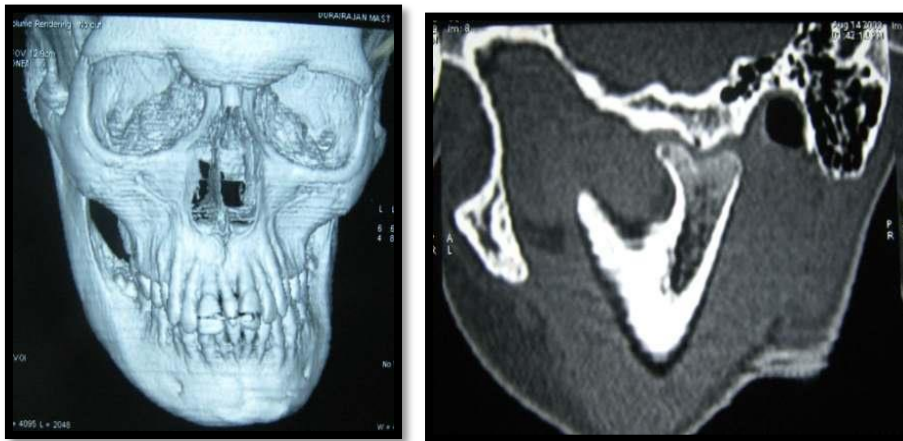


Fig-8a & b: Computed tomography of mandible showed bifid condyle on the right side

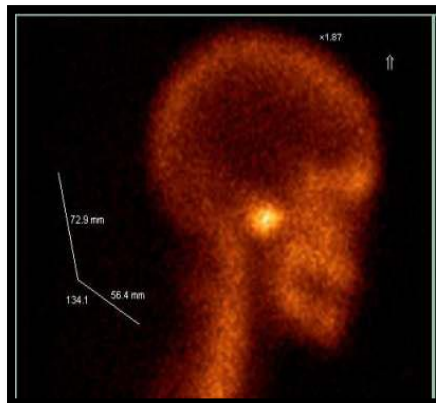


Fig- 9: Bone scintigraphy the pattern of tracer uptake in the left hemimandible appears to be within normal limits. These findings are negative for metastatic bone disease.

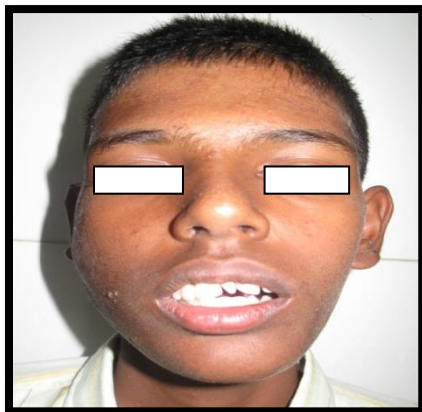


Fig-10: post-surgical image

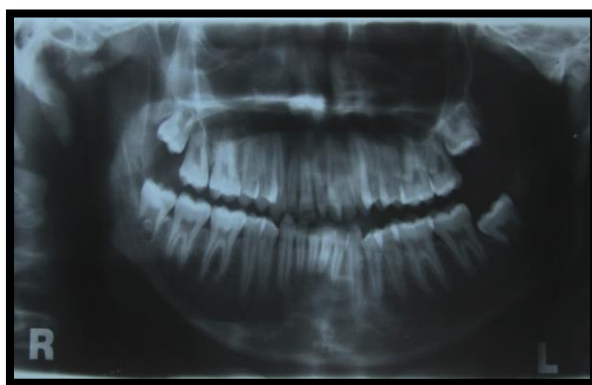


Fig-11: post-surgical OPG image

CASE 2

A fifteen year old female patient reported to the department of Oral Medicine & Radiology with a chief complaint of facial asymmetry and deviation of lower jaw towards right side for past 2years (Fig-11,12). Patient consulted a dentist 6 months before for similar complaint. Her medical and surgical history was non-contributory. There is no H/O associated discomfort on chewing food. On local examination, the deviation of the lower jaw towards the right side on opening, closing and at rest and prominent chin in right side. On palpation, no tenderness is evident in TMJ region. On auscultation click heard on closing the right side of TMJ. Intra oral hard tissue examination revealed Angle's class I molar relation on right side and class III molar relation on left side, midline shift in lower arch towards right side , microdontia of 12, cross bite in relation to 13 and 43 (Fig-13,14,&15). With the given history and clinical findings we arrived at a

provisional diagnosis left side condylar hyperplasia. Patient was subjected to routine radiographic investigation of Orthopantomogram (Fig-16) revealed the condylar neck is thicker in left side and appear elongated. Temporomandibular joint tomogram (Fig-17) shows clearly visualizing the enlarged condyle and elongated condylar neck on the left side. PA skull radiograph (Fig-18) showed condylar hyperplasia with vertical growth. The structural analysis shows the vertical asymmetry of the angles of the mandible. 3-D cone beam computed tomography images (Fig-19a,b,c) also showed enlarged condylar head with round shape in left side , and increased intercondylar distance, increased ramus height in left side, whereas right side showed normal condylar and ramus morphology. Patient is under orthodontic correction of the teeth and later will be advised for surgical correction of the elongated condyle after completion of the growth phase.

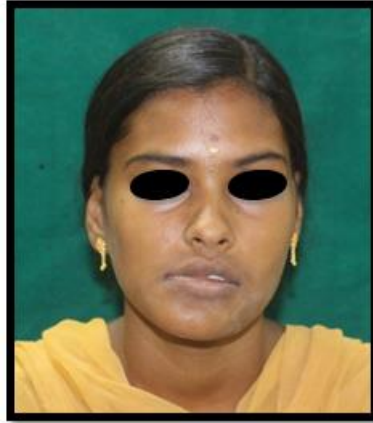

Fig-11: patient profile

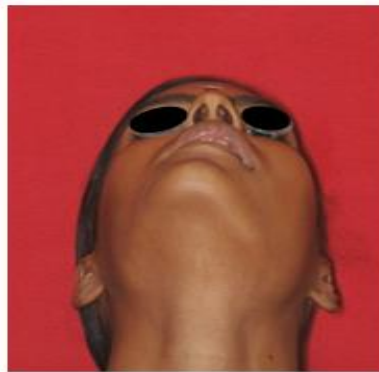

Fig-12: Submental view

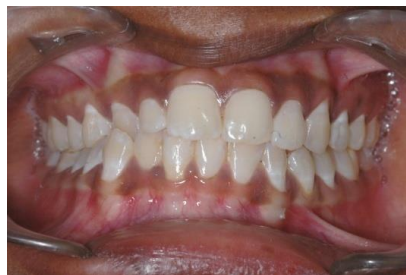

Fig 13: intra oral view

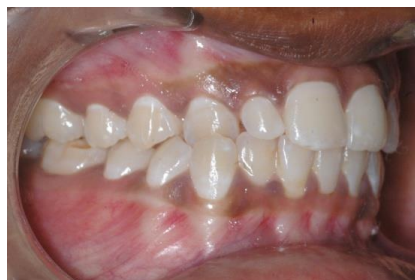

Fig-14: right lateral occlusion

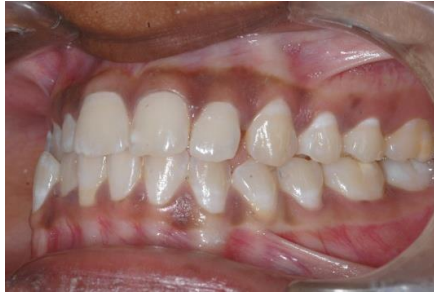

Fig-15: left lateral occlusion

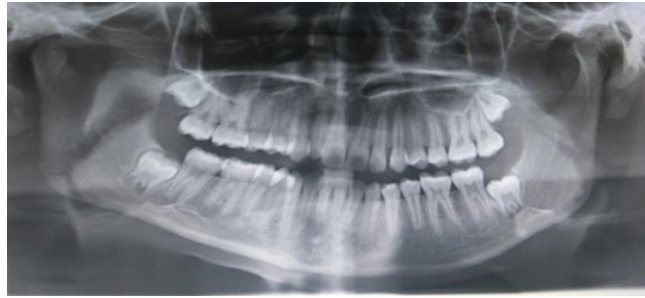


Fig-16: orthopantamogram

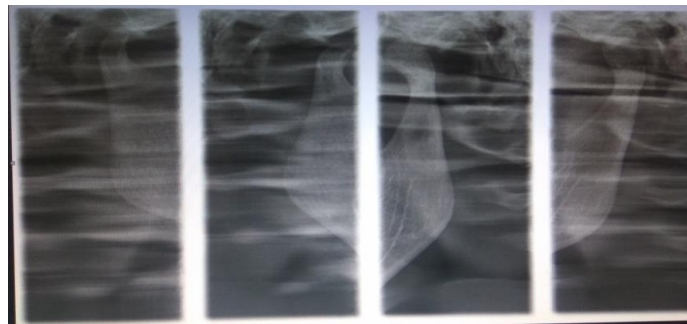


Fig-17: tMJ tomogram

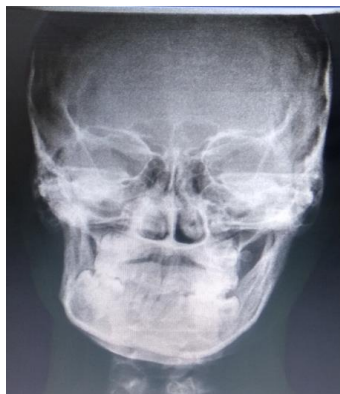

Fig-18: PA skull Radiograph

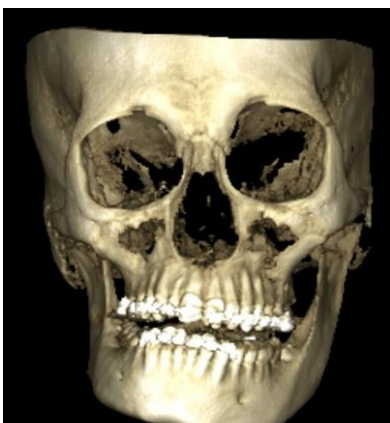

Fig-19a: CBCT -3D reconstructed image

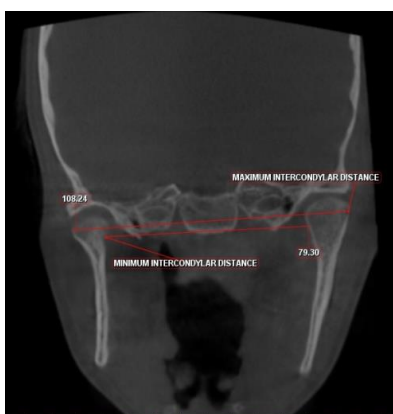


Fig-19b: CBCT Coronal image

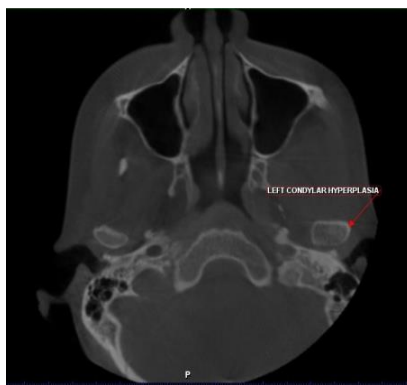


Fig-19c: CBCT Axial image

CASE REPORT 3

A 40 year old male patient reported to the Department of Oral Medicine and Radiology with a chief complaint of difficulty in closing the mouth for past 2 months. History revealed that patient had episodes of difficulty in mouth closure during yawning which is associated with pain around the right TMJ region (Fig-20). Patient gave a history of similar episodes of pain 5 years ago and he consulted a dental surgeon for which he was given an occlusal splint. Patient also gave H/O hearing click sounds on Right TMJ region, H/O dislocation of the Right TMJ on opening the mouth wide and inability to chew the food on right side. Intra oral examination revealed open bite

in right side and normal occlusion on right side (Fig-21, 22) and TMJ examination based on the research diagnostic criteria for screening and examination of TMJ revealed restricted mouth opening of 20mm, relatively normal protrusive and lateral excursion movements. Deviation of mouth is present towards right side during closure of mouth. Clicking sound was heard during opening and closing of mouth on palpation and auscultating the Right TMJ. Tenderness present during palpation and on loading the TMJ. On palpation of muscles of mastication pain was elicited in the right lateral pterygoid muscle insertion region. Mandibular tests of provocation revealed pain on opening against resistance. Anterior disc dislocation without reduction

on right side of TMJ was considered as a provisional diagnosis based on the history and clinical examination. Radiographic investigations that included orthopantomogram, TMJ tomogram and CBCT of the jaws covering the TMJ region were performed. Orthopantomograph (Fig-24) revealed thickened and elongated condylar neck on the right side. Elongation of styloid processes was evident on both the right and left sides. TMJ tomogram (Fig-23) revealed that the right condylar head is flattened and is positioned at the eminence during closed position and presence of right

condylar head beyond the eminence during opening suggestive of hypermobility of right condyle and internal derangement of right TMJ. 3-D cone beam computed tomography images (Fig-25a & 25b) was performed which showed enlarged condylar head with round shape in right side, and increased intercondylar distance, increased ramus height in right side. From the investigations a final diagnosis of condylar hyperplasia of right side was given. Patient was instructed for undergoing surgical management of shapening of the condyles.

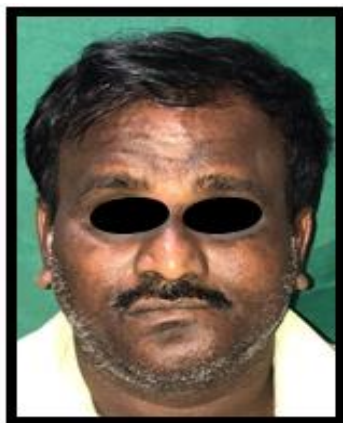

Fig-20: Patient profile

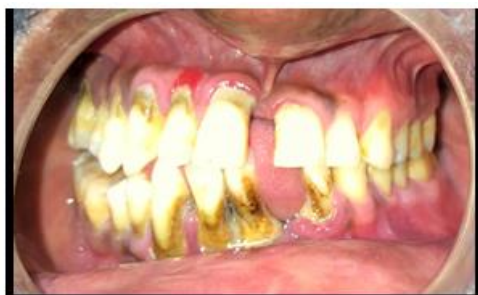

Fig-21: Intra oral image

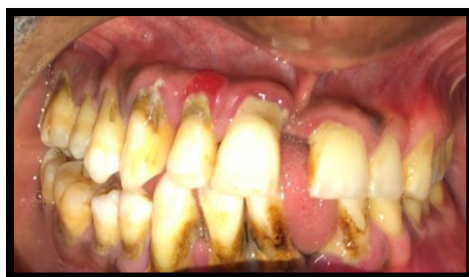

Fig-22: Right lateral occlusion

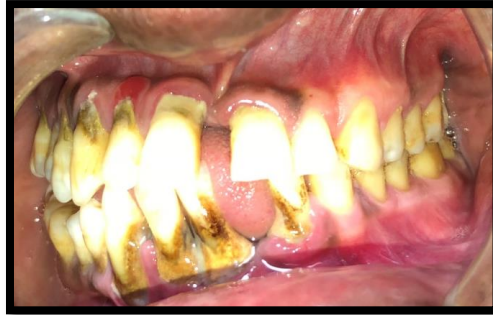

Fig-23: Left lateral occlusion

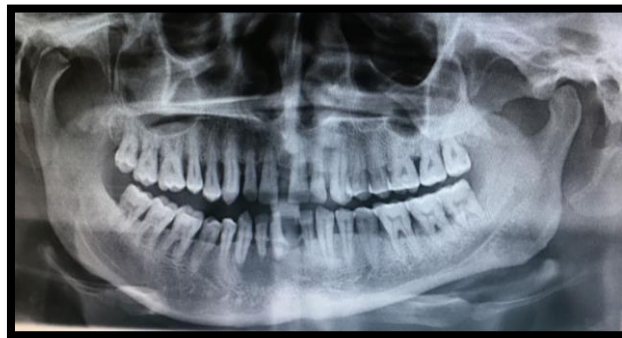

Fig-24: Orthopantomogram image

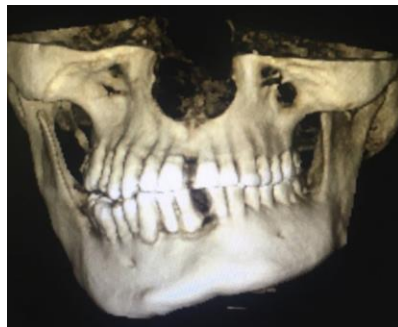

Fig-25a: 3D CBCT – Reconstructed Image

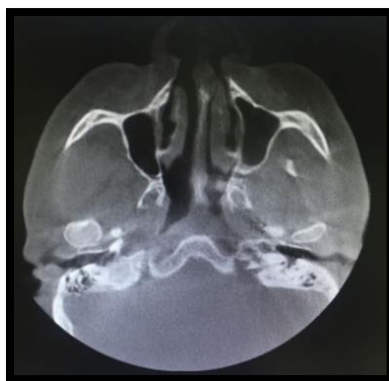


Fig-25b: Coronal CBCT image

DISCUSSION

Condylar hyperplasia has been described as a rare unilateral growth of the mandibular condyle. This growth causes both functional and esthetic problems, which often manifest as facial asymmetry, occlusal

interferences, and joint dysfunction that can lead to pain. Excessive growth can occur in several different locations in the mandible. The growth can be the result of an enlarged condyle, an elongated condylar neck, or outward bowing or downward growth of the body and

ramus. Due to the variations in locations of excessive growth, multiple classification systems have been developed to better characterize the pathology.

Asymmetric conditions attributed to condylar hyperplasia of the mandible were first reported by Adams in 1836. Gottlieb described condylar hyperplasia as an osteoma causing unilateral deformity and prognathic deviation subsequent to a bilateral disproportion in the size of the condyles [5].

The aetiology and pathogenesis of condylar hyperplasia is unknown. Some of them include previous trauma, true neoplasia, hormonal disturbances, partial hemihypertrophy, arthrosis, osteochondromatosis, local circulatory disturbances, and neurotrophic disturbances [6]. Other condition which can cause challenges in diagnosing this condition includes hemifacial hyperplasia but in this condition, the associated soft tissues and teeth also will be enlarged which was absent in all our cases also. Condylar hyperplasia usually occurs after puberty and is completed by 18 to 25 years. Prominent features of condylar hyperplasia include an enlarged mandibular condyle, elongated condylar neck, outward bowing and downward growth of the body, and ramus of the mandible on the affected side, causing fullness of the face on that side and flattening of the face on the contralateral side. The prominence of the chin is shifted to the unaffected side [2].

The condylar growth varies according to period of growth:

- During the pubertal growth spurt. – Abnormal hypermetabolic growth centre in the affected condyle.
- End of puberty – Growth in one condyle persists into adulthood.

At an early stage occlusal contact is maintained by increased vertical height of the dentoalveolar structures in both the upper and lower jaws. This results in slanting of the occlusal plane towards the affected side. When the downward growth of mandible continues further it exceeds the dentoalveolar growth potential and produces an open bite in the premolar and molar regions on the abnormal side. This depends, on one hand, on the rate of increasing enlargement of condyle and, on the other hand, the downward growth of the maxillary alveolus and teeth.

Many classifications were considered for categorization of different intensities and clinical presentations of condylar hyperplasia.

Obwegeser and Makek classification [7] was based on the asymmetry and predominant growth vector and was tabulated as follows:

Type I – Hemimandibular elongation: Chin deviation towards contralateral side, midline shift to contralateral

side, Lingual deviation of contralateral mandibular incisors and possible posterior cross bite.

Type II – Hemimandibular hyperplasia: Sloping rima oris with minimal chin deviation, supraeruption of maxillary molars on affected side, possible open bite and no midline shift.

Type III – Combination of Type I and Type II: Chin deviation towards contralateral side with a sloping rima oris, midline shift, possible open bite and / or cross bite.

Among the reported cases with the above classification under consideration, case 1 falls under type 1, case 2 belongs to type 3 whereas case 3 is of type 2 category.

Second classification by Wolford *et al.*, [8] developed an updated classification system that they considered more inclusive of pathologies causing Condylar hyperplasia. Their report classifies Condylar hyperplasia into four different categories based on clinical, imaging, growth, and histological characteristics. This system was developed to classify Condylar hyperplasia into more specific types in order to provide optimal treatment to patients based on their specific disease characteristics.

In this system, Type 1 and 2 CH are similar to the classification system developed by Obwegeser and Makek with the following exceptions. Type 1 is characterized by an accelerated and prolonged growth that causes condylar and mandibular elongation and split into 1A and 1B. CH Type 1A is defined as mandibular elongation that occurs bilaterally, while Condylar hyperplasia Type 1B occurs unilaterally. CH Type 2 consists of unilateral overgrowth of the condyle caused by an osteochondroma and results in vertical overgrowth of the mandible.

Wolford *et al.*, further classified CH Type 2 into A and B. Type 2A results from vertical elongation of the condylar head and neck. Type 2B involves horizontal exophytic tumor growth of the condyle in addition to vertical elongation of the head and neck. CH Type 3 consists of other benign tumors that cause Condylar hyperplasia, including but not limited to osteomas, neurofibromas, and fibrous dysplasia, and results in unilateral facial enlargement. Type 4 CH is caused by malignant tumors that originate in the condyle and cause enlargement and facial asymmetry. Some malignant tumors attributed to Type 4 CH include chondrosarcoma, multiple myeloma, osteosarcoma, and Ewing sarcoma.

CH type 1A is the most commonly occurring and CH type 4 is the rarest form. Since there were no signs of tumor occurrence in all the above reported cases a categorization into type 1A was contrived.

Third classification: According to Slootweg and Muller [9] based on histological findings as were

among the first to create a histological classification system based on a study they conducted in 1986, in which they classified 22 patients into four categories based on histological findings in various layers of hyperplastic condyles. Specifically, they analyzed the fibrous articular layer, the undifferentiated mesenchymal layer, the transitional layer, and the hypertrophic cartilage layer and characterized each layer based on histological findings.

CH Type 1 displayed a broad proliferation zone with an underlying thick layer of hyaline growth cartilage and bone that contained numerous cartilage islands.

CH Type 2 demonstrated a patchier distribution of proliferation zones with a smaller number of cartilage islands.

CH Type 3 was characterized by irregular-shaped masses of cartilage found in the bone of the condylar neck or encroaching onto the superficial articular layer. Type 3 displayed great distortion compared to the histological findings of normal condyles.

Type 4 CH was commonly characterized by a burned-out appearance of the condyle due to a very cell-poor fibrocartilaginous layer covering the subchondral bone plate. Sloopweg and Muller also noted that Type 4 CH did not demonstrate a proliferation layer of the hyaline growth cartilage like that seen in the other types.

Diagnosis and treatment modalities

Various methods are available for the diagnosis of Condylar hyperplasia. Correct diagnosis of Condylar hyperplasia is essential when deciding how to treat the condition. To prevent post-surgical reversion, accurate diagnosis of Condylar hyperplasia activity is also of utmost importance. Diagnostic methods such as clinical examination, radiographs, and nuclear imaging can be used to determine the type of Condylar hyperplasia as well as its activity. Clinical diagnosis has been described as the diagnostic gold standard. Radiographically, the condyle may appear relatively normal but symmetrically enlarged, or it may be altered in shape (e.g., conical, spherical, elongated, lobulated) or irregular in outline. It may appear more radiopaque because of additional bone present. A morphologic variation like elongation of the condylar head and neck may be seen. The ramus and mandibular body on the affected side also may be enlarged [10]. In the present cases, all three patients had the similar features mentioned above.

Nuclear imaging is capable of providing physiological details of Condylar hyperplasia using radionuclide-labeled tracers. Examples of different types of nuclear imaging include planar scintigraphy, single-photon emission computed tomography (SPECT) and PET. SPECT and planar scintigraphy utilize the radio nucleotide technetium-99m labelled methylene diphosphonate (99mTc-MDP), while PET utilizes the

radio nucleotide [18F]-fluoride. Prior to the development of 99mTc-MDP, [18 F]-fluoride was the standard radio nucleotide tracer for SPECT. Planar scintigraphy produces a two-dimensional image, as opposed to SPECT and PET, which produce three dimensional images. Bone scintigraphy has high sensitivity and low specificity for bone metabolism, that it can identify when a change in bone metabolism is present but is limited in its ability to differentiate among various conditions (e.g., bone healing, growth, infection, arthritic changes, or tumors) [11]. Generally when condyles are being evaluated with bone scintigraphy, a difference in uptake levels of less than 10% indicates either normal condyles or individuals without progressive asymmetry. Scintiscanning is useful for three reasons, it is possible to determine which side is affected, it becomes evident whether there is an abnormal condylar growth centre or whether there is generalized mandibular growth, and finally, it is apparent whether or not the hyperplasia is still active or if it has become stable [12].

Combined treatment modality is indicated during growth phase, which included fixed orthodontic management and surgical procedure. Condylectomy on the affected side is the accepted method of treatment because as long it remains active- asymmetry progresses with worsening occlusal harmony [13]. It gives the best possible result with little post-operative discomfort to the patient.

BIFID condyle

It is a rare developmental anomaly characterized by a double-headed mandibular condyle. Most bifid condyles have a medial and lateral head divided by an anteroposterior groove. Some condyles may be divided into an anterior and posterior head. The etiology of bifid condyle is due largely unknown, although various factors have been suggested as possible causes: endocrine disturbances, exposure to teratogens, nutritional deficiencies, infection and radiation, trauma, abnormal lateral pterygoid muscle attachment, persistence of fibrous septum within the condylar cartilage etc. It is mostly asymptomatic and identified as an incidental finding, and does not require emergent management [10]. If associated with hyperplasia, condylectomy is performed as in our case I.

CONCLUSION

Condylar hyperplasia requires a thorough examination and diagnostic tools to accurately diagnose and treat. Patients often seek treatment due to facial asymmetry and resulting esthetic problems. Additional investigation is needed to establish a more standardized approach for diagnosing the activity of Condylar hyperplasia. Clinical examination, radiography, planar scintigraphy, SPECT, and PET are all diagnostic methods that can be utilized by clinicians when planning surgery. Long term follow-up of the patients

must be needed to determine which treatment options are the most successful.

REFERENCES

1. Neville B, Damm DD, Allen CM, Bouquot J. N, Ille BW. Oral and Maxillo facial pathology. 2nd ed. Philadelphia: WB Saunders. 2001:544-6.
2. Cervelli V, Bottini DJ, Arpino A, Trimarco A, Cervelli G, Mugnaini F. Hypercondylia: problems in diagnosis and therapeutic indications. Journal of Craniofacial Surgery. 2008 Mar 1;19(2):406-10.
3. Gray RJ, Sloan P, Quayle AA, Carter DH. Histopathological and scintigraphic features of condylar hyperplasia. International journal of oral and maxillofacial surgery. 1990 Apr 1;19(2):65-71.
4. Olate S, Netto HD, Rodriguez-Chessa J, Alister JP, de Albergaria-Barbosa J, de Moraes M. Mandible condylar hyperplasia: a review of diagnosis and treatment protocol. International journal of clinical and experimental medicine. 2013;6(9):727.
5. Vela Desai PP, Sharma R. Condylar Hyperplasia: A Rare Case Report; 2013.
6. Slootweg PJ, Müller H. Condylar hyperplasia. A clinico-pathological analysis of 22 cases. Journal of maxillofacial surgery. 1986 Jan 1;14:209-14.
7. Obwegeser HL, Makek MS. Hemimandibular hyperplasia-- hemimandibular elongation. J Maxillofac Surg 1986;14:183-208.
8. Wolford LM, Movahed R, Perez DE. A classification system for conditions causing condylar hyperplasia. J Oral Maxillofac Surg 2014;72:567-95.
9. Slootweg PJ, Muller H. Condylar hyperplasia. A clinico-pathological analysis of 22 cases. J Maxillofac Surg 1986;14:209-14.
10. White & Pharoah. Text book oral radiology, Principles and interpretation, First south Asia Edition edition; 2014; 499-500.
11. Gray RJ, Sloan P, Quayle AA, Carter DH. Histopathological and scintigraphic features of condylar hyperplasia. International journal of oral and maxillofacial surgery. 1990 Apr 1;19(2):65-71.
12. Bharathi SC, Senthilnathan S, Kumar LD, Mohan AC, Taranth M. Unilateral condylar hyperplasia: A case report and review of literature. J Int Soc Prev Community Dent 2014;4(1):67-70.
13. Gombra V, Mushtaq A, Kaur M. Facial asymmetry and unilateral condylar hyperplasia-a case report. Annals of dental specialty. 2015 Oct 1;3(4):110-2.