

Adenocarcinoma of the Bladder: A Case Report and Review of the Literature

A. Sabiq^{1*}, F. Z. Ballouk¹, M. Bennan I¹, N. Kadri¹, A. Agouzal¹, I. Zaytoun¹, S. Kandri Rody¹, M. Darfaoui¹, A. El Omrani¹, M. Khouchani¹

¹Oncology-Radiotherapy Department, Oncology-Hematology Center, CHU Mohammed VI Marrakech, Morocco

DOI: [10.36347/sjmcr.2022.v10i03.016](https://doi.org/10.36347/sjmcr.2022.v10i03.016)

| Received: 27.01.2022 | Accepted: 03.03.2022 | Published: 17.03.2022

*Corresponding author: A. Sabiq

Oncology-Radiotherapy Department, Oncology-Hematology Center, CHU Mohammed VI Marrakech, Morocco

Abstract

Case Report

Primary bladder adenocarcinoma (PBA) is a rare entity representing 0.5 to 2% of all bladder malignancies. The clinical symptomatology: is not specific, the treatment is essentially surgical, chemotherapy and radiotherapy are discussed. For some authors, concomitant chemoradiotherapy seems to be promising for infiltrating tumors of the bladder. The evolution is often rapidly progressive and fatal. We report a case of primary adenocarcinoma of the bladder who consulted the department of Oncology-Radiotherapy UHC Mohammed VI Marrakech because of the rarity of these tumors and a review of the literature.

Keywords: bladder malignancies, Primary bladder adenocarcinoma (PBA), chemoradiotherapy.

Copyright © 2022 The Author(s): This is an open-access article distributed under the terms of the Creative Commons Attribution 4.0 International License (CC BY-NC 4.0) which permits unrestricted use, distribution, and reproduction in any medium for non-commercial use provided the original author and source are credited.

INTRODUCTION

Bladder cancer is the 2nd most common cancer of the urogenital tract after prostate cancer. Its incidence is estimated at 336,000 cases per year or 5.3% of all cancers). The most frequent histological type is transitional urothelial carcinoma representing 90-95% of bladder malignancies. Non-urothelial tumors of the bladder are much rarer and represent less than 5% of all bladder neoplasms, including primary bladder adenocarcinoma (PKA) which represents the 3rd most common cancer after urothelial carcinoma and squamous cell carcinoma. It is a rare entity that represents 0.5 to 2% of all bladder malignancies. It occurs most often in men (sex ratio of 3/1), between the 5th and 6th decade. Despite their low incidence, urologists should consider them in the presence of any bladder tumor, especially those with an unusual clinical presentation. We report a case of primary adenocarcinoma of the bladder who consulted the department of Oncology-Radiotherapy UHC Mohammed VI Marrakech because of the rarity of these tumors and a review of the literature.

OBSERVATION

The patient was 61 years old, a chronic smoker with 24 BP and no other specific pathological history. who consulted for macroscopic hematuria, urinary

burning and pollakiuria. The examination found a patient PS: 2, flexible abdomen with palpation of a firm hypogastric mass, the lumbar fossae are free, TR: without particularity, the ganglion areas are free, the rest of the clinical examination is without particularity.

The abdominal-pelvic CT scan (Fig 1 & 2) showed irregular parietal thickening of the posterolateral walls and floor, measuring 15 mm in maximum thickness with infiltration of pelvic fat and mesorectum, multiple visible adenopathies at the bilateral external and internal iliac level, at the lumbo-aortic level, inter aortico-cavity and retro-cavity of which the most voluminous measured 18*15mm. The patient underwent RTUV, the histological examination showed a urothelial-like mucosa associated with glandular parenchyma which are infiltrating carcinomatous proliferation. (Fig 3 & 4) then we completed by immunohistochemistry which showed: AB anti-GATA3+; AB anti CK 20 -; AB anti-PSA-; AB anti CK7+. In total it is a morphological and IHC aspect of moderately differentiated and infiltrating bladder ADK.

The extension workup (thoracic CT scan; bone scan) showed secondary bone and liver involvement with associated peritoneal carcinosis. A 5-fluorouracil-

based chemotherapy was proposed as palliative treatment.

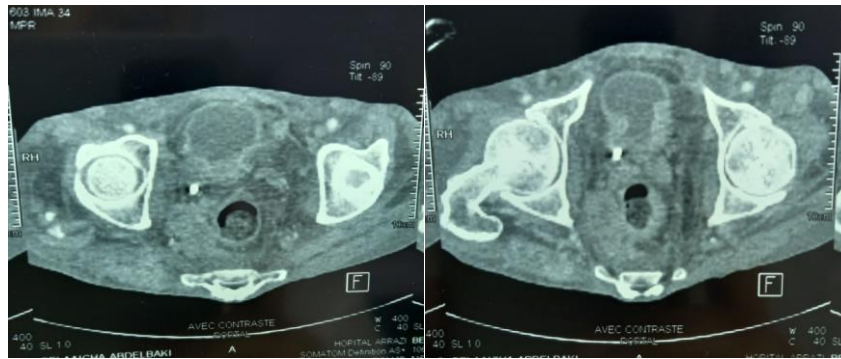


Fig 1 & 2: Pelvic CT axial section: irregular parietal thickening of the posterolateral walls and floor, measuring 15 mm maximum thickness with infiltration of the pelvic fat and mesorectum, multiple visible adenopathies at the bilateral external and internal iliac level, at the lumbosacral level of which the most voluminous measures 18*15mm

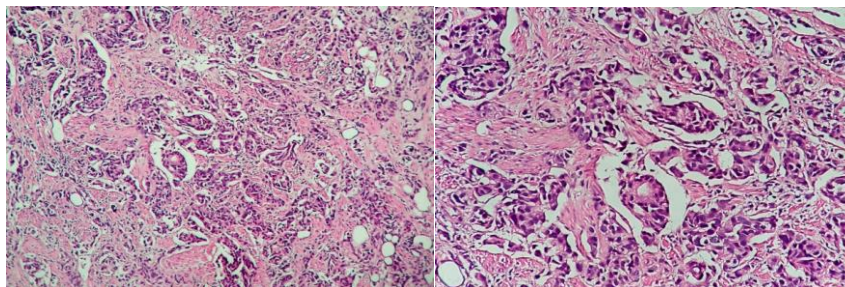


Fig 3 & 4: Microscopy: urothelial-like mucosa associated with glandular parenchyma which are infiltrating carcinomatous proliferation

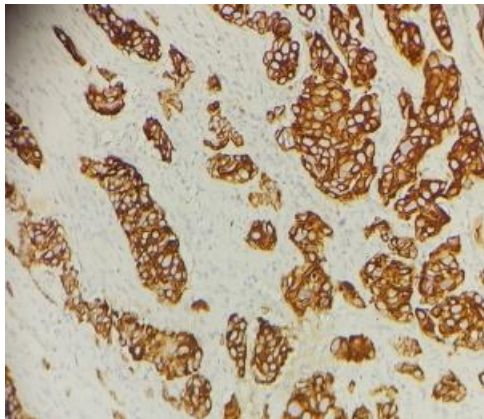


Fig 5: Intense and diffuse cytoplasmic and membrane expression of anti CK7

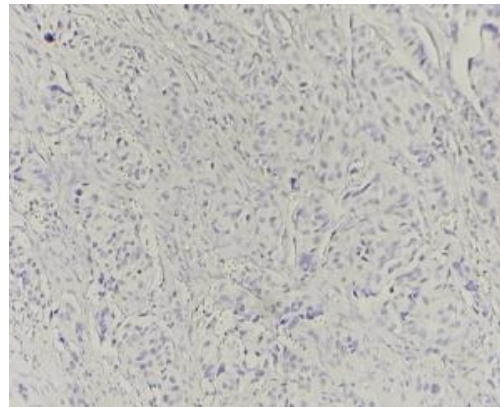


Fig 7: Moderate to intense and diffuse nuclear expression of anti-GATA3 AC in tumor cells

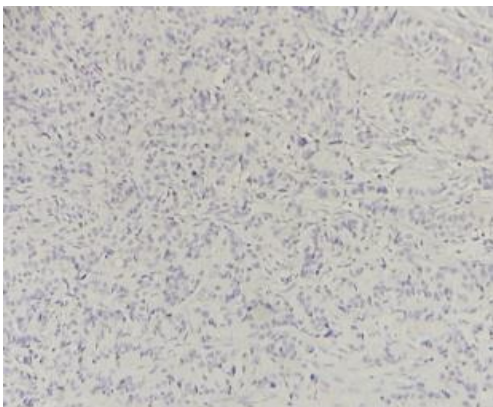


Fig 6: A lack of tumor cell expression of anti CK 20

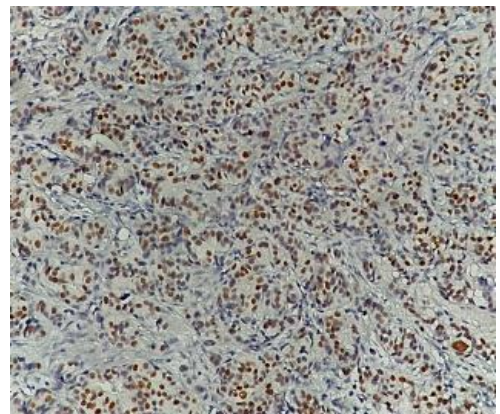


Fig 8: Une absence d'expression des cellules tumorales de AC anti PSA

DISCUSSION

Primary bladder adenocarcinomas represent only 0.5-2% of all primary malignancies of the bladder [5]. The mean age at diagnosis is 70 years with extremes of 38 to 83 years, a clear male predominance has been reported in most series [9, 10].

Primary bladder adenocarcinoma is classified into hemorrhagic and non-hemorrhagic adenocarcinoma. Differentiation between these two types is based mainly on clinical and morphological criteria, as the immunohistochemical phenotype is mostly uninformative and superimposable [12]. Urca adenocarcinoma often develops in the posterior wall of the bladder or bladder dome from remnants of the uracula, its epicenter is in the bladder muscle and tends to spread to the space of Retzius forming a suprapubic mass. It often presents with dotted calcifications that may be identified on uroscanner [11]. While the non-uracic form often develops in the base of the bladder from metaplasia of the urothelium [8].

The etiopathogeny of this tumor remains hypothetical and highly controversial. Its development within an epithelium normally devoid of any glandular structure has given rise to many theories, the metaplastic theory seems to unite the majority of authors, and derives its originality from the metaplastic power of the urothelial lining of the bladder [13], which occurs under the effect of mechanical or chemical irritating factors [7, 8, 14]. Support for this mechanism comes from cases occurring in patients with diffuse intestinal metaplasia of the bladder mucosa associated with obstruction, cystocele, neurologic bladder, bladder exstrophy, enterocystoplasty, or chronic irritation (chronic infections and inflammations) [15, 16]. In case of renal transplantation, the incidence of this type of tumor increases, and the age at the time of their occurrence decreases, which is explained by the immunosuppressive treatments used [17]. However, this tumor could also develop from pluripotent epithelial cells [18]. Histologically, this lesion is characterized by tumor lesions forming a glandular structure that resembles colonic adenocarcinoma (Figure 2). Grignon classified primary non-helical adenocarcinoma of the bladder into 6 histologic types [8]: Enteric ADK, mucinous (colloid) ADK, kitten-ring cell ADK, clear cell (mesonephric) ADK, mixed ADK and undifferentiated ADK. The clinical symptomatology of adenocarcinoma is not specific and differs little from that of urothelial carcinoma, dominated by macroscopic hematuria which is the most common clinical presentation, other symptoms have been reported such as dysuria, pollakiuria, incontinence or urinary retention [9].

On cystoscopy, bladder adenocarcinoma most often presents as a single lesion unlike urothelial carcinoma which tends to be multifocal and most often

localizes to the trigone and posterior wall as a papillary, solid, or ulcerated lesion, but any other location is possible [19]. The RTUV with the histological study allows to establish the positive diagnosis, based on the presence of independent cells or grouped in clusters, with eccentric nucleus repressed by a vacuole of secretion positive to the PAS or alcian blue stains. On immunohistochemical study, there is immunoreactivity for epithelial markers, including antibodies to cytokeratin (CK), epithelial membrane antigen (EMA) and less frequently carcinoembryonic antigen (CEA) [20], the negativity of PSA and placental alkaline phosphatase (PAP) allow the elimination of a prostatic origin [20]. One cannot conclude to a primary bladder tumor without excluding a secondary localization of a digestive or prostate cancer extended to the bladder [20, 21].

On the paraclinical level, thoraco-abdomino-pelvic computed tomography (CT) is essential to evaluate the locoregional tumor extension, the impact on the upper urinary tract and to determine the metastatic extension. Urine cytology and the search for mucosuria are positive in 20% of cases. Despite the number of therapeutic modalities used in the various publications, treatment is essentially surgical and consists of an early radical cystectomy that is as complete as possible [20], chemotherapy and radiotherapy are discussed [9, 22]. For some authors, concomitant chemoradiotherapy seems to be promising for infiltrating tumors of the bladder [23]. The evolution is often rapidly progressive and fatal, and is marked by frequent recurrences with locoregional or distant extension; indeed, the median survival time reported in the literature is 20 months [10].

CONCLUSION

Primary adenocarcinoma of the bladder is a rare tumor with a poor prognosis that presents a diagnostic and therapeutic challenge and requires concerted efforts by multiple medical disciplines to establish an effective treatment strategy and improve prognosis. Primary adenocarcinoma of the bladder is a rare tumor with a poor prognosis that presents a diagnostic and therapeutic challenge and requires concerted efforts by multiple medical disciplines to establish an effective treatment strategy and improve prognosis. Despite their low incidence, urologists should consider them in the presence of any bladder tumor, especially those with an unusual clinical presentation.

REFERENCE

1. Sherai, T. (2001). Etiology of bladder cancer *seiurol*, 11(3), 113-126.
2. Chopin, D., & Gratingo, B. (2001). Epidémiologie description des tumeurs superficielles de la vessie Programme urologique, 11, 953-960.

3. Lopez-Beltran, A. (2008). Bladder cancer: clinical and pathological profile. *Scandinavian journal of urology and nephrology*, 42(sup218), 95-109.
4. Kadouri, Y., Hachem, F., Lakssir, J., Sayegh, H., Benslimane, L., & Nouini, Y. (2020). Primitive adenocarcinoma of the bladder: about 6 cases. *The Pan African Medical Journal*, 36, 61-61.
5. Thomas, D. G., Ward, A. M., Path, M. R. C., & Williams, J. L. (1971). A study of 52 cases of adenocarcinoma of the bladder. *British Journal of Urology*, 43(1), 4-15.
6. Bennett, J. K., Wheatley, J. K., & Walton, K. N. (1984). 10-year experience with adenocarcinoma of the bladder. *The Journal of urology*, 131(2), 262-263.
7. Debbagh, A., Bennani, S., Hafiani, M., El Mrini, M., & Benjelloun, S. (2000, February). Primary adenocarcinoma of the bladder: report of a case. In *Annales D'urologie*, 34(1), 20-27.
8. Grignon, D. J., Ro, J. Y., Ayala, A. G., Johnson, D. E., & Ordóñez, N. G. (1991). Primary adenocarcinoma of the urinary bladder. A clinicopathologic analysis of 72 cases. *Cancer*, 67(8), 2165-2172.
9. Bernstein, S. A., Reuter, V. E., Carroll, P. R., & Whitmore Jr, W. F. (1988). Primary signet ring cell carcinoma of urinary bladder. *Urology*, 31(5), 432-436.
10. Torenbeek, R., Koot, R. A. C., Blomjous, C. E. M., De Bruin, P. C., Newling, D. W. W., & Meijer, C. J. L. M. (1996). Primary signet-ring cell carcinoma of the urinary bladder. *Histopathology*, 28(1), 33-40.
11. Brick, S. H., Friedman, A. C., Pollack, H. M., Fishman, E. K., Radecki, P. D., Siegelbaum, M. H., ... & Caroline, D. F. (1988). Urachal carcinoma: CT findings. *Radiology*, 169(2), 377-381.
12. Gopalan, A., Sharp, D. S., Fine, S. W., Tickoo, S. K., Herr, H. W., Reuter, V. E., & Olgac, S. (2009). Urachal carcinoma: a clinicopathologic analysis of 24 cases with outcome correlation. *The American journal of surgical pathology*, 33(5), 659.
13. El-Bolkainy, M., Mokhtar, N. M., Ghoneim, M. A., & Hussein, M. H. (1981). The impact of schistosomiasis on the pathology of bladder carcinoma. *Cancer*, 48(12), 2643-2648.
14. FJ, E. S., JL, A. M., Aramburu, L., & JM, U. A. (1991). Bladder adenocarcinoma. Presentation of 3 new cases. *Archivos Espanoles de Urologia*, 44(2), 141-143.
15. Filmer, R. B., & Spencer, J. R. (1990). Malignancies in bladder augmentations and intestinal conduits. *The Journal of urology*, 143(4), 671-678.
16. Culp, D. A. (1964). The histology of the exstrophied bladder. *The Journal of Urology*, 91(5), 538-548.
17. Anderström, C., Johansson, S. L., & von Schultz, L. (1983). Primary adenocarcinoma of the urinary bladder. A clinicopathologic and prognostic study. *Cancer*, 52(7), 1273-1280.
18. Ducarme, G., Bryckaert, P. E., Brandt, B., Durlach, A., & Staerman, F. (2003). Primary adenocarcinoma of the bladder and renal transplantation. *Progres en Urologie: Journal de L'association Francaise D'urologie et de la Societe Francaise D'urologie*, 13(4), 690-692.
19. Roy, S., Smith, M. A., Cieply, K. M., Acquafondata, M. B., & Parwani, A. V. (2012). Primary bladder adenocarcinoma versus metastatic colorectal adenocarcinoma: a persisting diagnostic challenge. *Diagnostic Pathology*, 7(1), 1-9.
20. Lesourd, A., Joerg, A., Ollier, P., & Le Duc, A. (1996). Un cas d'adénocarcinome primitif de la vessie à cellules en bague à châton. *Archives d'anatomie et de cytologie pathologiques*, 44(5-6), 278-281.
21. Smith, C., Feddersen, R. M., Dressler, L., McConnell, T., Milroy, M., & Smith, A. Y. (1994). Signet ring cell adenocarcinoma of prostate. *Urology*, 43(3), 397-400.
22. Fiter, L., Gimeno, F., Martin, L., & Tejada, L. G. (1993). Signet ring cell adenocarcinoma of bladder. *Urology*, 41(1), 30-33.
23. Housset, M. (1998). Chimioradiothérapie concomitante des cancers infiltrants de la vessie. *Cancer/Radiothérapie*, 2(6), 713-717.