

Lisfranc Injury: Medial Columellar Dislocation M1C1 Associated with a Fracture of the 2nd and 3rd Metatarsal in a Young Soccer Player

Hassan Zeddouk^{1*}, Yassine Saadi¹, Moncef Boufettal¹, Rida-Allah Bassir¹, Mohamed Kharmaz¹, Mohamed Saleh Berrada¹, Fekhaoui Mohammed Reda¹

¹Orthopaedic Surgery & Traumatology, University Mohamed V, Ibn Sina Hospital, Rabat, Morocco

DOI: <https://doi.org/10.36347/sjmcr.2025.v13i01.023>

| Received: 11.04.2024 | Accepted: 14.05.2024 | Published: 15.01.2025

*Corresponding author: Hassan Zeddouk

Orthopaedic Surgery & Traumatology, University Mohamed V, Ibn Sina Hospital, Rabat, Morocco

Abstract

Case Report

Representing only .2% of all fractures, Lisfranc injuries are rare and uncommon. High energy accidents as well as low energy accidents can cause them, and can go from a simple sprain to a full dislocated-fractured injury. Here we are reporting a case of a 17 years old male athlete who presented a medial columellar dislocation M1C1 following a soccer game incident. Management consisted in closed reduction and immobilization in a posterior splint for 6 weeks. Both clinical and radiological results were satisfying in short, medium and long term. Our patient went from passive rehabilitation after 6 weeks, to partial weight bearing after 9 weeks, and then a full weight bearing at 14 weeks gradually returning to his soccer training, individually first and then collectively. At the last follow up, 2 years after the incident, our patient regained full and painless professional activity. This study purpose was to shed light on the potential good results of the non-operative treatment in Lisfranc injuries even in athletic/high performance patients.

Keywords: Lisfranc Injury, Dislocation, Fracture, Reduction, Operative/Nonoperative Treatment.

Copyright © 2025 The Author(s): This is an open-access article distributed under the terms of the Creative Commons Attribution 4.0 International License (CC BY-NC 4.0) which permits unrestricted use, distribution, and reproduction in any medium for non-commercial use provided the original author and source are credited.

INTRODUCTION

The tarsometatarsal (TMT) joints injury of the midfoot are referred to as Lisfranc injury [1]. Its specter can go from sprain or subluxation to a displaced fracture or fracture-dislocation of the TMT joints [2].

CASE REPORT

A 17-year-old athlete (soccer player) with no previous history of any kind presented to the emergency department following a sports accident (tackle during a soccer match). The patient presented walking with two crutches, unable to support himself with his right foot. On inspection, he had a deformity opposite the 1st metatarsal joint, with slight oedema (Fig 1). On palpation, he had pain over the deformity and the 2nd and 3rd metatarsals. Neurovascular examinations were normal. X-rays of the right foot confirmed the diagnosis of a Lisfranc dislocation (medial columellar dislocation M1C1) associated with a non-displaced fracture of the 2nd and 3rd metatarsals (Fig 2). The patient was admitted to the operating room where a reduction of the dislocation (1st metatarsal and medial cuneiform bone) was performed under sedation. The right foot was immobilized with a posterior splint. X-rays of the foot

confirmed the reduction of the dislocation (Fig 3-4). The patient was discharged 12 hours after the procedure, without weight-bearing on the right foot for 6 weeks and was put under NSAIDs for 10 days associated with painkillers if necessary.

Follow Up

Two weeks after the procedure, the patient improved well, with less pain and a stable Lisfranc joint. Upon six weeks, the radiological assessment showed good consolidation of the fracture of the 2nd and 3rd metatarsals, which is why it was decided to start passive rehabilitation for 3 weeks before gradually introducing active rehabilitation which included Range of Motion Exercises, Strengthening Exercises, Balance and Proprioception Training, and Gait Training, all while monitoring the progress made by our patient. After 14 weeks, gradually resumed individual training with no initial pivot movements. After 16 weeks, training in small groups of 4 or 5 players was initiated, and then after 5 months, our patient resumed training with the whole group, and started competing again in the 6th month. During his last check-up, two years after his injury, the patient was satisfied, with no pain or limitations in his sporting activities.

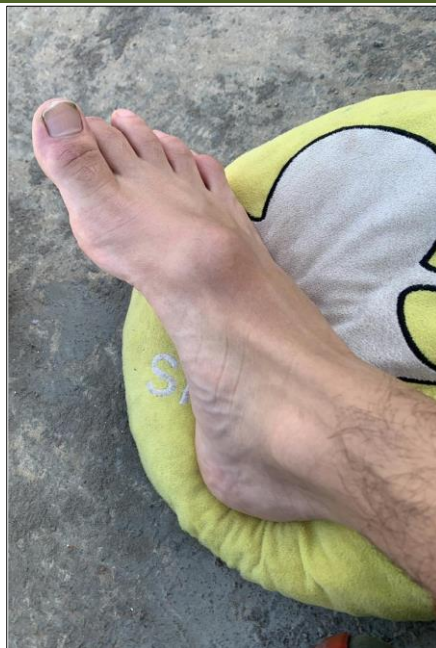

Fig. 1: Clinical image of our patient's foot upon arrival at the Emergency Department

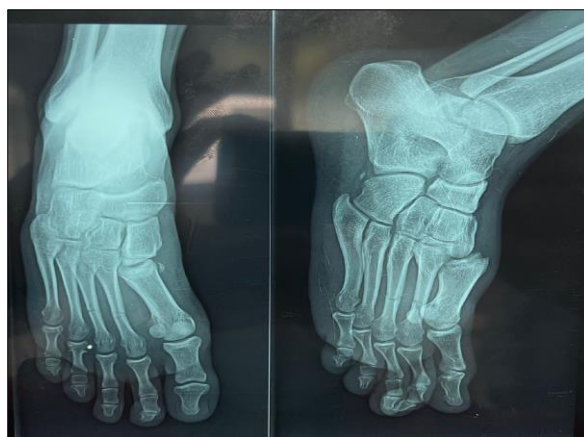

Fig. 2: Radiography of the right foot showing a dislocated M1C1 associated with a fracture of the 2nd and 3rd metatarsal

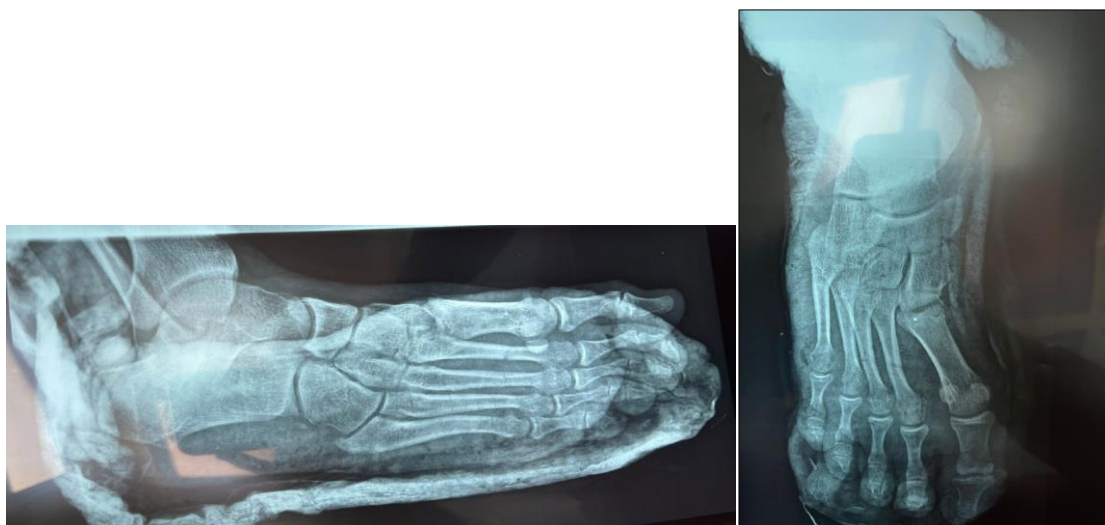

Fig. 3-4: Radiography of the foot after reduction and immobilization

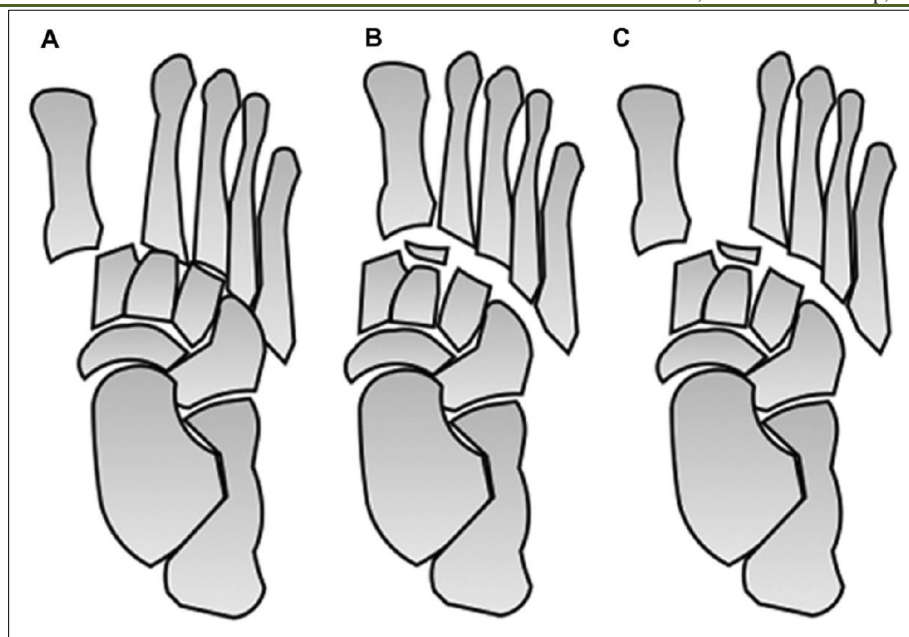


Fig 5: Quenu classification:
(A) Isolated
(B) Homolateral
(C) Divergent

DISCUSSION

High-energy injuries and Low energy injuries are the two main groups of the Lisfranc Injuries. The first one often results from crush injuries, falls, or motor vehicle accidents, meanwhile low-energy injuries, are commonly seen in professional athletic trauma or during missteps. While representing approximately 15% of all athletic injuries, Lisfranc injuries have become the second most common foot injury in sports. Sports such as football, soccer, running, gymnastics, and horse riding are the activities that have been associated the most with these kinds of injuries, with a male dominance of 2 to 4 times compared to women, possibly due to higher participation in high-speed activities.

Classifications

Since the early 20th century, many classifications for Lisfranc injuries have been proposed, notably by Quenu and Kuss. These systems can apply to both high-energy and low-energy injuries. In the Quenu and Kuss classification, Lisfranc fracture-dislocations are arranged into three types based on metatarsal displacement direction: homolateral (most common), isolated (least common), or divergent. (fig 5).

Diagnostic

Lisfranc injuries resulting from High-energy traumas typically present upon arrival at the emergency room with evident signs as: mid-foot swelling, deformity, and a flattened foot arch. Soft tissue injuries may include open fractures, damage to the dorsalis pedis, and injuries to the deep peroneal nerve. On the other hand, low-energy Lisfranc injuries present differently,

with patients unable to bear weight and showing varying degrees of mid-foot swelling. Palpation or manipulation of the tarsometatarsal joints elicits pain. Initial imaging involves non-weight-bearing anterior posterior and lateral radiographs, with CT helping in subtle injury detection. When radiographs are normal and suspicion of a lisfranc injury remains high, MRI finds its place for diagnosing and managing those injuries.

Treatment

Although some advocate for nonoperative approaches, operative treatment is typically favored for Lisfranc injuries in athletes. Nonoperative treatment involves protected weight-bearing in an ankle motion walking boot or splint, with frequent physical and radiological exams. If stable, weight-bearing can progress, and immobilization discontinued with a gradual return to activity, taking approximately four months for recovery. Operative options include open reduction and internal fixation or arthrodesis.

CONCLUSION

The decision between operative and nonoperative treatment for Lisfranc injuries, especially in athletes with stable injuries, can be challenging. Our experience suggests that nonoperative treatment can be effective, but further research is needed to establish clear guidelines in the athletic context.

REFERENCES

- Cheung, Y. Y. (2015). Soft tissue injury to the ankle: ligament injuries. *Musculoskeletal Imaging*. 2nd ed. Philadelphia, PA: Saunders Elsevier, 455-473.

- Fischer, L. P. (2005). Jacques Lisfranc de saint-martin (1787-1847). *Histoire des sciences médicales*, 39(1), 17-34.
- Richter, M., Wippermann, B., Krettek, C., Schratt, H. E., Hufner, T., & Thermann, H. (2001). Fractures and fracture dislocations of the midfoot: occurrence, causes and long-term results. *Foot & Ankle International*, 22(5), 392-398.
- Shapiro, M. S., Wascher, D. C., & Finerman, G. A. (1994). Rupture of Lisfranc's ligament in athletes. *The American journal of sports medicine*, 22(5), 687-691.
- Welck, M. J., Zinchenko, R., & Rudge, B. (2015). Lisfranc injuries. *Injury*, 46(4), 536-541.