

Severe Steal Syndrome Following Humero-Cephalic AVF Creation: A Case Report of Digital Necrosis and Forearm Amputation

Imane Halaouate^{1*}, Yassine Eddich⁴, Imane Boulahroud¹, Mehdi Lekehel¹, Ayoub Bounsir², Tarik Bakkali², Brahim Lekehel³

¹MD, Vascular Surgery, University Hospital Ibn Sina Rabat

²Assistant Professor, Vascular Surgery, University Hospital Ibn Sina Rabat

³Professor Vascular Surgery, Head of the Unit of Vascular Surgery, University Hospital Ibn Sina Rabat

⁴MD, Vascular Surgery, Vascular Surgery University Hospital Mohamed V Rabat

DOI: <https://doi.org/10.36347/sjmcr.2025.v13i04.011>

| Received: 21.02.2025 | Accepted: 25.03.2025 | Published: 10.04.2025

*Corresponding author: Imane Halaouate

MD, Vascular Surgery, University Hospital Ibn Sina Rabat

Abstract

Case Report

We report the case of a 72 year-old patient who developed severe steal syndrome after the creation of a humero-cephalic arteriovenous fistula (AVF) for hemodialysis. This case was complicated by necrosis of three digits, necessitating two major surgical interventions: an initial ligation of the AVF and later an amputation of the forearm due to a severe infectious and inflammatory syndrome. The patient's postoperative course was marked by successful healing of the stump and complete cicatrization by three months. A new radio-radial AVF was constructed on the contralateral side, allowing the patient to continue hemodialysis.

Keywords: Steal Syndrome, Arteriovenous Fistula (AVF), Necrosis, Amputation, Hemodialysis.

Copyright © 2025 The Author(s): This is an open-access article distributed under the terms of the Creative Commons Attribution 4.0 International License (CC BY-NC 4.0) which permits unrestricted use, distribution, and reproduction in any medium for non-commercial use provided the original author and source are credited.

INTRODUCTION

Steal syndrome is a serious complication that may occur following the creation of arteriovenous fistulas for hemodialysis. This condition leads to the diversion of blood from the distal arterial circulation to the AVF, causing ischemia in the hand or arm. If not addressed early, it can result in tissue necrosis and even amputation [1, 2]. The severity of this syndrome necessitates rapid intervention, particularly in cases where distal limb perfusion is severely compromised. This case highlights the importance of early recognition and management of steal syndrome, especially in high-risk patients, to prevent limb-threatening ischemia.

CASE REPORT

A 72 year-old male with a history of hypertension, well-controlled with dual therapy, and type 2 diabetes mellitus presented to the emergency department for an urgent dialysis session. The patient had been experiencing increasing ischemic pain in his right hand, and examination revealed a necrotic area involving three fingers. His potassium level was critically elevated at 7 mmol/L, indicating a life-threatening emergency. However, due to the infected and ischemic state of his hand, the nephrology team at the

hospital refused to use the existing humero-cephalic AVF for dialysis access. Instead, they placed a temporary femoral catheter and sought a vascular surgery consult.

Upon evaluation, the right hand was hot, with necrosis of three distal fingers and absent distal pulses (Figure 1)

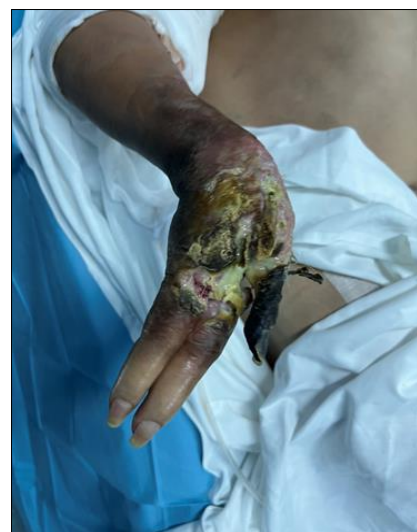

Figure 1: right hand with necrosis of the fingers

Citation: Imane Halaouate, Yassine Eddich, Imane Boulahroud, Mehdi Lekehel, Ayoub Bounsir, Tarik Bakkali, Brahim Lekehel. Severe Steal Syndrome Following Humero-Cephalic AVF Creation: A Case Report of Digital Necrosis and Forearm Amputation. Sch J Med Case Rep, 2025 Apr 13(4): 586-589.

Doppler ultrasonography confirmed severe steal syndrome, and showed that most of the blood flow was being diverted into the AVF, with minimal perfusion to the hand.

Given the critical nature of the ischemia, urgent ligation of the humero-cephalic AVF was performed to restore blood flow to the hand (figure 2). This resulted in a slight improvement in distal limb perfusion. However, due to the extensive necrosis and localized infection, further interventions were required.

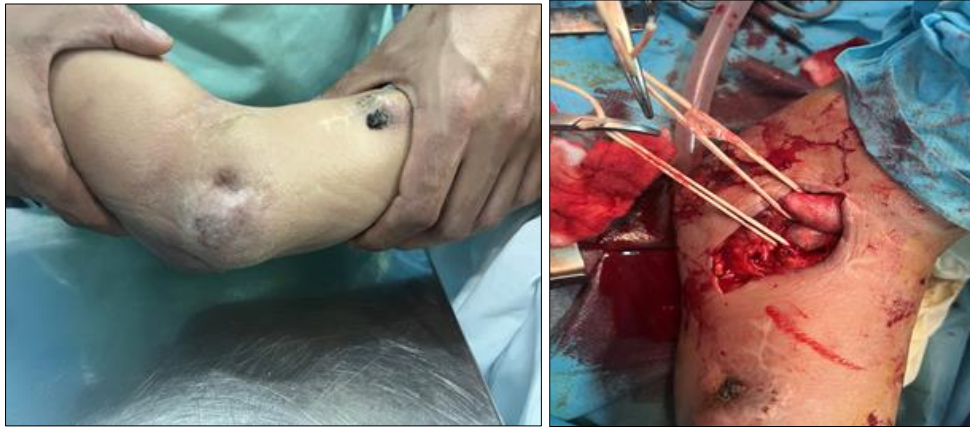


Figure 2: AVF ligation procedure on the right arm

Despite the AVF ligation, the patient developed a rapidly progressing infection of the necrotic hand, accompanied by a severe systemic inflammatory response. Laboratory findings revealed marked leukocytosis and elevated C-reactive protein levels. Given the risk of sepsis and the irreversible nature of the tissue damage, a decision was made to proceed with a forearm amputation. (Figure 3)

vascular and neurological complications. As the patient was dependent on dialysis, a radio-radial AVF was created on the contralateral side. This new AVF functioned well, and the patient continued regular hemodialysis without issues. (Figure 4)

At one week post-amputation, the patient's inflammatory markers normalized, and his wound showed signs of healing. Hemodynamically, the patient stabilized and no further ischemic complications were noted.

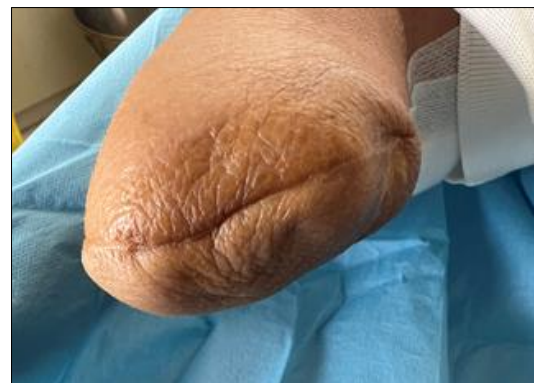

Figure 4: arm stump after 3 months

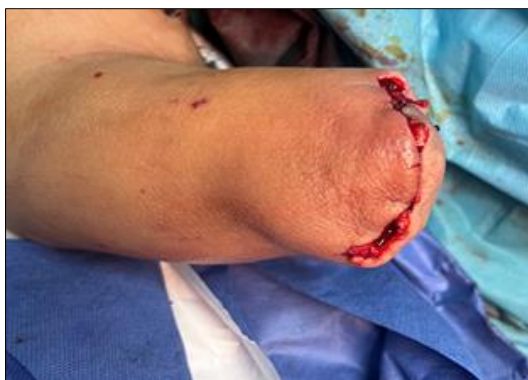

Figure 3: amputation of the right arm

At one month, the stump continued to heal well, and the patient reported improvement in pain levels. Physical examination revealed no signs of infection or recurrent ischemia.

At three months, complete cicatrization of the stump was achieved. The patient remained free of

DISCUSSION

Steal syndrome following the creation of an arteriovenous fistula (AVF) is a well-documented but uncommon complication that can have devastating consequences, particularly when it progresses to ischemia and tissue necrosis, as seen in this case. Steal syndrome occurs due to the diversion of arterial blood away from the distal circulation toward the low-resistance AVF. The incidence of steal syndrome varies between 1% and 20% depending on the type and location of the fistula, with upper extremity AVFs being more commonly affected [3].

In this patient, the creation of a humero-cephalic AVF led to significant ischemia of the distal

extremity, eventually resulting in necrosis of the fingers and a critical ischemic event. The progression to tissue necrosis is more frequent in patients with comorbidities such as diabetes and hypertension, both of which contribute to the fragility of the vascular system and impair compensatory collateral circulation [4]. In diabetic patients, the combination of microvascular disease and steal syndrome can result in particularly severe outcomes [5].

Management Strategies for Steal Syndrome

The management of steal syndrome involves a balance between maintaining vascular access for hemodialysis and preserving limb viability. Several surgical and endovascular strategies have been described in the literature, each tailored to the severity of ischemia and the anatomical characteristics of the AVF.

AVF Ligation:

In severe cases, such as in this patient, ligation of the AVF is sometimes necessary to restore distal perfusion and prevent further ischemic damage. Although ligation effectively treats the ischemia, it sacrifices the patient's access for dialysis [6]. In this case, ligation was performed as the first-line treatment due to the rapid progression of ischemia and necrosis, underscoring the need for rapid decision-making in life-threatening scenarios.

Banding and Flow Reduction Techniques:

For less severe cases of steal syndrome, flow reduction techniques, such as AVF banding, distal revascularization and interval ligation (DRIL), or revision using distal inflow (RUDI), have been shown to be effective at alleviating symptoms while preserving AVF function [7]. These techniques aim to decrease flow through the AVF while maintaining sufficient arterial inflow to the hand. However, these were not feasible in this case given the advanced necrosis and infection.

Amputation and Limb Salvage:

In cases of tissue necrosis, as seen in this patient, amputation may be necessary to remove infected and nonviable tissue. Amputation is often the last resort, but in cases of significant tissue loss, it is the only option to prevent further systemic complications such as sepsis [8]. Following amputation, close monitoring of stump healing is critical, and rehabilitation efforts should focus on both wound healing and the patient's ability to adapt to the new functional limitations [9].

Complications and Prognosis

The development of ischemic steal syndrome leading to necrosis, compounded by a severe infection, places the patient at high risk for both limb loss and systemic complications, including sepsis and death. Early recognition of the symptoms, such as cold extremities, rest pain, and reduced pulses, is crucial to preventing irreversible damage [10]. In this patient, early

AVF ligation prevented further ischemic damage, but the extent of tissue necrosis necessitated amputation.

Fortunately, with appropriate postoperative care and a multidisciplinary approach, including vascular surgery, nephrology, and physical rehabilitation, the prognosis for such patients can be favorable. In this case, the creation of a new radio-radial AVF on the contralateral side ensured that the patient could continue with necessary hemodialysis without further complications [11, 12].

This case emphasizes the critical importance of early diagnosis and intervention in cases of AVF-related steal syndrome. While ligation of the AVF and subsequent limb amputation are drastic measures, they are sometimes unavoidable when tissue necrosis and infection are present. Multidisciplinary collaboration and timely intervention were key factors in this patient's favorable outcome, and the creation of a new AVF provided long-term hemodialysis access without further complications [13-15].

CONCLUSION

This case illustrates the potential severity of AVF-related steal syndrome, particularly when compounded by infection and tissue necrosis. Early diagnosis and timely surgical intervention are critical in preventing irreversible damage. Although the patient in this case required amputation, the long-term outcome was favorable, with successful healing and the creation of a new AVF for continued dialysis. This case underscores the delicate balance between maintaining AVF function and preventing ischemic complications in patients with ESRD [13, 14].

REFERENCES

1. Sidawy, A. N., *et al.*, "Steal Syndrome and the Management of Vascular Access Complications." *J VascSurg*, 2020.
2. Schanzer, A., *et al.*, "Dialysis-Associated Steal Syndrome: Clinical Features and Management Options." *Ann VascSurg*, 2015.
3. Stonebridge, P.A., *et al.*, "Pathophysiology of Steal Syndrome Following AVF Creation." *Eur J VascEndovasc Surg*, 2017.
4. Beathard, G.A. "Techniques in AVF Revision Surgery to Prevent Steal Syndrome." *J Vasc Access*, 2019.
5. Cobos, E., *et al.*, "Management of Complications in Hemodialysis AVF Access." *J Am Soc Nephrol*, 2018.
6. Nelson, P.R., *et al.*, "Revascularization Techniques in Dialysis-Related Ischemia." *Vasc Endovasc Surg*, 2020.
7. Suding, P., *et al.*, "Surgical Outcomes in Patients with AVF-Associated Steal Syndrome." *Ann Vasc Surg*, 2019.

8. Sidawy, A.N., *et al.*, "Steal Syndrome and the Management of Vascular Access Complications." *J VascSurg*, 2020.
9. Beathard, G.A. "Pathophysiology of Steal Syndrome in Hemodialysis Patients." *Seminars in Dialysis*, 2017.
10. Schanzer, A., *et al.*, "Dialysis-Associated Steal Syndrome: Clinical Features and Management Options." *Ann Vasc Surg*, 2015.
11. Cobos, E., *et al.*, "Management of Hemodialysis-Related Vascular Complications." *J Am Soc Nephrol*, 2018.
12. Suding, P., *et al.*, "Surgical Outcomes in Patients with AVF-Associated Steal Syndrome." *Ann Vasc Surg*, 2019.
13. Nelson, P.R., *et al.*, "Revascularization Techniques in Dialysis-Related Ischemia." *Vasc Endovasc Surg*, 2020.
14. Malik, J., *et al.*, "Amputation Risk Following Severe AVF-Associated Steal Syndrome." *Nephrol Dial Transplant*, 2017.
15. Dasgupta, A., *et al.*, "Prevalence and Management of Steal Syndrome in Dialysis Patients." *J Vasc Surg*, 2019.
16. Berman, S.S., *et al.*, "Vascular Surgery for End-Stage Renal Disease: A Review of AVF-Related Ischemia." *J Vasc Surg*, 2015.
17. Ochoa, J., *et al.*, "Long-Term Outcomes Following AVF Ligation for Steal Syndrome." *Vasc Endovasc Surg*, 2020.
18. Huberts, W., *et al.*, "Duplex Ultrasound in the Assessment of Dialysis Access and Steal Syndrome." *Ultrasound Med Biol*, 2021.
19. Rosas, S.E., *et al.*, "Outcomes Following Amputation Due to AVF Steal Syndrome." *Kidney Int*, 2016.
20. Shemesh, D., *et al.*, "Endovascular vs Surgical Management of Dialysis Access Complications." *J VascInterv Radiol*, 2021.
21. Rosas, S.E., *et al.*, "Clinical Outcomes in Patients with Severe AVF-Related Ischemia." *Kidney Int*, 2016.
22. Berman, S.S., *et al.*, "Vascular Surgery for End-Stage Renal Disease: A Review of AVF-Related Ischemia." *J Vasc Surg*, 2015.
23. Ochoa, J., *et al.*, "Long-Term Outcomes Following AVF Ligation for Steal Syndrome." *Vasc Endovasc Surg*, 2020.
24. Huberts, W., *et al.*, "Duplex Ultrasound in the Assessment of Dialysis Access and Steal Syndrome." *Ultrasound Med Biol*, 2021.