Scholars Journal of Medical Case Reports
Abbreviated Key Title: Sch J Med Case Rep
ISSN 2347-9507 (Print) | ISSN 2347-6559 (Online)
Journal homepage: https://saspublishers.com

OPEN ACCESS

Dental Medicine

Solitary Bone Cyst of the Mandible Mimicking an Odontogenic Keratocyst: A Case Report and Brief Literature Review

Sarra Azzez[1*], Hela Zouaghi[1], Chaima Haj Hassine[1], Chiraz Baccouche[1]

[1]Department of Dental Medicine, Taher Sfar Teaching Hospital, Faculty of Dental Medicine of Monastir, University of Monastir, Monastir, Tunisia

DOI: https://doi.org/10.36347/sjmcr.2026.v14i10.050 | **Received:** 21.08.2026 | **Accepted:** 13.10.2026 | **Published:** 24.10.2026

***Corresponding author:** Sarra Azzez
Department of Dental Medicine, Taher Sfar Teaching Hospital, Faculty of Dental Medicine of Monastir, University of Monastir, Monastir, Tunisia

Abstract **Case Report**

Solitary bone cyst (SBC) is an uncommon, benign, non-neoplastic osteolytic pseudocyst without an epithelial lining. It occurs mainly in the second decade of life and predominantly in the mandible. Large lesions may mimic aggressive odontogenic lesions. A 16-year-old male in good general health presented with pain and mobility of a retained primary lower right second molar (85). Panoramic radiography showed agenesis of tooth 45 and an incidental, well-defined, 4 cm homogeneous radiolucency in the left mandibular body adjacent to teeth 33–37, all of which were vital. CT showed a 4.3 × 2 cm osteolytic lesion with clear borders in direct contact with the left inferior alveolar nerve (IAN), and a preoperative diagnosis of odontogenic keratocyst (OKC) was made. Exploration under local anaesthesia revealed an empty intraosseous cavity without lining or fluid, with the IAN exposed on its floor. The diagnosis of SBC was established operatively. Curettage of the bony walls was performed to induce intramedullary bleeding. Healing was uneventful. A one-year follow-up showed complete reossification and normal neurosensory outcome. SBC can mimic OKC or unicystic ameloblastoma on imaging. Surgical exploration is both diagnostic and therapeutic, and may avoid more aggressive treatment. Long-term clinical and radiographic follow-up is needed to confirm reossification and detect recurrence.

Learning points: (1) Large unilocular mandibular radiolucencies in adolescents with vital teeth should include SBC in the differential diagnosis. (2) Contact with the IAN on CT does not by itself indicate an aggressive lesion. (3) Conservative exploration with curettage can establish the diagnosis and treat the lesion in a single procedure.

Keywords: solitary bone cyst; simple bone cyst; traumatic bone cyst; mandible; odontogenic keratocyst; inferior alveolar nerve; curettage.

Copyright © 2026 The Author(s): This is an open-access article distributed under the terms of the Creative Commons Attribution **4.0 International License (CC BY-NC 4.0)** which permits unrestricted use, distribution, and reproduction in any medium for non-commercial use provided the original author and source are credited.

Introduction

Solitary bone cyst (SBC) is a non-neoplastic intraosseous pseudocyst without an epithelial lining [1]. In the 2022 fifth edition of the WHO Classification of Head and Neck Tumors, it is classified as a non-neoplastic, non-odontogenic bone lesion of the jaws [2]. It primarily affects the mandible, especially the posterior body and premolar–molar regions, and is most common in children and adolescents [3]. Although usually asymptomatic and discovered incidentally, SBC typically appears as a well-defined radiolucency scalloping between the roots of vital teeth [1]. Its unclear pathogenesis has been attributed to trauma-related hemorrhage, vascular obstruction, or developmental and ischemic abnormalities [1]. Large or atypical lesions may resemble odontogenic keratocysts, unicystic ameloblastomas, or other jaw lesions, creating diagnostic challenges [4].

This report describes a large mandibular SBC that mimicked an odontogenic keratocyst on computed tomography because of its size and proximity to the inferior alveolar nerve. It highlights the clinical and radiological features of this unusual presentation, discusses its diagnostic and management implications, and emphasizes the importance of considering SBC in the differential diagnosis of extensive mandibular radiolucencies.

Case Report

A 16-year-old male in good general health presented with localized pain and tooth mobility in the lower right quadrant. Medical, surgical and family

histories were non-contributory. There was no history of trauma, extractions or orthodontic treatment.

The primary lower right second molar (85) was retained, with grade II mobility and tenderness on handling. The oral mucosa was intact and healthy, with no ulceration, swelling, cortical bulging, sinus tract, or signs of inflammation. Permanent teeth 34, 35, 36, and 37 responded normally to pulp vitality testing. Extraoral examination showed facial symmetry with no lymphadenopathy or neurosensory deficit.

Panoramic radiography showed an incidental, well-demarcated, homogeneous, unilocular radiolucency of about 4 cm in the left mandibular body, extending along the root apices of teeth 33–37. No root resorption or tooth displacement was observed (**Figure 1**).

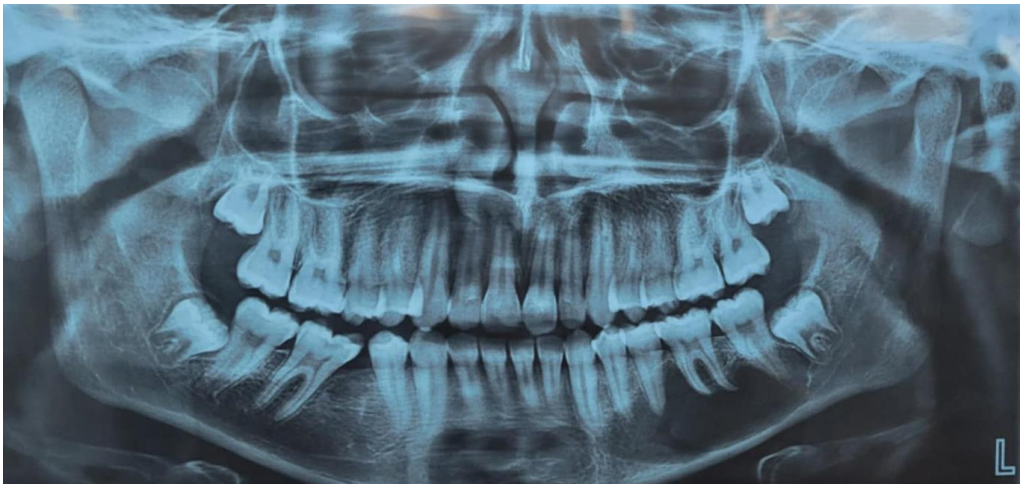

Figure 1: Panoramic x-ray showing an incidental finding of a radiolucent left mandibular lesion

The CT scan showed a well-defined, homogeneous osteolytic lesion of cystic density measuring 4.3 × 2 cm in the sagittal plane, with smooth margins and direct contact between its deep aspect and the left IAN canal, without buccolingual cortical expansion (**Figure 2**).

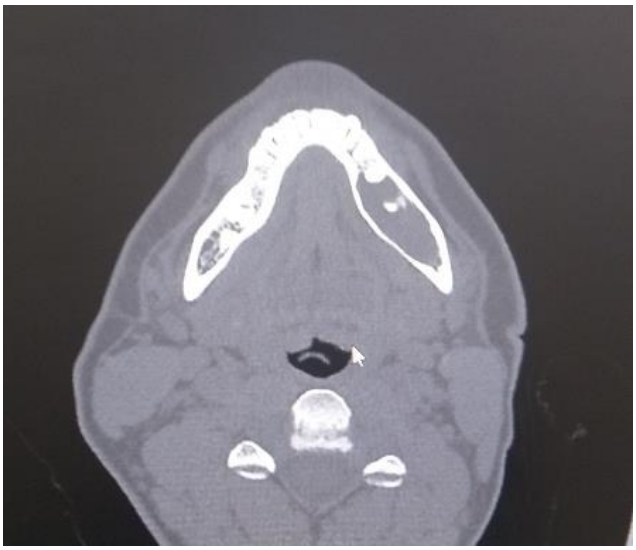

Figure 2: Mandibular CT scan (axial view) showing a homogeneous osteolytic left mandibular lesion

Given its size, anteroposterior medullary extension, and proximity to the inferior alveolar canal, a provisional diagnosis of OKC was made. Other differential diagnoses, such as unicystic ameloblastoma, were considered less likely.

Under local anaesthesia, a full-thickness mucoperiosteal flap was raised on the buccal aspect of the left mandibular body, and a conservative cortical osteotomy was made with a surgical bur. The cavity was empty, without fluid, tissue or lining, and the left IAN was visible on its floor (**Figure 3**). The bony walls were curetted to induce intramedullary bleeding and form a blood clot as a scaffold for osteogenesis. The flap was repositioned and closed primarily.

Figure 3: An intraoperative view with IAN exposure

No soft tissue or lining was obtained for histological examination, so the absence of an epithelial or neoplastic lining is based on the operative findings.

Postoperative healing was uneventful, with no neurovascular deficit or wound dehiscence. Clinical and radiographic surveillance was started. At 1-year follow-up, the panoramic X-ray showed complete reossification **(Figure 4).**

Figure 4: Panoramic X-ray at one-year follow-up

Written informed consent was obtained from the parents of the patient for publication of this case report and the accompanying iconographic data.

Discussion

Solitary bone cyst (SBC) remains a diagnostic challenge in oral and maxillofacial surgery because its radiographic appearance may overlap with that of several odontogenic and non-odontogenic lesions [4]. Our patient fit the usual demographic profile, and the lesion was discovered incidentally during assessment of a retained primary molar on the contralateral side. Typical SBCs produce unilocular radiolucencies with scalloped margins between the roots of vital teeth; however, larger lesions may cause cortical thinning or erosion, appear multilocular on panoramic imaging, and extend close to neurovascular structures [4,5]. In the present case, the lesion's size, homogeneous appearance, anteroposterior extension, and contact with the inferior alveolar nerve suggested an odontogenic keratocyst, whereas the vitality of adjacent teeth and the absence of root resorption or displacement supported, but did not establish, the diagnosis of SBC. The main differential diagnoses and their distinguishing features are summarized in Table 1.

The etiopathogenesis of SBC remains uncertain, although the trauma-related intramedullary hematoma hypothesis is most widely cited [6]. According to this theory, intraosseous bleeding following minor trauma may undergo clot lysis without adequate organization, resulting in cavity formation and progressive enlargement through fluid pressure and osmotic gradients [6]. Repetitive microtrauma, orthodontic movement, or previous extraction has also been proposed as a possible trigger [7,8,9,10]; however, no relevant traumatic, extraction-related, or orthodontic event was identified in our patient, and the agenesis of tooth 45 was considered incidental.

Surgical exploration with curettage remains the most widely used treatment [7,10]. It confirms the diagnosis by showing an empty, non-epithelialized cavity and stimulates bleeding, with the clot acting as a matrix for osteoblast migration [7,10]. Alternative approaches include decompression [8], filling with autologous blood or biomaterials [9], and radiographic observation of selected small, asymptomatic lesions [10]. Brunet-Llobet *et al.,*used a microperforated Nelaton catheter through a small trepanation, achieving gradual osteogenesis over 18–24 months while preserving tooth vitality [8]. Fındık *et al.,*filled a large posterior mandibular SBC with platelet-rich fibrin to accelerate osteogenesis [8]. Other techniques include injection of autologous venous blood, bovine lyophilised bone, and cannulated hydroxyapatite pins [9]. However, exploration was chosen in this case because the atypical imaging features did not exclude an aggressive lesion and because the procedure was both diagnostic and therapeutic. Radiographic healing generally occurs within 6–24 months [7,10], while recurrence is uncommon but may be more frequent in multilocular lesions or those associated with florid cemento-osseous dysplasia [1]. Long-term radiographic surveillance, preferably for at least three years or until complete healing is documented, is therefore advisable [11]. The main strengths of this report are the documentation of a large mandibular SBC with computed tomography findings, intraoperative confirmation, and direct visualization of the inferior alveolar nerve. Its limitations include the single-case design, the absence of a histological specimen, and the limited follow-up period.

Table 1: Differential diagnosis of radiolucent mandibular lesions [1]

Entity	Clinical features	Radiographic pattern	Key distinguishing factor
Solitary bone cyst (SBC)	Asymptomatic; young patients; vital teeth	Unilocular, scalloped margins; minimal expansion	Empty cavity without epithelial lining at surgery
Odontogenic keratocyst (OKC)	Aggressive medullary growth; high recurrence	Unilocular/multilocular; anteroposterior spread	Parakeratinized epithelial lining on histology
Unicystic ameloblastoma	Localized expansion; young adults	Well-defined radiolucency;root resorption	Ameloblastic epithelium; root resorption common
Central giant cell granuloma	Anterior mandible; female predilection	Expansile, multilocular; cortical breach	Multinucleated giant cells in fibrous stroma
Aneurysmal bone cyst (ABC)	Rapid expansion; pain; cortical ballooning	"Soap-bubble" multilocular expansion	Blood-filled pseudocyst with giant cells

Conclusion

SBC of the mandible is a benign pseudocyst occurring mainly in adolescents. Large or atypical lesions can mimic OKC on CT, including with contact with the inferior alveolar nerve. Surgical exploration with curettage can establish the diagnosis and treat the lesion in one step. Long-term clinical and radiographic follow-up is essential to confirm reossification and exclude recurrence.

References

1. Chadwick JW, Alsufyani NA, Lam EW. (2011). Clinical and radiographic features of solitary and cemento-osseous dysplasia-associated simple bone cysts. Dentomaxillofac Radiol. ;40(4):230-5. doi: 10.1259/dmfr/16355120.
2. Soluk-Tekkesin M, Wright JM. (2002). The World Health Organization Classification of Odontogenic Lesions: A Summary of the Changes of the 2022 (5th) Edition. Turk Patoloji Derg. ;38(2):168-184. doi: 10.5146/tjpath.2022.01573.
3. Tufan Yucesoy M, Duman Tepe R, Soluk Tekkesin M, Cakir Karabas H. (2025). Radiographic and histopathologic characteristics of simple bone cysts: a retrospective study of 46 cases. BMC Oral Health ;26(1):125. doi: 10.1186/s12903-025-07511-z.
4. Sabino-Bezerra JR, Santos-Silva AR, Jorge J Jr, Gouvêa AF, Lopes MA. (2013). Atypical presentations of simple bone cysts of the mandible: a case series and review of literature. J Craniomaxillofac Surg ;41(5):391-6. doi: 10.1016/j.jcms.2012.11.002. Epub 2012 Dec 6.
5. Copete MA, Kawamata A, Langlais RP. (1998). Solitary bone cyst of the jaws: radiographic review of 44 cases. Oral Surg Oral Med Oral Pathol Oral Radiol Endod ;85(2):221-5. doi: 10.1016/s1079-2104(98)90430-9.
6. Harnet JC, Lombardi T, Klewansky P, Rieger J, Tempe MH, Clavert JM. (2008). Solitary bone cyst of the jaws: a review of the etiopathogenic hypotheses. J Oral Maxillofac Surg;66(11):2345-8. doi: 10.1016/j.joms.2007.08.035.
7. Peñarrocha-Diago M, Sanchis-Bielsa JM, Bonet-Marco J, Minguez-Sanz JM. (2011). Surgical treatment and follow-up of solitary bone cyst of the mandible:a report of seven cases. Br J Oral Maxillofac Surg ;39(3):221-3. doi: 10.1054/bjom.2000.0559.
8. Brunet-Llobet L, Lahor-Soler E, Mashala EI, Miranda-Rius J. (2019). Continuous Surgical Decompression for Solitary Bone Cyst of the Jaw in a Teenage Patient. Case Rep Dent; 2019:9137507. doi: 10.1155/2019/9137507.
9. Fındık Y, Baykul T, Bülte M. (2014). Huge Solitary Bone Cyst located in Posterior Mandible. Int J Exp Dent Sci;3(1):53-56.
10. Suei Y, Taguchi A, Tanimoto K. (2007). Simple bone cyst of the jaws: evaluation of treatment outcome by review of 132 cases. J Oral Maxillofac

Surg ;65(5):918-23.doi:10.1016/j.joms.2006.06.297.
11. Lucena IM de, Santos I da S, Gamba T de O, Flores IL, Rados PV. (2020). Recurrence of simple bone cyst: a case report and brief review of literature. J Oral Diagn [Internet]. [cited 2026 Oct. 7];5:1-7. Available from: https://joraldiagnosis.com/revista/article/view/82