Scholars Journal of Medical Case Reports
Abbreviated Key Title: Sch J Med Case Rep
ISSN 2347-9507 (Print) | ISSN 2347-6559 (Online)
Journal homepage: https://saspublishers.com

OPEN ACCESS

Anesthesiology

Spontaneous Pneumomediastinum with Cervical Subcutaneous Emphysema in a Young Asthmatic Patient: A Case Report

Boubekri Ayoub[1*], Hmadate Ilyass[1], Atmani Walid[1], Bensghir Mustapha[1], Drissi Mohamed[1], Balkhi Hicham[1]

[1]Department of Anesthesiology and Intensive Care, Mohammed V Military Teaching Hospital, Rabat, Morocco

DOI: https://doi.org/10.36347/sjmcr.2026.v14i10.051 | **Received:** 15.08.2026 | **Accepted:** 21.10.2026 | **Published:** 22.10.2026

***Corresponding author:** Boubekri Ayoub
Department of Anesthesiology and Intensive Care, Mohammed V Military Teaching Hospital, Rabat, Morocco

Abstract **Case Report**

Spontaneous pneumomediastinum (SPM) is a rare and usually benign condition defined by free air in the mediastinum in the absence of trauma, surgery, or hollow-organ perforation. We report the case of a 22-year-old man with known asthma, treated with an on-demand short-acting β2-agonist, who was admitted for sudden-onset respiratory distress. He was conscious, with a respiratory rate of 40 breaths/min, an oxygen saturation of 92% on room air, suprasternal retraction, and cervical swelling with subcutaneous emphysema. Pulmonary auscultation was normal and hemodynamics were stable. Chest radiography was followed by chest computed tomography, which confirmed the diagnosis. The patient was admitted to the intensive care unit for close monitoring and received high-concentration oxygen by mask and intravenous analgesia. The clinical course was favorable, with complete resorption of the pneumomediastinum within 7 days and no invasive or surgical procedure. SPM should be considered in any young asthmatic patient with sudden respiratory distress, particularly when cervical subcutaneous emphysema is present. Chest radiography guides the diagnosis, whereas computed tomography is the reference examination to confirm it and to exclude tracheobronchial or esophageal perforation. Conservative management with close monitoring is usually sufficient.

Keywords: Spontaneous pneumomediastinum; Hamman syndrome; Macklin effect; Subcutaneous emphysema; Asthma; Computed tomography.

Copyright © 2026 The Author(s): This is an open-access article distributed under the terms of the Creative Commons Attribution **4.0 International License (CC BY-NC 4.0)** which permits unrestricted use, distribution, and reproduction in any medium for non-commercial use provided the original author and source are credited.

INTRODUCTION

Spontaneous pneumomediastinum (SPM), first described by Hamman in 1939, is defined by the presence of free air in the mediastinum without trauma, surgical procedure, or perforation of a hollow organ. It is a rare condition, reported in approximately 1 in 30,000 emergency department referrals, and it predominantly affects young men.

Its mechanism is explained by the Macklin effect. A sudden rise in intra-alveolar pressure causes rupture of peripheral alveoli. Air then dissects along the peribronchovascular sheaths toward the hilum and reaches the mediastinum, from where it may extend to the cervical and subcutaneous spaces. Asthma is one of the most frequent predisposing factors, together with intense coughing, vomiting, straining against a closed glottis, and Valsalva maneuvers.

We report the case of a young asthmatic patient admitted for sudden respiratory distress, in whom imaging revealed an SPM with a favorable outcome under conservative treatment.

CASE REPORT

This retrospective clinical observation was collected in the emergency department of the Military Hospital of Guelmim and subsequently in the intensive care unit. A 22-year-old man with known asthma, treated with an on-demand short-acting β2-agonist, was admitted for sudden-onset respiratory distress. On admission, he was conscious and tachypneic, with a respiratory rate of 40 breaths/min and a pulse oxygen saturation of 92% on room air. Examination showed suprasternal retraction and subcutaneous emphysema of the cervical region with cervical swelling (Figure 1). Pulmonary auscultation was normal. The patient was hemodynamically stable, and the remainder of the clinical examination was unremarkable.

Figure 1: Clinical photograph of the neck and upper chest at admission, showing cervical swelling consistent with subcutaneous emphysema

A chest radiograph was performed first (Figure 2) and was completed by a chest computed tomography (CT) to confirm the diagnosis, assess the extent of the gaseous collection, and look for its origin (Figure 3). The CT confirmed the pneumomediastinum.

Figure 2: Frontal chest radiograph at admission, suggestive of pneumomediastinum

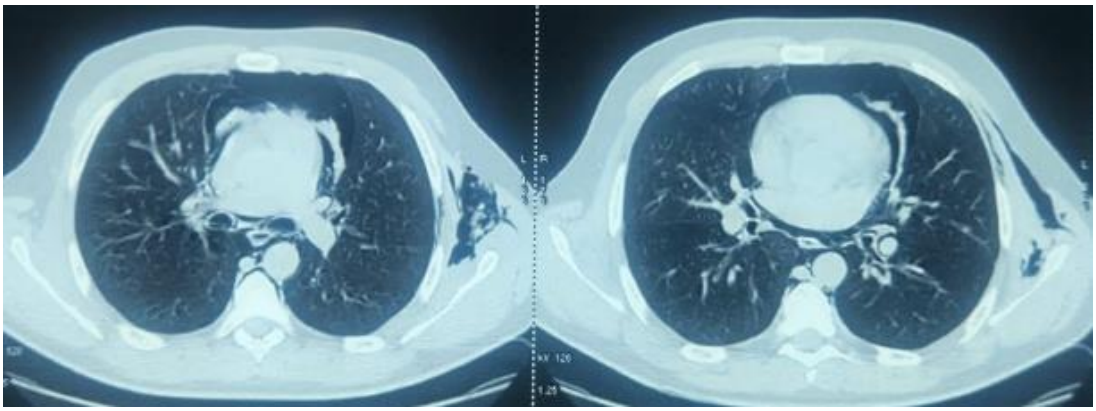

Figure 3: Axial chest computed tomography images (lung window) confirming the pneumomediastinum, with air also visible in the soft tissues of the chest wall

The patient was admitted to the intensive care unit for close monitoring of vital signs. He received high-concentration oxygen by mask and intravenous analgesia. The clinical course was favorable, with complete resorption of the pneumomediastinum within 7 days. No invasive or surgical procedure was required.

Discussion

Since its description by Hamman in 1939 [1], SPM has been recognized as an uncommon entity whose mechanism, known as the Macklin effect [2], involves alveolar rupture followed by dissection of air along the peribronchovascular sheaths toward the mediastinum. Its incidence is approximately 1 in 30,000 emergency

department referrals [3]. The present patient corresponds to the typical profile of SPM: a young man with asthma [3,4]. Emesis and asthma exacerbations are the most frequently reported triggering events in published series [4], and respiratory diseases may lead to pneumomediastinum particularly during exacerbations with excessive coughing [5]. In our patient, no other precipitating event was identified, and an asthma exacerbation was the most likely trigger.

Chest pain and dyspnea are the most common presenting symptoms [3,4,6], whereas the presentation of our patient was dominated by acute respiratory distress and cervical subcutaneous emphysema. Subcutaneous emphysema can be detected in about 70% of patients with pneumomediastinum [5] and is the initial complaint in approximately one third of patients with SPM [4]. Although a crunching sound synchronous with the heartbeat (Hamman's sign) may be heard on auscultation [5], its absence, as in our patient, does not exclude the diagnosis.

The main diagnostic challenge is to distinguish SPM from secondary pneumomediastinum due to potentially life-threatening conditions, such as esophageal rupture (Boerhaave syndrome) or tracheobronchial injury [3,6]. In our patient, the combination of respiratory distress, hypoxemia, and cervical subcutaneous emphysema justified a complete imaging assessment.

Chest radiography is the first-line examination, and SPM is more likely to be discovered by chest radiography than secondary pneumomediastinum [4]. However, radiography may miss small collections: in one series, CT revealed a pneumomediastinum not visible on the chest radiograph in 9 of 38 patients [6]. CT therefore remains the reference examination. It confirms the diagnosis, defines the extent of the air collection, and may show the Macklin effect, which appears as linear collections of air contiguous to the bronchovascular sheaths and may help differentiate a respiratory origin from other etiologies [7]. CT also allows a search for pneumothorax and for signs of tracheobronchial or esophageal injury.

The extent of the diagnostic work-up should be adapted to the clinical context. In a retrospective series of 49 patients with SPM, esophagography, performed in 17 patients, was invariably negative, and the authors concluded that SPM rarely corresponds to a true esophageal perforation and that an extensive work-up is not required [6]. Further esophageal evaluation should therefore be reserved for patients whose history or evolution suggests a perforation [3,6].

Management of SPM is essentially conservative, based on observation, analgesia, treatment of the underlying cause, and avoidance of the triggering mechanism. The condition is considered benign, treatment is expectant, and recurrence is low [4]. Most published series support this approach [8–10], and complications are rare [3,11]. In our patient, admission to the intensive care unit was a precautionary measure that allowed close monitoring of vital signs. High-concentration oxygen is commonly administered in this setting; however, the specific contribution of oxygen therapy to resorption cannot be determined from a single case. Resorption was complete within 7 days without any invasive procedure.

This report has the limitations inherent to a single retrospective case. Nevertheless, it illustrates that SPM should be considered in any young asthmatic patient presenting with sudden respiratory distress, especially when cervical subcutaneous emphysema is present, and that early recognition, strict monitoring, and an appropriate imaging assessment allow a favorable outcome.

Conclusion

SPM is a rare but, in most cases, benign complication, for which asthma is a recognized predisposing factor. It should be considered in any sudden respiratory distress in a young asthmatic patient. Chest radiography guides the diagnosis, but chest CT remains the reference examination to confirm it and to exclude tracheobronchial or esophageal perforation. This case underlines the value of early recognition, strict monitoring, and an adapted imaging assessment.

Acknowledgements

The authors thank the emergency and intensive care teams of the Military Hospital of Guelmim who contributed to the care of this patient. No specific funding was received for this work.

Conflict of Interest

The authors declare that there is no conflict of interest.

Ethical Statements

Ethical approval: Ethical approval was not required for this case report.

Informed consent: Written informed consent was obtained from the patient for the publication of this case report and the accompanying images.

References

1. Hamman L. Spontaneous mediastinal emphysema. Bull Johns Hopkins Hosp. 1939;64:1-21.
2. Macklin MT, Macklin CC. Malignant interstitial emphysema of the lungs and mediastinum as an important occult complication in many respiratory diseases and other conditions: an interpretation of the clinical literature in the light of laboratory experiment. Medicine (Baltimore). 1944;23(4):281-358.

3. Newcomb AE, Clarke CP. Spontaneous pneumomediastinum: a benign curiosity or a significant problem? Chest. 2005;128(5):3298-302. doi:10.1378/chest.128.5.3298
4. Caceres M, Ali SZ, Braud R, Weiman D, Garrett HE Jr. Spontaneous pneumomediastinum: a comparative study and review of the literature. Ann Thorac Surg. 2008;86(3):962-6. doi:10.1016/j.athoracsur.2008.04.067
5. Kouritas VK, Papagiannopoulos K, Lazaridis G, Baka S, Mpoukovinas I, Karavasilis V, *et al.,*Pneumomediastinum. J Thorac Dis. 2015;7(Suppl 1):S44-9. doi:10.3978/j.issn.2072-1439.2015.01.11
6. Bakhos CT, Pupovac SS, Ata A, Fantauzzi JP, Fabian T. Spontaneous pneumomediastinum: an extensive workup is not required. J Am Coll Surg. 2014;219(4):713-7. doi:10.1016/j.jamcollsurg.2014.06.001
7. Murayama S, Gibo S. Spontaneous pneumomediastinum and Macklin effect: overview and appearance on computed tomography. World J Radiol. 2014;6(11):850-4. doi:10.4329/wjr.v6.i11.850
8. Macia I, Moya J, Ramos R, Morera R, Escrivà J, Fernández E, *et al.,*Spontaneous pneumomediastinum: 41 cases. Eur J Cardiothorac Surg. 2007;31(6):1110-4.
9. Takada K, Matsumoto S, Hiramatsu T, Kojima E, Shizu M, Okachi S, *et al.,* Management of spontaneous pneumomediastinum based on clinical experience of 25 cases. Respir Med. 2008;102(9):1329-34. doi:10.1016/j.rmed.2008.03.023
10. Kim KS, Jeon HW, Moon Y, Kim YD, Ahn MI, Park JK, *et al.,* Clinical experience of spontaneous pneumomediastinum: diagnosis and treatment. J Thorac Dis. 2015;7(10):1817-24.
11. Kelly S, Hughes S, Nixon S, Paterson-Brown S. Spontaneous pneumomediastinum (Hamman's syndrome). Surgeon. 2010;8(2):63-6.