Scholars Journal of Medical Case Reports
Abbreviated Key Title: Sch J Med Case Rep
ISSN 2347-9507 (Print) | ISSN 2347-6559 (Online)
Journal homepage: https://saspublishers.com

OPEN ACCESS

Gastroenterology

Post-Traumatic Cavernous Internal Carotid Artery Pseudoaneurysm Revealed by Delayed Massive Epistaxis Successfully Treated by Covered Stent: A Case Report

Dr Zineb Berdi[1]*, Dr Ghita MEHRAZ[1], Dr Moad El Mekkaoui[1], Dr Zakaria El Hafi[1], Pr. Razika Bencheikh[1], Pr. Mohamed Anass Benbouzid[1], Pr. Leila Essakalli[1]

[1]Department of ENT and Head and Neck Surgery – Specialty Hospital / Ibn Sina University Hospital, Rabat, Morocco; Faculty of Medicine and Pharmacy / Mohammed V University, Rabat, Morocco

DOI: https://doi.org/10.36347/sjmcr.2026.v14i11.091 | **Received:** 22.08.2026 | **Accepted:** 26.10.2026 | **Published:** 23.11.2026

***Corresponding author:** Dr Zineb Berdi
Department of ENT and Head and Neck Surgery – Specialty Hospital / Ibn Sina University Hospital, Rabat, Morocco; Faculty of Medicine and Pharmacy / Mohammed V University, Rabat, Morocco

Abstract | **Case Report**

Background: Post-traumatic pseudoaneurysm of the cavernous internal carotid artery is a rare but potentially life-threatening vascular complication of craniofacial trauma. Because of its delayed clinical presentation, diagnosis is often challenging, with recurrent or massive epistaxis representing the most typical presenting symptom. Early recognition is essential to prevent catastrophic hemorrhage. ***Case presentation:*** We report the case of a 34-year-old man who sustained severe craniofacial trauma following a motorcycle accident. Initial computed tomography revealed complex fractures involving the greater wing of the sphenoid, optic canal, orbit, and facial skeleton, associated with epidural hematomas. Orbito-cerebral magnetic resonance imaging followed by digital subtraction angiography demonstrated a post-traumatic pseudoaneurysm of the left cavernous internal carotid artery associated with an ipsilateral middle meningeal artery aneurysm. The patient was initially lost to follow-up and presented five months later with recurrent episodes of massive epistaxis. Endovascular treatment using a covered stent achieved complete exclusion of the pseudoaneurysm while preserving carotid artery patency. Clinical and radiological follow-up at two years showed no recurrent hemorrhage or residual vascular abnormality. ***Conclusion:*** Delayed or recurrent epistaxis following craniofacial trauma, particularly in the presence of skull base or sphenoid fractures, should raise suspicion of a traumatic carotid pseudoaneurysm. Digital subtraction angiography remains the diagnostic gold standard, whereas endovascular reconstruction using covered stents offers an effective and vessel-preserving therapeutic option with excellent long-term outcomes.

Keywords: Traumatic pseudoaneurysm; Cavernous internal carotid artery; Massive epistaxis; Craniofacial trauma; Endovascular treatment; Covered stent.

Copyright © 2026 The Author(s): This is an open-access article distributed under the terms of the Creative Commons Attribution **4.0 International License (CC BY-NC 4.0)** which permits unrestricted use, distribution, and reproduction in any medium for non-commercial use provided the original author and source are credited.

INTRODUCTION

Post-traumatic pseudoaneurysm of the cavernous internal carotid artery is a rare but potentially fatal vascular complication of craniofacial trauma, and it often remains asymptomatic until a massive hemorrhage occurs.

It accounts for less than 1% of all intracranial aneurysms and most often follows high-energy trauma causing a skull base fracture, particularly of the sphenoid bone, or, more rarely, penetrating trauma. It results from a partial tear of the arterial wall, leading to the formation of a pulsatile hematoma that secondarily communicates with the vascular lumen.

Symptoms are often delayed by several days to several weeks after the initial trauma, which may cause a diagnostic delay before the lesion suddenly declares itself when it ruptures into the sphenoid sinus. Massive or recurrent epistaxis is one of the most dreaded modes of presentation, and is generally secondary to rupture of the pseudoaneurysm into the sphenoid sinus.

Early diagnosis is essential given the major risk of hemorrhage and the high mortality in the absence of appropriate management.

Over the past two decades, the management of these lesions has changed considerably thanks to the development of endovascular techniques.

We report a case of post-traumatic pseudoaneurysm of the cavernous internal carotid artery revealed by massive epistaxis following blunt head trauma, highlighting the diagnostic challenges and the endovascular therapeutic strategies for this rare entity, which led to a favorable outcome.

CASE REPORT

We report the case of a 34-year-old patient involved in a road traffic accident while riding a motorcycle, with an impact to the craniofacial and orbital region. The initial trauma was accompanied by transient loss of consciousness and post-traumatic vomiting.

On admission to the emergency department, the patient presented with marked left orbital edema, a significant decrease in ipsilateral visual acuity, and moderate unilateral left epistaxis.

Clinical examination revealed a frontal wound, a step-off bony deformity of the left hemiface, left subconjunctival hemorrhage, and marked ipsilateral eyelid edema.

Initial imaging included craniofacial computed tomography, which showed multiple fractures of the sphenoid bone involving the greater wing, with incarceration of a bone fragment in the optic canal and a fracture of the left superolateral orbital wall. Associated fractures of the zygomatic arch and of the left maxillary sinus were also noted, along with marked ipsilateral eyelid and cheek infiltration. Brain CT additionally showed two biconvex collections consistent with epidural hematomas.

Orbito-cerebral magnetic resonance imaging performed subsequently showed findings compatible with a traumatic false aneurysm of the left cavernous internal carotid artery, bulging into the ipsilateral sphenoid sinus.

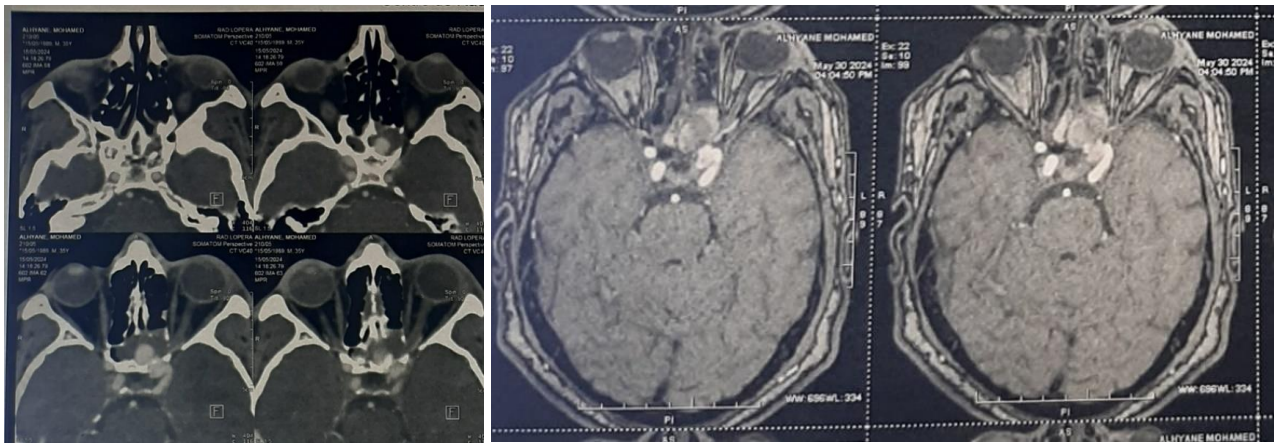

Figure 1: Craniofacial CT and orbito-cerebral MRI showing findings compatible with a traumatic false aneurysm of the left cavernous internal carotid artery, bulging into the ipsilateral sphenoid sinus

This abnormality was confirmed by cerebral angiography, which also revealed an associated aneurysm of the ipsilateral middle meningeal artery. Urgent endovascular management was then proposed.



Figure 2: Selective left internal carotid artery cerebral angiography showing a post-traumatic pseudoaneurysm of the intracavernous segment of the internal carotid artery, confirmed by opacification of a pseudoaneurysmal sac communicating with the parent artery

However, the patient was lost to follow-up before treatment.

Five months later, the clinical course was marked by persistent decreased visual acuity on the left and by three episodes of spontaneous, profuse epistaxis that resolved spontaneously. This prompted cerebral MR angiography, which confirmed the persistence of the false aneurysm of the left internal carotid artery.

The patient subsequently underwent endovascular treatment consisting of exclusion of the pseudoaneurysm by placement of a covered stent in the cavernous segment of the left internal carotid artery, achieving complete exclusion of the aneurysmal sac while preserving patency of the carotid axis.

Post-procedural control angiography showed complete exclusion of the false aneurysm with good stent patency and no residual leak.

The postoperative course was favorable, marked by the absence of recurrent epistaxis and by stability of the residual left visual deficit.

Radiological and clinical follow-up was carried out at 6 months, 1 year, and 2 years, with no clinical recurrence or secondary complication. A control MRI performed during follow-up showed no residual vascular abnormality and no sign of pseudoaneurysm recurrence.

DISCUSSION

Traumatic pseudoaneurysm of the cavernous internal carotid artery is a rare but particularly serious vascular complication of craniofacial trauma. It accounts for less than 1% of all intracranial aneurysms and most often results from high-energy trauma causing a fracture of the skull base, particularly of the sphenoid bone or the carotid canal [1,2]. Despite its low incidence, this lesion is associated with substantial morbidity and mortality because of the high risk of delayed rupture and catastrophic hemorrhage.

Unlike true aneurysms, a pseudoaneurysm is characterized by a partial or complete tear of the arterial wall, the aneurysmal sac being made up solely of perivascular tissue, organized thrombus, or reactive fibrous structures. This architecture explains its marked fragility and its tendency to enlarge progressively under arterial pressure before eventually rupturing [3]. In our case, the fracture of the greater wing of the sphenoid with extension to the optic canal is the most likely traumatic mechanism of the carotid injury. The close anatomical relationships between the intracavernous segment of the internal carotid artery, the cavernous sinus, and the sphenoid sinus explain the occurrence of rupture into the sphenoid sinus, responsible for massive epistaxis.

The interval between the initial trauma and clinical presentation is a well-known characteristic of traumatic pseudoaneurysms. In most published series, symptoms appear between a few days and several months after the trauma, with reported delays of up to six months or even longer [2,4]. This delayed course is attributed to the progressive formation of the pseudoaneurysmal cavity before its rupture. Our patient illustrates this course perfectly, since he presented with several episodes of massive epistaxis five months after the initial trauma, although the diagnosis had already been suspected during the initial hospitalization. This observation underlines the importance of rigorous follow-up in patients with a skull base fracture and suspected carotid injury, even in the absence of immediate symptoms.

Epistaxis is the most frequent and most feared mode of presentation of this condition. It generally occurs after rupture of the pseudoaneurysm into the sphenoid sinus and may be preceded by self-limited sentinel episodes of epistaxis. These episodes should be regarded as a true warning sign, since they often precede a potentially fatal hemorrhage [5]. Several authors therefore recommend that any delayed or recurrent epistaxis in a patient who has sustained craniofacial trauma, particularly in the presence of a sphenoid fracture, should prompt priority consideration of a carotid origin until proven otherwise. In our case, the three successive episodes of profuse epistaxis were the trigger for resuming investigations and treatment.

Imaging plays a central role in diagnosis. Craniofacial computed tomography is indispensable in the initial evaluation of trauma, as it identifies skull base fractures that may involve the course of the internal carotid artery. However, it does not always allow direct visualization of the pseudoaneurysm. MRI and MR angiography provide complementary information on the vascular structures, anatomical relationships, and possible intracranial complications [6]. Nevertheless, cerebral angiography with digital subtraction remains the diagnostic gold standard. In addition to its high spatial resolution, it allows precise characterization of the morphology of the pseudoaneurysm, identification of any associated vascular lesions, and immediate consideration of endovascular treatment. In our case, angiography not only confirmed the diagnosis but also revealed an ipsilateral middle meningeal artery aneurysm, illustrating the value of a complete vascular evaluation after severe trauma.

The therapeutic strategy has changed profoundly over the past two decades. Historically, treatment relied mainly on carotid ligation or direct surgical repair. However, these techniques were associated with high neurological morbidity, owing to the depth of the intracavernous segment and the complexity of skull base surgical approaches [7]. The development of interventional neuroradiology has profoundly changed the management of these lesions. Current options include therapeutic occlusion of the

internal carotid artery after occlusion testing, coil embolization, flow-diverting stents, and covered stents [8].

The therapeutic choice depends on several parameters: the size of the pseudoaneurysm, the width of the neck, the quality of the collateral circulation, the patient's clinical condition, and the possibility of preserving the carotid axis. In young patients, when the anatomy allows, conservative techniques are preferred in order to avoid the ischemic complications associated with carotid sacrifice. In our case, placement of a covered stent achieved immediate exclusion of the pseudoaneurysm while maintaining patency of the internal carotid artery. This technique has the major advantage of instantly isolating the aneurysmal sac from the arterial circulation, thereby reducing the risk of recurrent hemorrhage. Published series report high rates of technical and clinical success with a low incidence of complications when indications are properly selected [8–10].

Radiological follow-up is an essential step after endovascular treatment. Regular surveillance by MR angiography or angiography is recommended to verify stent patency and to exclude endoleak, in-stent thrombosis, or recurrence of the pseudoaneurysm. In our case, the controls performed at six months, one year, and two years confirmed complete and durable exclusion of the lesion without secondary complication, attesting to the efficacy of the treatment.

Finally, this case highlights the importance of a multidisciplinary approach involving ENT, neurosurgery, interventional neuroradiology, and ophthalmology teams. Any delayed or recurrent epistaxis in a patient with a history of craniofacial trauma, particularly in the presence of a sphenoid or skull base fracture, should lead to prompt vascular imaging. Early diagnosis allows appropriate endovascular management before a potentially fatal hemorrhage occurs.

CONCLUSION

Post-traumatic pseudoaneurysm of the cavernous internal carotid artery is an exceptional but formidable complication of craniofacial trauma because of its high risk of delayed massive hemorrhage. Its diagnosis relies on a high index of clinical suspicion, particularly in the setting of any recurrent or profuse epistaxis occurring after skull base trauma. Vascular imaging, and in particular digital subtraction cerebral angiography, remains indispensable to confirm the diagnosis, characterize the lesion, and plan the therapeutic strategy.

Our case illustrates the sometimes-delayed course of this complication and the value of prolonged surveillance in patients with sphenoid or carotid canal fractures. It also demonstrates the efficacy of endovascular treatment with a covered stent, which provides immediate and durable exclusion of the pseudoaneurysm while preserving internal carotid artery patency. Given the excellent clinical and radiological results obtained after two years of follow-up, this technique appears to be a treatment of choice in selected patients.

Finally, this case underscores the importance of multidisciplinary collaboration among ENT surgeons, neurosurgeons, interventional neuroradiologists, and ophthalmologists to ensure early diagnosis and prompt management of this rare but potentially fatal condition.

REFERENCES

1. Ahmed O, Raghuram K, Phan K, et al. Traumatic pseudoaneurysm of the cavernous carotid artery presenting with delayed epistaxis: a case report and review of literature. J Surg Case Rep. 2020;2020[12]:rjaa500.
2. Menon G, Sudhir J, Rao BRM. Post-traumatic cavernous carotid pseudoaneurysm presenting with delayed massive epistaxis. Cureus. 2018;10[9]:e3270.
3. Fontela PS, Tampieri D, Atkinson JD. Posttraumatic pseudoaneurysm of the intracavernous internal carotid artery presenting with massive epistaxis. J Trauma. 2006;60[4]:889-892.
4. Wang HS, Chen YL, Liang CL, et al. Endovascular management of traumatic internal carotid artery pseudoaneurysms. J Clin Neurosci. 2014;21[7]:1233-1238.
5. Cohen JE, Gomori JM, Segal R, et al. Results of endovascular treatment of traumatic intracranial aneurysms. Neurosurgery. 2008;63[3]:476-485.
6. Lee TS, Ducic Y, Gordin E, Stroman D. Management of carotid artery trauma. Craniomaxillofac Trauma Reconstr. 2014;7[3]:175-189.
7. Burlew CC, Biffl WL, Moore EE, et al. Blunt cerebrovascular injuries: redefining screening and management. Arch Surg. 2012;147[12]:1131-1137.
8. Cinar C, Bozkaya H, Oran I. Endovascular treatment of traumatic carotid artery injuries with covered stents. Diagn Interv Radiol. 2013;19[6]:473-479.
9. Briganti F, Leone G, Marseglia M, et al. Endovascular treatment of traumatic intracranial aneurysms: long-term outcomes. Neuroradiology. 2016;58[4]:403-410.
10. Saatci I, Cekirge HS. Covered stents for treatment of carotid cavernous lesions and traumatic pseudoaneurysms: indications, technique and outcomes. Interv Neuroradiol. 2017;23[3]:250-258.