Scholars Journal of Medical Case Reports
Abbreviated Key Title: Sch J Med Case Rep
ISSN 2347-9507 (Print) | ISSN 2347-6559 (Online)
Journal homepage: https://saspublishers.com

OPEN ACCESS

Medicine

Cryptococcal Meningoencephalitis Mimicking Tuberculous Meningitis in an HIV-Negative Patient with Crohn's Disease: A Case Report

Mohammed Raiteb[1*], Mohamed Er- Rejrragi[1], Zakaria Chahbi[1], Meriem Mouharir[1], Said Kaddouri[1], Redouane Moutaj[2], Hassan Qacif[1], Mohamed Zyani[1]

[1]Department of Internal Medicine, Avicenne Military Hospital, Marrakech, Morocco, Faculty of Medicine and Pharmacy of Marrakech - Cadi Ayyad University. Marrakech. Morocco
[2]Department of Parasitology, Avicenne Military Hospital, Marrakech, Morocco, Faculty of Medicine and Pharmacy of Marrakech - Cadi Ayyad University. Marrakech. Morocco

DOI: https://doi.org/10.36347/sjmcr.2026.v14i11.094 | **Received:** 23.09.2026 | **Accepted:** 18.11.2026 | **Published:** 23.11.2026

***Corresponding author:** Mohammed Raiteb
Department of Internal Medicine, Avicenne Military Hospital, Marrakech, Morocco, Faculty of Medicine and Pharmacy of Marrakech - Cadi Ayyad University. Marrakech. Morocco

Abstract **Case Report**

Cryptococcal meningoencephalitis in HIV-negative patients is often diagnosed late, especially where tuberculosis is endemic. We report the case of a 63-year-old man with type 2 diabetes and Crohn's disease who had received high-dose prednisone, stopped one month before admission, and was still taking azathioprine and sulfasalazine. He presented with a 15-day history of progressive headache, feverishness, and confusion. Cerebrospinal fluid (CSF) analysis showed lymphocytic meningitis with low glucose, and brain magnetic resonance imaging showed white matter nodular lesions, basal meningeal enhancement, and a ring-enhancing putaminal lesion. The lymphocyte count was 600/mm³ and HIV serology was negative. Tuberculous meningitis was suspected and four-drug antituberculosis therapy was started, but his condition worsened. On two lumbar punctures, India ink, cultures, multiplex polymerase chain reaction including *Cryptococcus neoformans/gattii*, and Xpert MTB/RIF Ultra were negative. Cryptococcal antigen, tested by latex agglutination, was positive in CSF and blood, and cryptococcal meningoencephalitis was diagnosed. Because flucytosine is not available in Morocco, he received liposomal amphotericin B plus fluconazole for 14 days, followed by fluconazole consolidation and 12 months of maintenance therapy. His neurological examination was normal by day 10. The antigen remained positive and CSF abnormalities persisted for several months before the CSF gradually normalized. No relapse was observed during follow-up. This case shows that iatrogenic immunosuppression in inflammatory bowel disease can be enough to cause cryptococcosis, that the disease may closely mimic tuberculous meningitis, and that negative microscopy, culture, and PCR do not rule it out. In an immunosuppressed patient with chronic lymphocytic meningitis, cryptococcal antigen should be tested at the first lumbar puncture, even in tuberculosis-endemic settings.

Keywords: Cryptococcosis, Cryptococcal meningitis, Cryptococcal antigen, HIV-negative, Crohn disease, Azathioprine, Tuberculous meningitis, Liposomal amphotericin B.

Copyright © 2026 The Author(s): This is an open-access article distributed under the terms of the Creative Commons Attribution **4.0 International License (CC BY-NC 4.0)** which permits unrestricted use, distribution, and reproduction in any medium for non-commercial use provided the original author and source are credited.

INTRODUCTION

Cryptococcosis is an invasive fungal infection caused by encapsulated yeasts [1] of the *Cryptococcus neoformans* and *Cryptococcus gattii* species complexes [2]. It is an opportunistic infection, which takes hold when host immunity fails [3,4,5]. Meningoencephalitis is both its most frequent and its most lethal form [2,6]. In 2022, the World Health Organization listed *C. neoformans* as a top fungal priority pathogen, and cryptococcal meningoencephalitis still kills 24% to 47% of patients within 10 weeks [6].

Advanced HIV infection remains the dominant risk factor worldwide, especially in low- and middle-income countries [2,4,6]. However, cryptococcosis is increasingly reported in HIV-negative patients: solid organ transplant recipients, patients with cancer or rheumatic diseases, those receiving corticosteroids or other immunosuppressive drugs, and even apparently immunocompetent hosts [2,6,7]. In high-income countries, they account for about one-third of cases, and up to 30% of them die despite appropriate therapy [1,8].

We report the case of an HIV-negative patient with Crohn's disease who was first treated for tuberculous meningitis. The diagnosis of cryptococcal meningoencephalitis finally rested on antigen detection alone.

Case Report

A 63-year-old man, a shopkeeper from Morocco, had been followed for five years for type 2 diabetes treated with glimepiride. He was also followed for Crohn's disease treated with sulfasalazine. Five months before admission, he had been hospitalized for a Crohn's disease flare. He had received prednisone 60 mg daily for 21 days, gradually tapered and stopped one month before admission, along with maintenance therapy with azathioprine and sulfasalazine. He had no exposure to birds.

The patient was admitted to our department for confusion. His symptoms had started 15 days earlier with a progressively worsening headache, along with feverishness and a decline in his general condition.

On admission, he was afebrile and his vital signs were normal. Meningeal signs were subtle: mild neck stiffness, a faintly positive Brudzinski sign, and a negative Kernig sign. His Glasgow Coma Scale score was 15. He was confused, with memory impairment, behavioral changes, and disorientation to time and place. He reported diplopia, without oculomotor palsy or involvement of other cranial nerves. There was no focal neurological deficit. Funduscopic examination was normal. There were no clinical signs of intracranial hypertension.

Noncontrast head computed tomography (CT) was normal. The cerebrospinal fluid (CSF) was clear. Analysis showed 92 leukocytes/mm³ (90% lymphocytes), a protein level of 1.50 g/L, and a glucose level of 0.48 g/L with a blood glucose of 2.38 g/L (CSF-to-blood glucose ratio, 0.20). Direct examinations (Gram and Ziehl-Neelsen stains, India ink), cultures (bacterial, Sabouraud, and Löwenstein-Jensen media), multiplex meningitis polymerase chain reaction (PCR) including *Cryptococcus neoformans/gattii* (FilmArray Meningitis/ Encephalitis panel), and the Xpert MTB/RIF Ultra assay were all negative.

Brain magnetic resonance imaging (MRI) showed multiple nodular lesions in the supratentorial and infratentorial white matter, hyperintense on T2-weighted and FLAIR images, without restricted diffusion or mass effect. There was diffuse micronodular and gyriform meningeal enhancement, most prominent at the skull base. A 4.7-mm left putaminal lesion showed ring enhancement. There was no hydrocephalus (Figure 1).

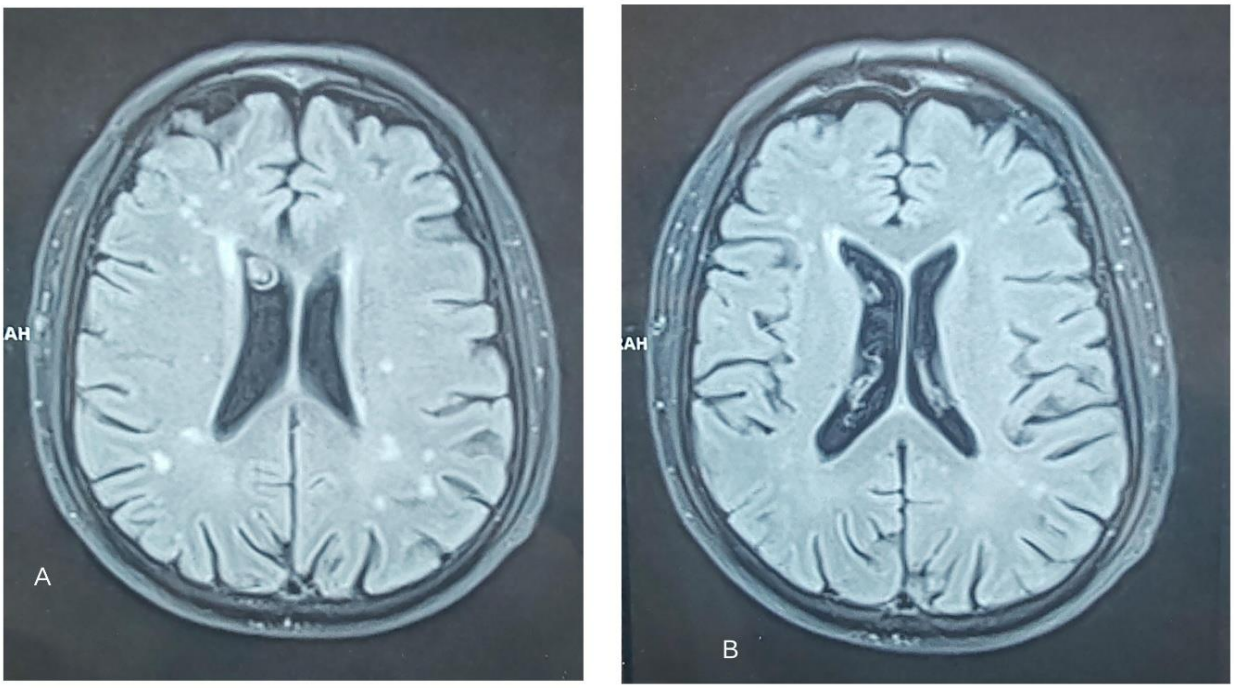

Figure 1: Brain magnetic resonance imaging at admission. Axial fluid-attenuated inversion recovery (FLAIR) images (A, B)

The complete blood count showed lymphopenia (600/mm³) and macrocytic anemia (hemoglobin, 12.2 g/dL; mean corpuscular volume [MCV], 104.7 fL). C-reactive protein (CRP) was 5.2 mg/L and procalcitonin 0.05 ng/mL. Glycated hemoglobin (HbA1c) was 7.0%. Folate and vitamin B12 levels were normal. Serologic tests for human immunodeficiency virus (HIV), syphilis, brucellosis, Lyme disease, and viral hepatitis were negative. Serum protein electrophoresis was normal. The CD4+ T-cell count was not measured.

Tuberculous meningitis was the most likely diagnosis, given the high endemicity of tuberculosis in our country, the patient's immunosuppression, the chronic lymphocytic meningitis with low CSF glucose, and the MRI findings. Four-drug antituberculosis therapy with rifampin, isoniazid, pyrazinamide, and ethambutol was started, and azathioprine was stopped because of the lymphopenia and the ongoing infection. We did not add adjunctive corticosteroids, since the diagnosis of tuberculous meningitis had not been confirmed. Cryptococcal meningitis was ruled out at that stage, because India ink, Sabouraud culture, and multiplex PCR for *Cryptococcus* were negative.

Despite antituberculosis therapy, his neurological status did not improve and his general condition worsened. A repeat lumbar puncture showed persistent meningitis (144 leukocytes/mm³, 99% lymphocytes; protein, 1.57 g/L; CSF-to-blood glucose ratio, 0.30). As on the first lumbar puncture, direct examinations, cultures, multiplex meningitis PCR (FilmArray Meningitis/Encephalitis panel), and Xpert MTB/RIF Ultra were negative. The interferon-gamma release assay (QuantiFERON-TB Gold) was negative. Cryptococcal antigen, tested by latex agglutination, was positive in both CSF and blood (qualitative test, without titration). Because this result did not fit with the other tests, we suspected a false positive. Rheumatoid factor, requested at that point, was negative.

Based on the positive cryptococcal antigen in the CSF, a diagnosis of cryptococcal meningoencephalitis was made. Antituberculosis therapy was stopped. Induction therapy with liposomal amphotericin B (3 mg/kg/day) plus fluconazole (800 mg/day) was given for 14 days; flucytosine is not available in our country. Consolidation consisted of fluconazole 400 mg/day for 8 weeks, followed by maintenance fluconazole 200 mg/day for 12 months. Amphotericin B was well tolerated, apart from hypokalemia that was easily corrected.

During induction, the patient gradually improved. By day 10 of antifungal therapy, his neurological examination was normal, with resolution of the headache, meningeal signs, confusion, and disorientation. At the end of induction, the CSF contained 65 leukocytes/mm³, with a protein level of 1.18 g/L, a glucose level of 0.60 g/L, and a CSF-to-blood glucose ratio of 0.50. India ink and Sabouraud culture were still negative; cryptococcal antigen remained positive. Post-induction MRI showed persistent meningeal enhancement and two ring-enhancing lesions in the left putamen and left caudate nucleus (4.7 and 3.8 mm). The patient was discharged home. His Crohn's disease was in remission, and azathioprine was not restarted.

Two months after the start of treatment, MRI showed fewer nodular lesions, stable ring-enhancing lesions, and persistent basal meningeal enhancement.

The patient remained asymptomatic throughout follow-up. CSF cell count and protein levels gradually decreased (Table 1). At month 4, MRI showed persistent nodular lesions and basal meningeal enhancement. The caudate lesion had disappeared. The putaminal lesion now appeared lacunar, surrounded by gliosis, with no enhancement or restricted diffusion, consistent with a sequela (Figure 2). At month 13, the CSF contained 1 cell/mm³, with a protein level of 0.40 g/L and a CSF-to-blood glucose ratio of 0.60. India ink and cultures had remained negative on every lumbar puncture. MRI at month 13 was unchanged from month 4 (Figure 3).

Table 1: Changes in cerebrospinal fluid parameters

Time point*	Context	Leukocytes/mm³ (% lymphocytes)	Protein (g/L)	Glucose, g/L (CSF-to-blood glucose ratio)	Cryptococcal antigen
D−18	Start of antituberculosis therapy	92 (L 90%)	1.50	0.48 (0.20)	Not tested
D0	Start of antifungal therapy; antituberculosis therapy stopped	144 (L 99%)	1.57	0.63 (0.30)	Positive
End of induction	Switch to fluconazole (consolidation)	65 (L 95%)	1.18	0.60 (0.50)	Positive
M2	Consolidation	56 (L 95%)	1.20	2.34 (0.80)	Positive
M4	Maintenance	37 (L 95%,)	1.05	0.87 (0.70)	Not tested
M8	Maintenance	23 (L 95%)	0.60	0.83 (0.70)	Not tested
M14	Maintenance (final month of maintenance therapy)	1	0.40	0.78 (0.60)	Not tested

*Relative to the start of antifungal therapy (D0). D, day; M, month; L, lymphocytes; CSF, cerebrospinal fluid.

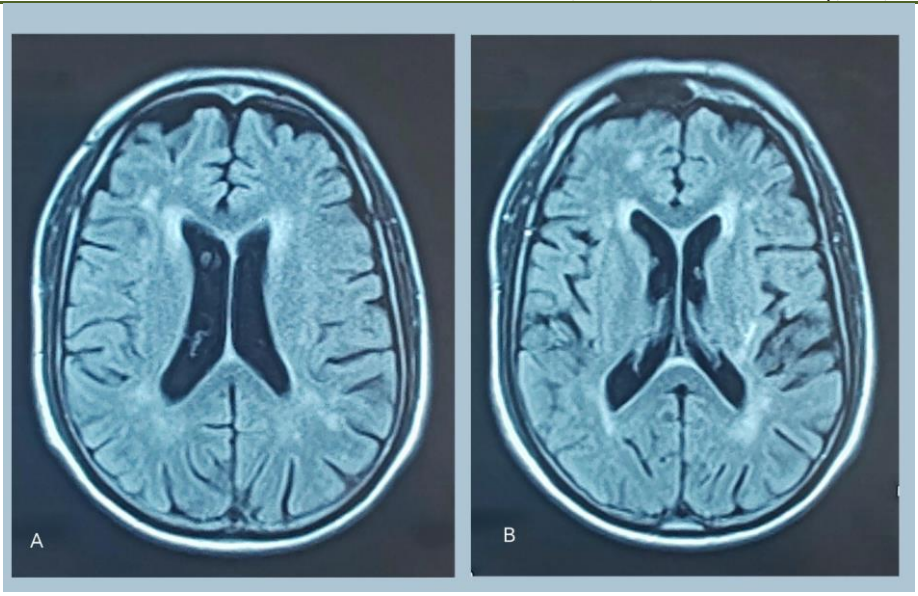

Figure 2: Follow-up brain magnetic resonance imaging at month 4. Axial T2-weighted FLAIR images at levels matched to Figure 1 (A, B)

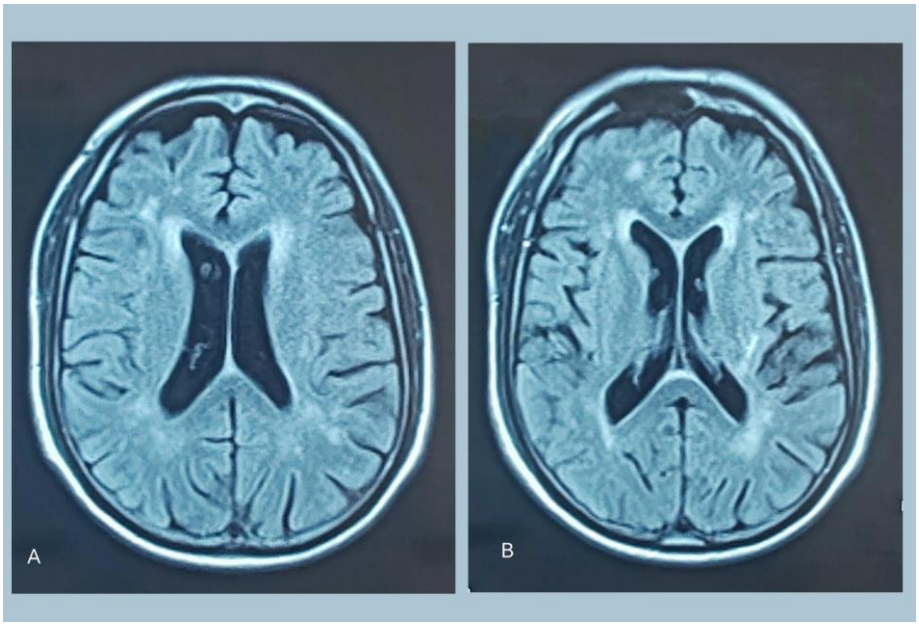

Figure 3: Follow-up brain magnetic resonance imaging at month 13. Axial T2-weighted FLAIR images at levels matched to Figure 1 (A, B)

Fluconazole was stopped after one year of maintenance therapy. Crohn's disease remained in remission on sulfasalazine alone, despite azathioprine withdrawal. No relapse was observed after 14 months of follow-up from the start of antifungal therapy. He had no relapse two months after fluconazole was stopped.

Study setting, ethics, and consent

The patient was hospitalized in the Infectious Diseases Unit of the Department of Internal Medicine at the Avicenne Military Hospital in Marrakech, The patient gave written consent for the publication of this case.

DISCUSSION

Our case illustrates three pitfalls in HIV-negative patients: an iatrogenic immunosuppression that is easy to underestimate, a presentation that mimics tuberculosis, and a diagnosis that may rest on antigen detection alone, because microscopy, culture, and PCR may all be negative.

Moroccan data on HIV-negative patients are scarce: in a laboratory series from Rabat, they accounted for only 5 of 40 cases collected over 21 years [4]. In these patients, diagnosis is often delayed because the onset is insidious and the disease is rarely suspected [2].

Our patient had accumulated several risk factors. Most HIV-negative patients with cryptococcosis have an underlying condition, and corticosteroid therapy comes first [1]. In inflammatory bowel disease, corticosteroids and azathioprine each roughly triple the risk of opportunistic infection, and combining two or more immunosuppressive drugs raises the odds ratio to 14.5 [3]. The same study counted any drug taken in the 3 months before infection. Risk was highest in patients first seen after age 50 and was linked to lower lymphocyte counts rather than to the azathioprine dose [3]. Our patient met all of these conditions: he was 63 years old, he had stopped high-dose prednisone 1 month before admission, he was still taking azathioprine, and his lymphocyte count was 600/mm³, with a macrocytosis suggesting a thiopurine effect. Immunosuppressive therapy is a recognized host factor for cryptococcosis in the EORTC/MSGERC consensus definitions [9].

Everything initially pointed to tuberculous meningitis: subacute headache, confusion, lymphocytic meningitis with low cerebrospinal fluid (CSF) glucose, immunosuppression, and basal meningeal enhancement, in a country where tuberculosis is endemic. This confusion is common in HIV-negative patients, and it is costly, because diagnostic delay worsens the prognosis [7]. Imaging is of little help. In the series by Qu *et al.,* meningeal enhancement and hydrocephalus were as frequent in one disease as in the other, whereas white matter lesions resembling demyelination were more common in cryptococcal meningitis [7]. *Cryptococcus* spreads from the meninges along the perivascular spaces to the basal ganglia [2,5], and lesions enhance when cell-mediated immunity is preserved [5]. Even advanced MRI sequences may fail to distinguish cryptococcal from tuberculous lesions [5]. The white matter nodules and the ring-enhancing putaminal lesion seen at admission, as well as the caudate lesion that appeared later, fit this pattern well. Patro et al. reported a strikingly similar course: empirical antituberculous therapy, clinical progression, negative CSF cultures, and finally a positive CSF cryptococcal antigen [5]. Looking back, the antigen should have been tested at the first lumbar puncture. The global guideline places antigen testing in CSF and blood, together with microscopy, culture, and imaging, at the center of the diagnosis of cryptococcosis, whereas screening is supported only in people living with HIV [6]. In an immunosuppressed patient with chronic lymphocytic meningitis, we believe the antigen belongs in the first workup, even where tuberculosis is endemic.

India ink, cultures, and the multiplex PCR panel were negative on every sample. India ink is less sensitive in HIV-negative patients (30%--72%) [2]. In the 306 HIV-negative patients of Pappas *et al.,* it was positive in only half of the patients tested, and CSF culture in 89% of those with central nervous system disease [1]. With latex agglutination, the technique available in our laboratory, Qu et al. detected the antigen in 99.2% of their HIV-negative patients, compared with 77.8% for India ink and 79.3% for culture [7]. Antigen sensitivity reaches 87%--100% in CSF and 94%--100% in serum, regardless of HIV status, and both false-negative and false-positive results are uncommon [2]. Rheumatoid factor was negative in our patient. Under the EORTC/MSGERC definitions, cryptococcal antigen in CSF or blood confirms proven cryptococcosis [9]. Likewise, a positive antigen with a compatible presentation was a sufficient case definition in the series by Pappas et al. [1]. As for the FilmArray meningitis/encephalitis panel, *C. neoformans/gattii* is among the targets with the highest proportions of false-negative results [10]. Most false negatives occurred in previously treated patients, yet the authors conclude that PCR should not replace antigen testing [10]. Finally, laboratory series built on microscopy and culture, such as the Rabat series in which India ink and culture were positive in every case, may under-represent paucifungal forms like ours [4].

Flucytosine is not available in Morocco, so we combined liposomal amphotericin B with fluconazole, an accepted alternative when flucytosine cannot be obtained [2,6]. For HIV-negative, non-transplant patients, the global guideline recommends at least 2 weeks of induction, extended if CSF cultures remain positive or symptoms persist [6]. Most experts, however, favor a longer course, typically 4 to 6 weeks, in this population [2], and the guideline itself suggests 4 to 6 weeks when cryptococcomas are present [6]. We stopped induction at 14 days because cultures had always been negative, the neurological examination was normal by day 10, and the ring-enhancing lesions measured less than 5 mm. Consolidation and maintenance therapy with fluconazole followed the guideline [6].

The antigen was still positive at the end of induction and at month 2, although the patient had recovered. This should not be alarming: antigen titers correlate poorly with outcome and may remain elevated for more than a year [2], and the guideline advises against escalating therapy for persistent antigenemia or abnormal CSF chemistry [6]. CSF pleocytosis and elevated protein also persisted for several months, while cultures stayed negative. A plausible explanation is the intrathecal Th1 response described by Panackal *et al.,* which persists after microbiological control, driven by fungal antigens released during treatment, for as long as antigen remains detectable [8]. Likewise, cryptococcal lesions may persist on imaging for years and should not guide treatment duration [2,6].

Our patient had two independent predictors of poor outcome, age over 60 years and altered mental status [7]. In the series by Pappas *et al.,* overall mortality was 30% and relapse occurred in 4% of patients [1]. Mortality reached 45% in the Rabat series, which consisted mostly of patients living with HIV [4]. Yet he recovered without neurological deficit and was still relapse-free 2 months after fluconazole was stopped.

Our report has several limitations. CSF opening pressure was not measured, nor was the CD4 count. The antigen was tested qualitatively by latex agglutination, without titration or lateral flow assay. The species could not be identified because cultures remained negative.

In developing countries, cryptococcal and tuberculous meningitis are the two most common causes of chronic infectious meningitis, and their clinical, CSF, and imaging features overlap [5,7]. Clinicians working where tuberculosis is endemic should therefore keep cryptococcosis in mind and test for the antigen early.

CONCLUSION

Cryptococcosis is not limited to people living with HIV. In our patient, corticosteroids, azathioprine, lymphopenia, and age were enough. In a country where tuberculosis is endemic, chronic lymphocytic meningitis in an immunosuppressed patient should prompt cryptococcal antigen testing from the first lumbar puncture, even when the clinical picture and imaging point to tuberculosis. Negative India ink, culture, and PCR do not rule out the diagnosis; a positive antigen is enough to confirm it. During follow-up, a persistent antigen and a slowly normalizing CSF do not mean treatment failure. Finally, even without flucytosine, liposomal amphotericin B combined with fluconazole led to a favorable outcome.

Conflict of Interest: The authors declare no conflict of interest.

Funding: None.

REFERENCES

1. Pappas, P. G., Perfect, J. R., Cloud, G. A., Larsen, R. A., Pankey, G. A., Lancaster, D. J., Henderson, H., Kauffman, C. A., Haas, D. W., Saccente, M., Hamill, R. J., Holloway, M. S., Warren, R. M., & Dismukes, W. E. (2001). Cryptococcosis in human immunodeficiency virus-negative patients in the era of effective azole therapy. *Clinical Infectious Diseases, 33*(5), 690–699. https://doi.org/10.1086/322597
2. Beardsley, J., Sorrell, T. C., & Chen, S. C.-A. (2019). Central nervous system cryptococcal infections in non-HIV infected patients. *Journal of Fungi, 5*(3), Article 71. https://doi.org/10.3390/jof5030071
3. Toruner, M., Loftus, E. V., Jr., Harmsen, W. S., Zinsmeister, A. R., Orenstein, R., Sandborn, W. J., Colombel, J.-F., & Egan, L. J. (2008). Risk factors for opportunistic infections in patients with inflammatory bowel disease. *Gastroenterology, 134*(4), 929–936. https://doi.org/10.1053/j.gastro.2008.01.012
4. Bandadi, F. Z., Raiss, C., Moustachi, A., Lyagoubi, M., & Aoufi, S. (2019). Quarante cas de cryptococcose neuroméningée diagnostiqués en 21 ans au laboratoire de parasitologie de l'hôpital Ibn Sina de Rabat. *Pan African Medical Journal, 33*, Article 249. https://doi.org/10.11604/pamj.2019.33.249.18011
5. Patro, S. N., Kesavadas, C., Thomas, B., Kapilamoorthy, T. R., & Gupta, A. K. (2009). Uncommon presentation of intracranial cryptococcal infection mimicking tuberculous infection in two immunocompetent patients. *Singapore Medical Journal, 50*(4), e133–e137.
6. Chang, C. C., Harrison, T. S., Bicanic, T. A., Chayakulkeeree, M., Sorrell, T. C., Warris, A., Hagen, F., Spec, A., Oladele, R., Govender, N. P., Chen, S. C., Mody, C. H., Groll, A. H., Chen, Y. C., Lionakis, M. S., Alanio, A., Castañeda, E., Lizarazo, J., Vidal, J. E., . . . Perfect, J. R. (2024). Global guideline for the diagnosis and management of cryptococcosis: An initiative of the ECMM and ISHAM in cooperation with the ASM. *The Lancet Infectious Diseases, 24*(8), e495–e512. https://doi.org/10.1016/S1473-3099(23)00731-4
7. Qu, J., Zhou, T., Zhong, C., Deng, R., & Lü, X. (2017). Comparison of clinical features and prognostic factors in HIV-negative adults with cryptococcal meningitis and tuberculous meningitis: A retrospective study. *BMC Infectious Diseases, 17*, Article 51. https://doi.org/10.1186/s12879-016-2126-6
8. Panackal, A. A., Wuest, S. C., Lin, Y.-C., Wu, T., Zhang, N., Kosa, P., Komori, M., Blake, A., Browne, S. K., Rosen, L. B., Hagen, F., Meis, J., Levitz, S. M., Quezado, M., Hammoud, D., Bennett, J. E., Bielekova, B., & Williamson, P. R. (2015). Paradoxical immune responses in non-HIV cryptococcal meningitis. *PLoS Pathogens, 11*(5), Article e1004884. https://doi.org/10.1371/journal.ppat.1004884
9. Donnelly, J. P., Chen, S. C., Kauffman, C. A., Steinbach, W. J., Baddley, J. W., Verweij, P. E., Clancy, C. J., Wingard, J. R., Lockhart, S. R., Groll, A. H., Sorrell, T. C., Bassetti, M., Akan, H., Alexander, B. D., Andes, D., Azoulay, E., Bialek, R., Bradsher, R. W., Jr., Bretagne, S., . . . Pappas, P. G. (2020). Revision and update of the consensus definitions of invasive fungal disease from the European Organization for Research and Treatment of Cancer and the Mycoses Study Group Education and Research Consortium. *Clinical Infectious Diseases, 71*(6), 1367–1376. https://doi.org/10.1093/cid/ciz1008
10. Tansarli, G. S., & Chapin, K. C. (2020). Diagnostic test accuracy of the BioFire® FilmArray® meningitis/encephalitis panel: A systematic review and meta-analysis. *Clinical Microbiology and Infection, 26*(3), 281–290. https://doi.org/10.1016/j.cmi.2019.11.016