

## Lipoma of the Corpus Callosum: Case Report

S. Outaghyame<sup>1\*</sup>, A. Garmane<sup>1</sup>, B. Boutakiout<sup>1</sup>, M. Ouali Idrissi<sup>1</sup>, N. Cherif Idrissi El Ganouni<sup>1</sup>

<sup>1</sup>Department of Radiology, UHC Mohamed VI, Marrakech, Morocco

DOI: [10.36347/sjmcr.2021.v09i09.020](https://doi.org/10.36347/sjmcr.2021.v09i09.020)

| Received: 13.08.2021 | Accepted: 19.09.2021 | Published: 25.09.2021

\*Corresponding author: S. Outaghyame

### Abstract

### Case Report

Lipoma of the corpus callosum is a very rare birth defect, which can be associated with various degrees of dysgenesis of the corpus callosum. Its extension to the lateral ventricle is even rarer. It is often asymptomatic, but it can be presented by epilepsy, hemiplegia, dementia or simple headaches. Computed tomography scan (CT-Scan) and magnetic resonance imaging allow it's diagnosis. We report the case of an 18-year-old girl suffering from simple headache, victim of a craniofacial trauma, thus, a lipoma of the corpus callosum with extension to the lateral ventricle was discovered.

**Keywords:** Intracranial lipoma, corpus callosum lipoma, CT.

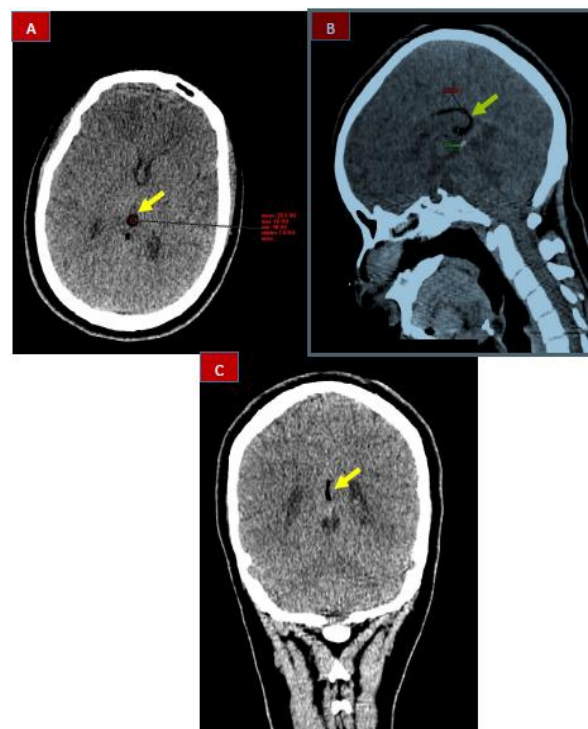
**Copyright © 2021 The Author(s):** This is an open-access article distributed under the terms of the Creative Commons Attribution 4.0 International License (CC BY-NC 4.0) which permits unrestricted use, distribution, and reproduction in any medium for non-commercial use provided the original author and source are credited.

## INTRODUCTION

Intracranial lipomas are congenital malformative lesions considered as very rare, less than 0.1% of intracranial tumors [1]. They are considered heterotopias rather than tumors since they are histologically composed of normal fat cells, but anatomically displaced [2]. They occur mainly in the pericallosal region (45%) [3]. However, lipomas of the corpus callosum only represent 5% of callosum tumors [3]. They are associated in more than half of cases with congenital malformations such as agenesis / dysgenesis of the corpus callosum [1]. Most lipomas of the corpus callosum are asymptomatic and are discovered incidentally. Their prognosis and symptoms depend on the associated malformation.

## PATIENT AND OBSERVATION

This is an 18-year-old patient with no notable pathological history, who got to the emergency department for a craniofacial trauma, with initial loss of consciousness, without any other particular signs. The neurological examination was normal, and the patient underwent a brain CT scan. The CT revealed (Figure 1): the presence of a midline fatty density formation, occupying the posterior part of the corpus callosum and extending to the body, measuring 6.6 mm in thickness, and extending to the left lateral ventricle, without any other associated lesions.



**Figure 1: (A, B, C): Spontaneous contrast brain CT, in axial, coronal and sagittal slices, showing: a fatty density formation of the midline, occupying the posterior part of the corpus callosum and lengthening to the body, measuring 6.6 mm thick (splenium), and extends to the left lateral ventricle**

## DISCUSSION

Intracranial lipomas are congenital malformative lesions considered as very rare, less than 0.1% of intracranial tumors. These are differentiation abnormalities of the mesenchymal tissue of the primary meninge. They were first described in 1818 by Meckel (chiasmatic lipoma), and in 1856 by Rokitansky who described a pericallosal lipoma with agenesis of the corpus callosum [1].

They are located in the midline in 90% of cases, and the most frequent site is the dorsal pericallosal region [3]. However, although they are located in 45% of cases in the corpus callosum, lipomas of the corpus callosum only represent 5% of tumors callosum [3]. They are often associated with other anomalies in the differentiation of the median structures, in particular with hypogenesis or agenesis of the corpus callosum, which are found in 90% of anterior lipomas and in 30% of posterior lipomas [1].

The precise etiopathogenesis of intracranial lipomas is still a subject of discussion. Historically, several theories regarding the histogenesis of these lesions have been put forward, including: hypertrophy of pre-existing adipose tissue in the meninges, metaplasia of meningeal connective tissue, heterotopic malformation of dermal origin, and pseudotumor derived from the meninges primitive. Today, it is accepted that these lipomas result from the abnormal persistence and mal-differentiation of the primitive meninge, which normally resolves between the 8th and the 10th week of gestation [1]. Other abnormalities related to the presence of intracranial lipomas include agenesis of the corpus callosum (the most common), agenesis of the cerebellar vermis, pituitary tumors, acoustic schwannomas, and other intracranial lipomas more often located in the plexus lateral ventricular choroid [1, 2, 4].

Corpus callosum lipomas are morphologically classified into two groups [1]: anterior (tubulonodular) lipomas: they are rounded or lobular and are generally > 2cm thick. They are frequently associated with hypogenesis / agenesis of the corpus callosum, abnormalities of the frontal lobes, calcifications, and / or ocular abnormalities. The tubulonodular variety can extend into the choroid plexuses of the lateral ventricles; Posterior lipomas (curvilinear): These are thin and elongated along the margin of the corpus callosum, and are usually <1 cm thick. They exist right behind the splenium and are less often associated with corpus callosum abnormalities and / or other encephalic abnormalities.

They are often encountered in the pediatric population and young adults, based on brain imaging, either incidentally, or following to the exploration of the symptoms they cause [5]. Currently, with the increasing use of prenatal ultrasound, more cases are

detected, starting from the 26th week of gestation [1]. Isolated lipomas from the corpus callosum are asymptomatic. Clinical manifestations such as seizures, mental disorders, hemiparesis and headache are often secondary to the concomitant abnormalities of the nervous tissue. One of the most common symptoms is epilepsy: when present, it appears before the age of 15, and is often partial and severe. They can also cause obstructive hydrocephalus [1].

The imaging is the main source of the diagnosis of corpus callosum lipomas. X-rays of the skull may show curvilinear calcifications, especially in the tubulonodular variety. On computed tomography, these lipomas appear as lumps of fat density (-80 to -110 HU), which may contain peripheral calcifications (the tubulonodular variety may present a peripheral curvilinear calcification sometimes called a "bracket sign" on reconstructed coronal images) [1]. MRI is thus the examination of choice not only to characterize the extension of the lipoma, but also to search for frequently associated agenesis / dysgenesis of the corpus callosum. It is not surprising that these lumps follow the intensity of the fat signal on all the sequences: thus they appear in hyper T1 and T2, with fall of the signal on the sequences of FATSAT.

As a whole, there is few differential diagnosis to be evoked in front of these fatty lumps of the corpus callosum, namely: cysts and dermoid teratomas, a "fatty" brain scythe: in particular in front of the curvilinear type, or a rare lipomatous transformation of certain types tumors: TNEP, ependymoma, glioma [1].

No specific treatment is usually required: anticonvulsant therapy is the modality of choice in symptomatic lipomas, and surgery is rarely indicated due to the strong vascularization and the adhesion of the lesion to the surrounding parenchyma [1].

## CONCLUSION

Lipoma of the corpus callosum is a very rare abnormality, which can be associated with various degrees of dysgenesis of the corpus callosum. Its extension to the lateral ventricle is even rarer. In most cases they are asymptomatic and are discovered incidentally. Their prognosis and symptoms depend on the associated malformation.

**Conflict of Interest:** All authors state that they have no conflicts of interest.

## REFERENCES

1. Zhari, B., Mattiche, H., Boumdine, H., Amil, T., & Ennouali, H. (2015). Lipoma of the corpus callosum: about a case with literature review. *The Pan African Medical Journal*, 21, 245-245.
2. Jabot, G., Stoquart-Elsankari, S., Saliou, G., Toussaint, P., Deramond, H., & Lehmann, P.

- (2009). Intracranial lipomas: clinical appearances on neuroimaging and clinical significance. *Journal of neurology*, 256(6), 851-855.
3. Alam, A., Ram, M. S., & Sahu, S. (2006). Lipoma of the corpus callosum: diagnosis using magnetic resonance imaging. *Medical Journal, Armed Forces India*, 62(3), 299-300.
  4. Badreeddine, A., Franck, M., Meryem, B., Said, B., Jean-Pierre, G., & Mustapha, M. (2017). Double ostéolipome et dysplasie corticale épileptogène: à propos d'un cas. *AJNS*, 36(1).
  5. Jeffus, K., David Bourne, T., & Beatriz Lopes, S. (2009). Lipoma of the corpus callosum. *International society of neuropathology*.